

Instruments, Materials, and Devices

ZVI METZGER, BETTINA BASRANI and HAROLD GOODIS

CHAPTER OUTLINE

DIAGNOSTIC MATERIALS AND DEVICES

Assessment of Pulp Sensibility
Assessment of Pulp Vascularity
Assessment of Cracks and Fractures
Assessment of Images

ENDODONTIC INSTRUMENTS

Hand Instruments
Instruments for Cleaning and Shaping the Root Canal Space
Devices for Periapical Débridement Through a Root Canal Access
Devices for Measuring Root Canal Length
Instruments for Root Canal Obturation
Devices for Removing Root Canal Obstructions

MATERIALS FOR DISINFECTING THE PULP SPACE

Chemomechanical Preparation
Sodium Hypochlorite
Chlorhexidine
MTAD and Tetraclean
Ethylenediamine Tetra-acetic Acid
Hydrogen Peroxide

Iodine Potassium Iodide
Choosing the Ideal Irrigant
Intracanal Medication
New Irrigation and Disinfection Techniques and Devices

ROOT CANAL FILLING MATERIALS

Solid Materials
Sealers and Cements
Standards and Properties

DELIVERY SYSTEMS FOR ROOT CANAL

OBTURATION MATERIALS

Carrier-Based Systems
Injection Techniques
Rotary Techniques

TEMPORARY RESTORATIONS

LASERS

Neodymium-Doped Yttrium Aluminum Garnet Lasers
Erbium-Doped Yttrium Aluminum Garnet Lasers
Diode Lasers
Erbium/Chromium-Doped Yttrium Scandium Gallium Garnet Lasers

The past decades have seen many changes in the practice of endodontics, such as in materials, techniques, equipment, instrument design, and the types of metals used to manufacture endodontic instruments. However, the goals of non-surgical endodontic therapy has not changed: “Root canal systems must be cleaned and shaped: cleaned of their organic remnants and shaped to receive a three-dimensional hermetic (fluid-tight seal) filling of the entire root canal space.”³³²

DIAGNOSTIC MATERIALS AND DEVICES

Assessment of Pulp Sensibility

One of the greatest diagnostic challenges in clinical practice is the accurate assessment of pulp status. A variety of pulp testing approaches exist, and there may be confusion as to their

The authors acknowledge the excellent scholarship of Drs. Van Himel and John McSpadden in authoring previous editions of this chapter.

validity or appropriateness in different clinical situations. When tests are evaluated, there are some terms that may lead to more definitive and possibly quantifiable endodontic diagnoses. These terms are *sensitivity*, the ability of a test to identify teeth with disease; *specificity*, the ability of a test to identify teeth without disease; and *predictive value*, the ability of a test to foretell what the diagnosis actually is.

Pulp stimulation with cold or heat is the oldest method of evaluating the pulp's health and its ability to respond to external stimulation, but evaluation of pulpal response must not be confused with vitality testing, which requires assessment of pulpal circulation.¹⁴⁰

Cold Tests

Cold thermal testing causes contraction of the dentinal fluid within the dentinal tubules, resulting in a rapid outward flow of fluid within the patent tubules. This rapid movement of dentinal fluid results in hydrodynamic forces acting on the A δ nerve fibers within the pulp-dentin complex, leading to a sharp

sensation lasting for the duration of the thermal test. A variety of cold tests may be employed; the major difference between them is the degree of cold applied to the tooth.¹⁴⁰

A simple means of applying a cold stimulus to a tooth is to wrap a sliver of ice in wet gauze and place it against the buccal surface, comparing the reaction between the test tooth and a control tooth. Pencils of ice can be made by filling a plastic straw with water and freezing it in an upright position in a freezer.³⁵²

Ethyl chloride (-41°C) may be sprayed onto a cotton pledget, resulting in the formation of ice crystals (Fig. 8-1) prior to application to the tooth. Dichlorodifluoromethane (DDM) (-50°C) is a compressed refrigerant spray that can also be sprayed onto a cotton pledget for cold testing (Fig. 8-2). More recently, ozone-friendly non-chlorofluorocarbon sprays have been introduced in certain countries.

Another effective cold stimulus is frozen carbon dioxide (CO_2), also known as *dry ice* or *carbon dioxide snow* (-78.5°C). For testing purposes, a solid stick of CO_2 is

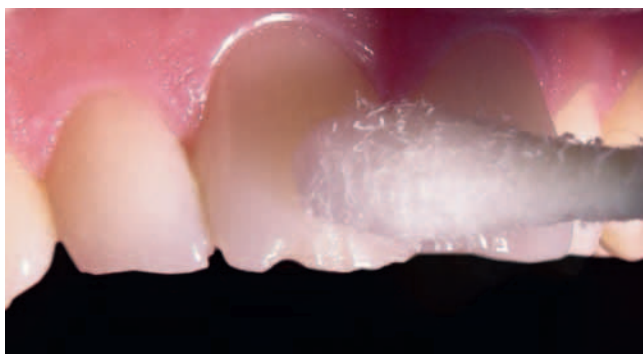

FIG. 8-1 Ethyl chloride sprayed onto a cotton pledget, resulting in the formation of ice crystals. (Courtesy Dr. R. Portigliatti.)



FIG. 8-2 Hygenic Endo-Ice. (Courtesy Coltène/Whaledent, Cuyahoga Falls, OH.)

prepared by delivering CO_2 into a custom-made plastic cylinder, and the stick is applied to the buccal surface of the tooth. This method is particularly effective when trying to assess teeth that have been restored with full-coverage metal restorations.³⁹⁷ Rickoff³¹⁴ reported that CO_2 snow applied to a tooth for 5 minutes did not jeopardize the health of the pulp, nor does it damage the surface of the enamel.³⁰⁰ On the other hand, CO_2 may cause pitting of the surface of porcelain restorations when applied for as little as 5 seconds.²⁰³ When testing with a cold stimulus, the advantage of refrigerant sprays and frozen carbon dioxide is that the cold stimulus does not go into a liquid phase but rather a gas phase. This allows testing to be specific to one tooth at a time, without cold water from melted ice stimulating adjacent teeth.

Ice-cold water is another useful and inexpensive test. The tooth being tested should be isolated with a rubber dam and then bathed with water from a syringe. Cold tests should be applied until the patient definitely responds or the stimulus has been applied for a maximum of 15 seconds.¹²¹ One of the significant benefits of ice-water testing is that it can be used on any tooth regardless of the type of restoration that may be present. Overall, cold tests appear to be more reliable than heat tests,^{93,341} and there is a general consensus that the colder the stimulus, the more effective the assessment of tooth innervation status.

Heat Test

Warm thermal testing is not employed as often as cold testing because most patients are more sensitive to cold stimuli, and warm thermal tests have been traditionally more difficult to perform. Heat testing can be undertaken using a stick of heated gutta-percha or hot water. A gutta-percha stick, preferably base-plate gutta-percha, is heated with a naked flame or an electric heater until it becomes soft and glistens.¹⁴⁹ It is then applied to the Vaseline-coated surface of the test tooth. It is purported that a tooth surface temperature as high as 150°C can be achieved with this technique³¹⁹; gutta-percha softens at 65°C and may be heated in delivery devices up to 200°C . This test may be difficult to use on posterior teeth because of limited access. A further disadvantage is that excessive heating may result in pulp damage.²⁸⁰ Prolonged heat application will result in biphasic stimulation of A δ fibers initially, followed by the pulpal C fibers. Activation of C fibers may result in a lingering pain, therefore heat tests should be applied for no more than 5 seconds. However, inadequate heating of the gutta-percha stick could result in the stimulus being too weak to elicit a response from the pulp.¹⁴⁰

The use of hot water, administered through an irrigating syringe under rubber dam isolation, has also been described as a means of thermal testing. Frictional heat may be generated by using a rubber cup intended for prophylaxis (without paste) against the buccal aspect of a tooth. The normal use of thermal tests on teeth has been shown not to be harmful to healthy pulp tissue.¹⁷⁰ The System B (SybronEndo, Orange, CA) allows dentists to set specific temperatures for warm thermal testing. After the surface of the tooth has been lubricated, a test tip can be attached to the handle of the System B and the temperature set at 150°F . The preheated tip is placed on the surface of the tooth, and the patient's response is evaluated.

One of the problems of testing with heat is that often a nonvital tooth increases in pain secondary to heat stimuli. In

the clinical situation whereby a patient reports pain to heat and relief with cold stimuli, the application of cold to individually selected teeth may eliminate the patient's tooth pain. Therefore, in these situations, the application of cold with relief of pain can be diagnostic for a nonvital pulp.

Electric Pulp Test

The objective of the electric pulp test (EPT) is to stimulate intact A δ nerves in the pulpal-dentin complex by applying an electric current to the tooth surface. A positive result stems from an ionic shift in the dentinal fluid within the tubules, causing local depolarization and subsequent generation of an action potential from intact A δ nerves.²⁹²

The electric pulp tester is a battery-operated instrument connected to a probe that is applied to the tooth under investigation. It functions by producing a pulsating electrical stimulus, the initial intensity of which should be set at a very low value to prevent excessive stimulation and discomfort. The intensity of the electric stimulus is then increased steadily at a preselected rate, and a note is made of the readout on the digital display when the patient acknowledges a warm or tingling sensation. The readout is not a quantitative measurement of pulp health; it simply provides evidence that the A δ fibers are sufficiently healthy to function.¹⁴⁰

Bipolar and monopolar are the two stimulating modes available. The bipolar mode is presumably more accurate because the current is confined to the coronal pulp, but most EPTs are still monopolar.³⁵²

The requirements of an EPT are an adequate stimulus, an appropriate application method, and careful interpretation of results (Fig. 8-3). Tooth isolation during EPT is essential. Drying the enamel, placement of an interproximal plastic strip, and use of a rubber dam can prevent the spread of electrical impulses to adjacent teeth or gingival tissue. Electric current can also be transferred between adjacent teeth through contacting metallic restorations.⁶⁴ A conducting medium should also be used to ensure that maximum current passes from the electrode to the tooth surface.²⁶¹ A laboratory study²⁴⁷ concluded that the interface medium made no appreciable difference to either the voltage or the electric current transmitted. However, a more recent study did demonstrate that different media influence the responses gained from electric testing.²⁶²



FIG. 8-3 Electronic pulp tester. (Courtesy SybronEndo, Orange, CA.)

There are several considerations regarding optimal placement of the tester electrode. The response threshold is reached when an adequate number of nerve terminals are activated to attain what is termed a *summation effect*.²⁸¹ An area of high neural density should have a relatively fast and strong response and requires the least electric current. Therefore, the most desirable area of assessment in incisor teeth is at the incisal edge.³² The tester should be applied on the tooth surface adjacent to a pulp horn, the area of highest nerve density within the pulp. This position equates to the incisal third region of anterior teeth and the mid-third region of posterior teeth. The threshold for response may be influenced by the thickness of the enamel and dentin overlying the pulp. Thus, the response threshold for healthy teeth may be lowest in incisors, slightly greater in premolars, and greatest in molar teeth. A recent study has revealed that the optimum site for tester electrode placement on molars is on the tip of the mesiobuccal cusp.²²⁵

Assessment of Pulp Vascularity

Vitality testing requires the measurement of pulpal blood flow. Several devices are used to evaluate circulatory changes rather than the neural integrity of the pulp, and a number of these have been used experimentally to evaluate pulpal health.

Crown Surface Temperature

An investigator¹⁰³ performed extensive research in the field of crown surface temperature. This pulp vitality technique is based on the hypothesis that vital teeth are warmer and will rewarm quicker after cooling than nonvital teeth. His experiments concluded that time/temperature curves comparing the warming of vital versus nonvital teeth were diagnostically informative.

Attempts to use color change of cholesteric liquid crystals as a diagnostic tool to measure crown temperature change¹⁷³ have also met with some success. And a more recent study using an infrared thermographic camera showed crown temperature patterns of nonvital teeth to be slower to rewarm than those of vital teeth.³²⁰

Transmitted Light Photoplethysmography

Transmitted light photoplethysmography (TLP) is a noninvasive technique used to monitor pulpal blood flow and has been successfully applied in animal and human studies. It has been suggested that TLP incurs less signal contamination from the periodontal blood flow than is the case for laser Doppler flowmetry (LDF).^{227,268}

Laser Doppler Flowmetry

LDF was developed to assess blood flow in microvasculature systems such as the retina, mesentery, renal cortex, and skin.¹⁷¹ It has recently been used in intact teeth in animals^{137,139} and in man.^{253,421} LDF utilizes a light beam (helium neon 632.8 nm) which is scattered by moving red blood cells.⁴²¹ Newer machines have varied the wavelength between 600 and 700 nm, depending on the light absorption properties of the tissue tested. This light beam undergoes a frequency shift according to the Doppler principle. The backscattered light is picked up by photodetectors and produces a signal that is proportional to the red cell flux (number of cells \times average velocity). This can be used as a measure of pulpal blood flow, expressed as a percentage of full-scale deflection at a given gain. The tech-

nique appears objective, noninvasive, and accurate. A growing number of reports indicate it is a method that can easily be adapted to the testing of a tooth and is promising as a pulp vitality tester. It is especially effective in young traumatized teeth with large pulps that do not respond well to other forms of sensitivity testing.^{129,130,253,421}

Several studies have reported successful use of LDF to study human pulpal blood flow. The value of this method has been well documented, but its high cost and difficulty of use in clinical situations have prevented widespread use.

Pulse Oximetry

Pulse oximetry has been used to detect vascular integrity in the tooth.³³⁵ The process measures oxygen saturation in external soft tissue. It has been suggested that it is capable of passing its signal through enamel and dentin. It may also be used on natural tooth structure. The device, as LDF, utilizes a probe that transmits red (640 nm) and infrared light through the tissue (received by a photodetector). Since oxygenated and deoxygenated hemoglobin absorb different amounts of each light, pulsating changes in blood volume cause periodic changes in the amount of light absorbed by the vascular bed before reaching the photodetector. To date, it has not been considered capable of judging pulp vitality in a manner that would allow the proper degree of sensitivity and specificity. It must again be stressed that LDF and pulse oximetry can only be used on natural tooth structure, never on restorations. When used clinically and having a possible response, a rubber dam should isolate the test teeth, and the gingival tissue below the dam should be blocked with an opaque substance (tin foil).

Xenon-133 Radioisotopes

Radioactive materials for measurement of pulpal blood circulation were previously used in the radiolabeled microsphere injection method.^{191,192,396} A method utilizing a radiation probe with xenon-133 (¹³³Xe) radioisotope to differentiate between vital and pulpless teeth on the basis of blood supply has been found effective.³⁹⁶ However, the use of radioactive materials is expensive, restricted on humans, and requires special licensing requirements. To this point, the most promising of these experimental methods are those using the measurement of light passing through or deflected from the blood in the pulp.

Dual Wavelength Spectrophotometry

Oximetry by spectrophotometry uses a dual wavelength light source (760 and 850 nm) to determine the oxygen saturation level of the pulpal blood supply. Preliminary tests on teeth were promising, since the blood oxygenation and volume could be detected.²⁸⁴ The instrument might be useful not only in determining pulp necrosis but also the inflammatory status of the pulp. It shows promise as a pulp tester because it is noninvasive, objective, small, and portable.

Doppler techniques, pulse oximetry, and photoplethysmography are all used in medicine and in dental research. However, they have been less successfully applied to routine endodontic care, because the circulatory system of the pulp is encased in a rigid structure and therefore is difficult to study without the removal of hard tissue. Consequently, the need for an absolute rigid observation point in the Doppler technique and the interference of extrapulpal circulatory systems in pulse

oximetry and photoplethysmography have limited the introduction of these methods to endodontic practice.

Assessment of Cracks and Fractures

Magnification

The introduction of the operative microscope marked outstanding progress in dentistry. Magnification improves the performance of clinical procedures, and the operating microscope has dramatically improved endodontic nonsurgical treatment and periradicular surgery. The use of the operating microscope and microsurgical instrumentation have resulted in greater precision in surgical procedures, less operative trauma, improved healing, better esthetic results, and more predictable treatments. Speed, control, comfort, and adjustment are other distinct advantages.

LOUPES

Magnification loupes attached to eyeglasses are relatively inexpensive, and the learning curve for their use is much shorter than for the microscope. However, there are several shortcomings to loupes compared to the operating microscope. Each loupe has a fixed magnification power (typically less than 4×) that cannot be increased or decreased. Most loupes have no integrated light source, although often they are employed with an accompanying headlamp system. There is no way to digitally document viewed images. The focus is adjusted through the movements of the clinician's head, creating postural positions that may not be ergonomic.

OPERATING MICROSCOPES

All microscope lenses are designed and installed in a telescopic system (Fig. 8-4). This means they are already focused to infinity. They send parallel beams of light to each eye, allowing the viewing of objects three dimensionally with an excellent depth impression.



FIG. 8-4 Zeiss Operating Microscope. (Courtesy Carl Zeiss Meditec, Germany.)

Some characteristics of microscopes are: (1) wide range of magnification, (2) coaxial illumination that allows light to enter even the deepest areas of examination, (3) easy photographic and video capture documentation, (4) the capacity to make focus adjustments by moving the microscope or its parts, maintaining an ergonomic work position.

The major advantage of using light and magnification is the increased diagnostic potential. The microscope is an excellent tool for detecting cracks, additional canals, perforations, and the like.²⁵² It is important to clarify the difference between magnification and differentiation. *Magnification* is defined as viewing an object at a greater size; *differentiation* refers to making an object distinct or specialized. The microscope alone is very useful, but sometimes additional adjuncts must be employed for better differentiation. Methylene blue used in conjunction with magnification can add important information, especially for fracture detection. Additionally, some operating microscopes employ colored light sources which help in the differentiation between bone and root surfaces during apicoectomies.

Periodontal Probing

Periodontal probing is an essential part of the endodontic diagnostic process. The tooth should be evaluated interproximally and at every millimeter on both the buccal and lingual surfaces, with emphasis on the convex part of the root. Each furcation should also be explored with a periodontal or furcation probe. Periodontal probing is especially useful in helping to detect vertical root fractures (VRF). If the probe sinks abruptly into an isolated deep, narrow periodontal defect, the level of suspicion for a VRF increases. This is true especially when there is no evidence of periodontal disease associated with other areas of the tooth or adjacent teeth. If a VRF is suspected but cannot be directly visualized, magnification, illumination, and staining can be very helpful.

Elastic, plastic, periodontal probes (Premier, Plymouth Meeting, PA) (Fig. 8-5) have been advocated for better detection of defects associated with VRFs. A periodontal pocket associated with a VRF—in an otherwise periodontally intact tooth—differs from a common periodontal pocket by having a



FIG. 8-5 Flexible periodontal probe (Premier, Plymouth Meeting, PA) and a conventional rigid metal probe.

deep, narrow pocket with a small occlusal entrance. The flexibility of the plastic probes allows them to be introduced into pockets that may not permit the insertion of rigid metal probes. (Fig. 8-6).

Biting Tests

The Tooth Slooth (SybronEndo) (Fig. 8-7) has proved very useful for the differential diagnosis of various stages of incomplete crown fractures. The design of the device permits a chewing force to be applied selectively to one cusp at a time. When this selective force is applied to a cracked cusp of a vital tooth, the coronal dentin distorts, which is allowed by the crack and results in a painful response. This sensation is not present in other intact cusps of the same tooth. This device can be effective when cotton rolls or wooden sticks are not helpful.

Staining

Dyes can aid greatly in the diagnosis of either caries or fractures. Caries detectors have been used effectively to identify caries not otherwise evident with either visual inspection or traditional hand instruments. Methylene blue dye, India ink or iodine tincture have been very effective dyes used to diagnose the presence of crown or root fractures.²⁰⁶

Transillumination

Transillumination is the transmission of light through tissues of the body. A common example is the transmission of light

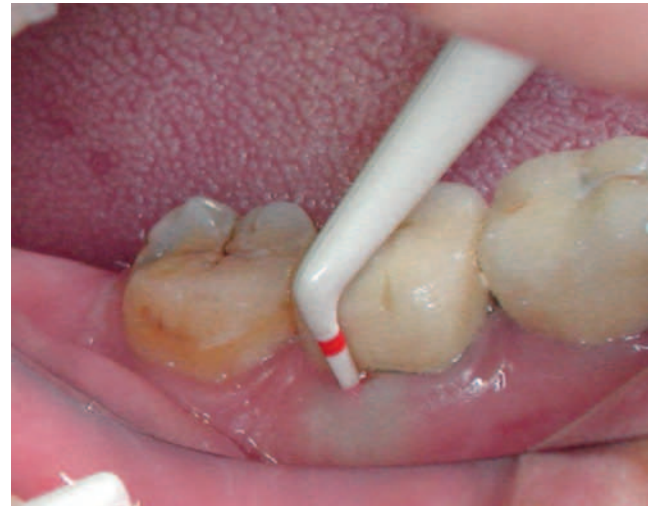

FIG. 8-6 A Premier periodontal probe in a narrow and deep pocket associated with VRF. Note the blanching that indicates the narrow nature of the pocket.



FIG. 8-7 Tooth Slooth. (Courtesy SybronEndo, Orange, CA.)

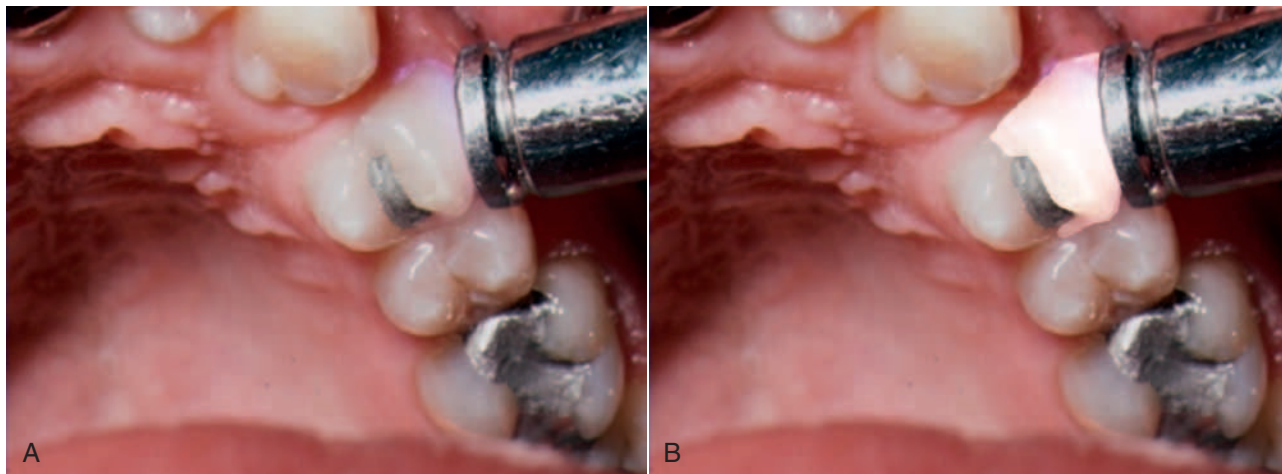


FIG. 8-8 A crack in the crown of a tooth, located by using a transilluminator.

through fingers, producing a red glow due to red blood cells absorbing all other colors of the light. Transillumination is an excellent technique for viewing caries, fractures, narrow root canal orifices, and other clinical entities. It is used by passing an intense light through the side of the tooth and can substantially enhance the clinician's diagnostic and treatment abilities. Healthy tooth structure has an index of light transmission greater than that of caries or calculus. A fracture line or a calcified root canal orifice also have a reduced ability to transmit light. Therefore, if an intense light is applied in direct proximity to a tooth, and other extraneous light is reduced, these clinical entities will appear as distinct dark areas in the otherwise bright structure (Fig. 8-8). The transilluminator tip is placed on either the facial or lingual surface of the tooth or the root, and the area can be viewed from the occlusal surface or the surface opposite the transilluminator. Direct vision or a dental mirror may be used for viewing, depending upon the area under examination. The exact placement of the transilluminator differs for caries, endodontics, fractures, and so forth.

The acceptance of transillumination as a diagnostic technique has been greatly enhanced by the availability of modern devices made expressly for this purpose.¹¹⁸ These transilluminators use white light-emitting diode (LED) lamps to generate the necessary intense white light. The light is then transmitted to the working area, without heat, using a narrow fiberoptic rod or fiberoptic cables. An important feature is that a fiberoptic rod can be easily removed and autoclaved to avoid cross-contamination between patients. The small size and portability of these new devices enhances the convenient use of transillumination.

Assessment of Images

Radiographs

Radiography is an essential part of endodontic diagnosis. Modern technology is rapidly shifting toward digital filmless imaging and other new image-enhancing techniques (see Chapter 29). Therefore the clinician must be well versed in this diagnostic field.

The radiographic examination should always be evaluated together with other diagnostic tests and clinical examination.

Initial sensitivity tests can suggest which type of radiograph will be most advantageous. If a vital tooth is evaluated, a bitewing radiograph would be advantageous to detect caries or other potential causes of pulpal inflammation. If periapical disease is suspected by the previous tests, a periapical radiograph is indicated. All radiographs should be taken using holders that allow parallelism and standardization. If comparative radiographs will be necessary on a subsequent patient visit, it is useful to fabricate an individual impression material bite-block so that the angulation of follow-up radiographs will be as similar as possible. Extra oral radiographs, like occlusal or PAs, may also be useful in certain cases.

Radiography cannot directly detect pulpal inflammation, but caries or defective restorations seen on the radiograph may suggest pulpal inflammation. Condensing apical periodontitis is a near-pathognomonic sign of longstanding pulpitis. Also, the presence of an apical radiolucency of endodontic origin may be a good indication that necrosis or a necrotic zone is present in the pulp space.

The radiograph is one of the best means at our disposal for determining the existence of a chronic periapical condition. It is characterized by a rather well-defined radiolucent area, or dark shadow, which may or may not be exactly at the apex of the tooth.

Technology has advanced in the area of radiology to include F-speed or Insight conventional film, xeroradiography, digital radiography, subtraction radiography, phosphor images, ultrasound, and recently also cone-beam computed tomography (CBCT). But improvement in our ability to interpret periradicular/periapical pathosis is still debatable with some of these methodologies. Comparing xeroradiography and E-speed conventional film, investigators²² reported no difference in the detection of periapical bone pathosis.

Another study³⁹⁹ found that digitally subtracted images were more sensitive for identifying cortical and cancellous bone changes than conventional films. In an in vitro model, other investigators⁹⁰ found that subtraction radiography was capable of discriminating between health and disease. Still others²⁶⁵ found that the progress of chronic apical periodontitis may be followed predictably by their subtraction methodology. Digital subtraction radiography may also be useful in the

evaluation of healing following endodontic therapy.⁴³³ Another investigation²⁰⁷ concluded that conventional film radiography performed slightly better for the detection of periapical bone lesions than direct digital radiography, and that image processing did not improve the observer performance.

Researchers²⁹⁶ reported that cortical bone lesions were identified with greater accuracy than trabecular bone lesions, regardless of whether digital radiography or conventional films were used.

Another study¹⁰⁹ demonstrated that there was no significant difference in the accuracy of detecting artificially prepared periapical lesions between Schick CDR and Trophy RVGui DDR systems. Their results using digital radiography were in agreement with Seltzer and Bender's³⁴¹ finding using conventional radiography: artificially produced lesions were not radiographically observed unless the cancellous lesion extended to the junction of the cancellous and cortical bone.

Ultrasound

Coinvestigators⁶⁶ have introduced the potential of ultrasound real-time imaging in endodontics and found it able to distinguish between granulomas and cysts. This promising potential awaits further long-term investigations.

Cone-Beam Computed Tomography and Other Scans

CBCT (Fig. 8-9), ultrasound, and other emerging technologies seem to be very promising tools for determining a more accu-

rate diagnosis of periradicular pathoses.^{67,153,246,275} The reader is referred to Chapter 29 for further information about CBCT.

ENDODONTIC INSTRUMENTS

Although most instruments used in general dentistry also can be used for endodontic therapy, some hand instruments are designed specifically for endodontic procedures. In addition, many different types of instruments have been designed for procedures performed inside the pulp space. These include manually operated instruments for root canal preparation, rotary and other engine-driven and energized instruments for root canal preparation, and instruments for root canal obturation.

Standardized specifications have been established to improve instrument quality. For example, the International Standards Organization (ISO) has worked with the Fédération Dentaire Internationale (FDI) through the Technical Committee 106 Joint Working Group (TC-106 JWG-1) to define specifications. These standards are designated with an ISO number. The American Dental Association (ADA) also has been involved in this effort, as has the American National Standards Institute (ANSI); these standards are designated with an ANSI number. However, new instrument designs have resulted in a need for reconsideration of the standards.

Two ISO standards pertain to endodontic instruments. ISO No. 3630-1 deals with K-type files (as does ANSI No. 28), Hedström files (ANSI No. 58), and barbed broaches and rasps (ANSI No. 63). ISO No. 3630-3 deals with condensers, pluggers, and spreaders (ANSI No. 71).

Hand Instruments

Traditional dental hand instruments have been modified for endodontic uses. A typical set of endodontic instruments might include a front-surface mouth mirror, a D-5 explorer, a D-16 endodontic explorer, cotton pliers, a spoon excavator, a series of pluggers, a plastic instrument, a hemostat, a periodontal probe, and a ruler. The endodontic explorer has two straight, very sharp ends that are angled in two different directions from the long axis of the instrument.

The mouth mirror should be a front-surface mirror, especially when magnifying loupes or an operating microscope are used. Several types of endodontic spoons are available. These spoons have a much longer offset from the long axis of the instrument (for better reach inside constricted pulp chambers) than regular dental spoons. The spoons are used to remove carious material and to excise pulp tissue; therefore, they should be kept well sharpened (Fig. 8-10). The cotton pliers should preferably be of the locking type that can securely hold gutta-percha cones when transferred from the dental assistant to the dentist's hand. The periodontal probe should be a flexible one (see Fig. 8-5). The exact type and number of instruments usually depend on the techniques used and clinician's preference.

Microwstruments

With the enhanced use of microscopes in endodontics, especially during apical surgery, many specially designed miniaturized instruments have been introduced. These include miniature mirrors, probes and pluggers (for details see Chapter 21).

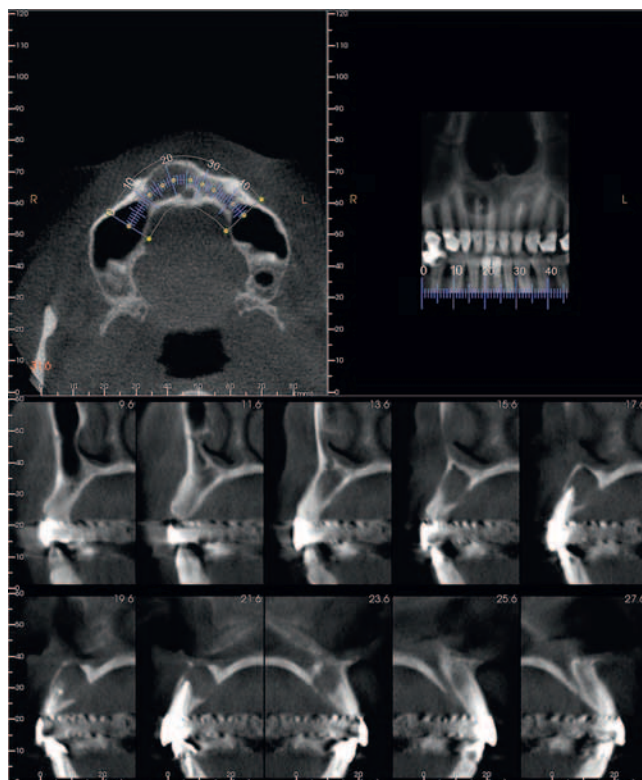


FIG. 8-9 CBCT example: These series of images show an ovoid radiolucent area in the anterior right maxilla. Both teeth 1.1 and 1.2 were endodontically treated; however, given the epicenter of the entity relative to the teeth, the radiolucent area was interpreted to be a keratocystic odontogenic tumour. (Courtesy Dr. E. Lam.)




FIG. 8-10 Endodontic explorer (A) and endodontic spoon (B). (From Boyd LR: *Dental instruments: a pocket guide*, ed 3, Saunders Elsevier, St Louis, 2009.)

Instruments for Cleaning and Shaping the Root Canal Space

The purposes of this section is to provide the principles necessary for the clinician to better understand the ideal design for current and future instruments. Most instructional materials mistakenly attempt to teach step-by-step techniques rather than explain the physics of the instruments. However, an increasing number of new products and their advocates have created confusion in the selection process. For this reason, the clinician must understand the basic mechanical, physical, and scientific principles of instrumentation (*Box 8-1*).

The two primary goals of root canal instrumentation are (1) to provide a biologic environment (infection control) conducive to healing and (2) to develop a canal shape receptive to obturation. Historically, most instruments used to shape the canal were designed to be used by hand. Recently, rotary instrumentation has gained considerable popularity and may be used in conjunction with hand instruments (*Box 8-2*). The information in the following sections should facilitate the most efficient use of rotary instruments, minimizing the chance of instrument or procedural mishaps and allowing the clinician to achieve ideal treatment results.

Group 1: Manually Operated Instruments

Manually operated instruments are all instruments that are generically called *files*. Defining endodontic instruments by function, files are instruments that enlarge canals with reciprocal insertion and withdrawal motions. Reamers cut and enlarge canals with rotational motions. Before using either instrument, the clinician must make sure the canal is patent.

Files were first mass produced by the Kerr Manufacturing Co. of Romulus, Michigan, in the early 1900s, hence the name K-type file (or K-file) and K-type reamer (K-reamer). K-files and K-reamers originally were manufactured by the same process. Three or four equilateral, flat surfaces were ground at increasing depths on the sides of a piece of wire, producing a tapered pyramidal shape. The wire then was stabilized on one end, and the distal end was rotated to form the spiral instrument (*Fig. 8-11*). The number of sides and the number of spirals determine whether the instrument is best suited for filing or reaming. Generally, a three-sided configuration with

BOX 8-1

Terminology for the Physical Properties of Instruments

Successful use of an instrument depends on the ways the material, design, and technique relate to the forces exerted on the instrument. The following terms quantify the actions and reactions to these forces.

Stress: The deforming force measured across a given area.

Stress concentration point: An abrupt change in the geometric shape of a file, such as a notch, which results in a higher stress level at that point than along the surface of the file where the shape is more continuous.

Strain: The amount of deformation a file undergoes.

Elastic limit: A set value representing the maximal strain that, when applied to a file, allows the file to return to its original dimensions. After the strain is removed, the residual internal forces return to zero.

Elastic deformation: The reversible deformation that does not exceed the elastic limit.

Shape memory: A condition that exists when the elastic limit is substantially higher than is typical for conventional metals. It allows an instrument to regain its original form after being deformed.

Plastic deformation: Permanent bond displacement, which occurs when the elastic limit is exceeded. The file does not return to its original dimensions after strain is removed.

Plastic limit: The point at which a plastic-deformed file breaks.

fewer spirals is used for reaming; a three- or four-sided configuration with more spirals is used for filing.

Historically, root canal instruments were manufactured from carbon steel. Subsequently, the use of stainless steel greatly improved the quality of instruments. More recently, the introduction of the nickel-titanium (NiTi) alloy in the manufacture of endodontic instruments has resulted in significant improvements in canal shaping because of its increased flexibility compared to stainless steel (this metal is described later in the chapter).




FIG. 8-11 The two ends of a blank, tapered pyramidal wire are stabilized (*top*) and then one end is rotated to create a spiral shape on the file's working surface (*middle*). Multiple rotations produce the final spiral shape (*bottom*). (Courtesy John T. McSpadden, Lookout Mountain, GA.)

BOX 8-2

Classification of Instruments Used for Cleaning and Shaping the Root Canal Space

Endodontic instruments for root canal preparation can be divided into six groups:

- ◆ **Group I:** Manually-operated instruments, such as barbed broaches and K-type and H-type instruments.
- ◆ **Group II:** Low-speed instruments with a latch-type attachment. Typical instruments in this group are Gates-Glidden (GG) burs and Peeso reamers. They are typically used in the coronal part of the canal and never used in a canal curvature.
- ◆ **Group III:** Engine-driven nickel-titanium rotary instruments. They consist of a rotating blade that can safely be operated in, and adapt itself to, curved root canals. Most engine-driven instruments available today belong to this group.
- ◆ **Group IV:** Engine-driven instruments that adapt themselves three-dimensionally to the shape of the root canal. Like other nickel-titanium instruments, they adapt to the shape of the root canal longitudinally but additionally they adapt also to the cross-section of the root canal. There is currently only one instrument in this group: the self-adjusting file (SAF; ReDent-Nova, Raanana, Israel).
- ◆ **Group V:** Engine-driven reciprocating instruments.
- ◆ **Group VI:** Ultrasonic instruments.

BARBED BROACHES AND RASPS

Dating from the early to mid-19th century, broaches and rasps were the earliest endodontic instruments used to extirpate the pulp and enlarge the canal (Fig. 8-12). Still used today, these instruments are manufactured by hacking a round, tapered wire with a blade to form sharp, projecting barbs that cut or snag tissue. Specifications have been set for both the barbed broach and the rasp (ANSI/ADA standard No. 63, ISO/FDI standard No. 3630/1).

A barbed broach does not cut or machine dentin; this instrument is mostly used to engage and remove soft tissue

from the canal. It is also an excellent tool for removing cotton or paper points that have accidentally become lodged in the root canal.

K-TYPE INSTRUMENTS

The K-file and K-reamer are the oldest useful instruments for cutting and machining dentin (Fig. 8-13). They are made from a stainless steel wire that is ground to a tapered square or triangular cross-section and then twisted to create either a file or a reamer. A file has more flutes (see Components of a File) per length unit than a reamer.

K-type instruments are useful for penetrating and enlarging root canals. The instrument works primarily by compression-and-release destruction of the dentin surrounding the canal. Generally, a reaming motion (i.e., constant file rotation) causes less transportation than a filing motion (reciprocating or “watch-winding” file rotation).⁴⁰⁶ (*Transportation* is the excessive loss of dentin from the outer wall of a curved canal in the apical segment. This procedural error can lead to perforation of the root canal system or an inability to negotiate the canal space apical to the canal transportation.) A stainless steel K-file can be precurved to a desired form to facilitate insertion and minimize transportation. Permanent deformation occurs when the flutes become wound more tightly or opened more widely (Fig. 8-14). When such deformation occurs, the instrument should no longer be used. Instruments fracture during clockwise motion after plastic deformation.^{158,345} This occurs when the instrument becomes bound while the force of rotation continues. Interestingly, although the force required for failure is the same in both directions of rotation,^{205,213} failure occurs in the counterclockwise direction at half the number of rotations required for failure in the clockwise direction. Therefore K-type instruments should be operated more carefully when pressure is applied in a counterclockwise direction.

H-TYPE INSTRUMENTS

An H-type instrument has spiral edges arranged to allow cutting only during a pulling stroke (Fig. 8-15). An example is a Hedström file. An H-type instrument is better for cutting than a K-type instrument, because it has a more positive rake angle (see Components of a File) and a blade with a cutting rather than a scraping angle. Bending a Hedström file results in points of greater stress concentration than occurs with K-type instruments. These concentration points can lead to the propagation of cracks and fatigue failure.¹⁵⁸ Clinically, fatigue happens without any external physical signs of stress, such as the flute changes seen in K-type instruments (see Fig. 8-14).

Currently all H-type instruments are ground from a tapered blank. Hedström files are formed by grinding a single continuous flute. Computer-assisted machining technology has allowed the development of H-type instruments with very complex forms. This process, called *multiaxis grinding*, allows adjustment of the rake angle, helix angle, multiple flutes, and tapers. H-files cut the canal wall when pulled or rotated clockwise; the file is relatively ineffective when pushed or rotated counterclockwise. Because the H-file generally has sharper edges than the K-file, it has a tendency to screw into the canal during rotation, particularly if the instrument's blades are nearly parallel. Awareness of screwing-in forces is important for avoiding instrument failure.

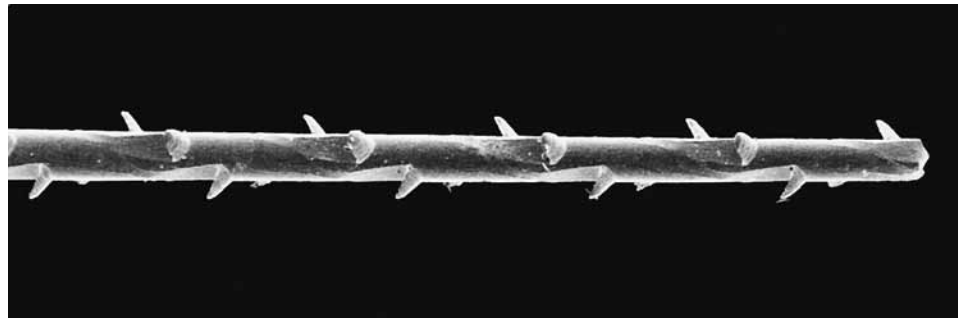


FIG. 8-12 Barbed broach (Union Broach, York, PA).




FIG. 8-13 K-file #40 (Dentsply-Maillefer, Ballaigues, Switzerland).

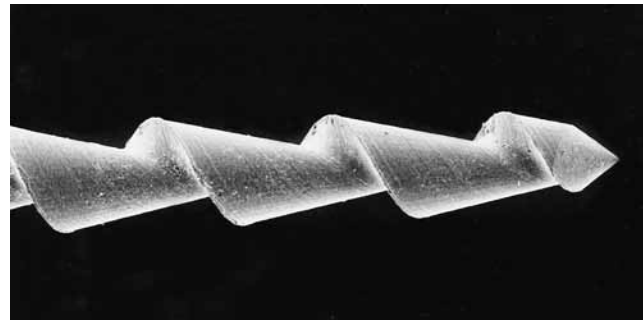


FIG. 8-15 Hedström file #50 (Dentsply-Maillefer, Ballaigues, Switzerland).

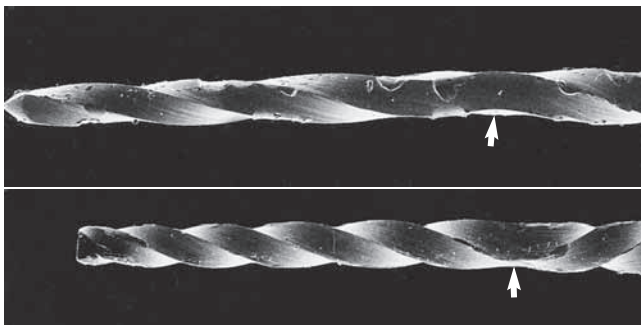


FIG. 8-14 K-files stressed to deformation by clockwise and counter-clockwise twisting (arrow indicates deformed areas). These instruments are close to fracture and should be discarded.

INSTRUMENT DESIGN MODIFICATIONS

K-files and H-files can be modified into numerous designs. Often the instruments can be improved for more effective instrumentation by changing the geometric dimensions, using computerized multi-axis grinding machines. For example, changing the cross-sectional geometry of a K-type instrument from square to rhomboid enhances the instrument's flexibility and rake angle. However, the possible geometries can complicate adherence to ISO and ANSI standards.

TIP DESIGN

Studies have shown that tip design can affect file control, efficiency, and outcome in the shaping of root canal systems.^{266,267} The tip of the original K-file resembled a pyramid (see Fig. 8-13). Instrument tips have been described as *cutting*, *noncut-*

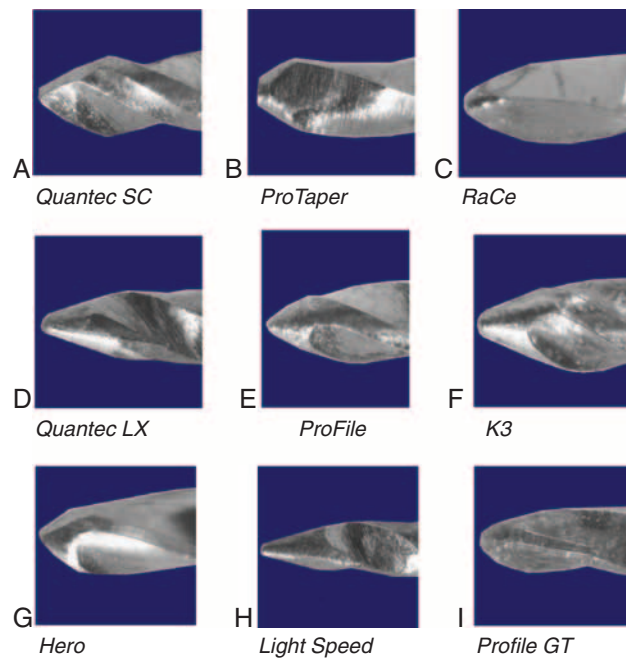


FIG. 8-16 Instrument tips arranged in order from cutting to non-cutting. (Courtesy John T. McSpadden, Lookout Mountain, GA.)

ting, and *partially cutting*, although no clear distinction exists among the three types (Fig. 8-16).

The instrument tip has two functions: to guide the file through the canal and to enlarge the canal. A clinician who is unfamiliar with the tip design of a particular instrument is apt

to do either of the following: (1) transport the canal (if the tip is capable of enlarging the canal and remains too long in one position) or (2) encounter excessive torsion and break the file (if a noncutting tip is forced into a canal with a smaller diameter than the tip). Transportation of the original axis of the canal can occur by remaining too long in a curved canal with a tip that has efficient cutting ability.

The angle and radius of its leading edge and the proximity of the flute to its actual tip end determines the cutting ability of a file tip. Cutting ability and file rigidity determine the propensity to transport the canal. The clinician must keep in mind that as long as the file is engaged 360 degrees, canal transportation is unlikely to occur. Only with overuse does the file begin to cut on one side, resulting in transportation. Most instrumentation errors occur when the file tip is loose in the canal, which gives it a propensity to transport the canal.

A good beginner's rule is this: If the canal is smaller than the file, the prudent use of a cutting tip is more efficient. If the canal is larger than the tip, using a less-effective cutting tip can help prevent transportation (see Fig. 8-16). Much has been written about the importance of various sophisticated tip modifications to prevent such ledging, but little scientific evidence exists that any one design is better than another.^{190,308,309,316,321}

METAL ALLOYS

The development of nitinol, an equiatomic alloy composed of nickel and titanium,⁴¹² has proved a significant advancement in the manufacture of endodontic instruments. NiTi is called an *exotic metal* because it does not conform to the typical rules of metallurgy. Because it is a superelastic metal, the application of stress does not result in the usual proportional strain seen in other metals such as stainless steel. When stress is initially applied to NiTi, the result is proportional strain, but the strain remains essentially the same as the application of additional stress reaches a specific level, forming what is called a *loading plateau*. Eventually, of course, application of more stress results in more strain, which increases until the file breaks. This unusual property is the result of a molecular crystalline phase transformation. External stresses transform the austenitic crystalline form of NiTi into a martensitic crystalline structure that can accommodate greater stress without increasing the strain. As a result of its unique crystalline structure, a NiTi file has *superelasticity*, or the ability to return to its original shape after being deformed. Simply stated, NiTi alloys currently are the only readily available affordable materials with the flexibility and toughness for routine use as effective rotary endodontic files in curved canals.

Attempts to improve the NiTi alloy continue, and recent reports indicate that new NiTi alloys may be five times more flexible than currently used alloys.¹⁸⁶ Microscopic surface defects are considered a contributing factor for crack propagation and instrument fracture. Therefore, attempts to improve surface characteristics by electropolishing, surface coatings, and surface implantation have been used for this purpose.^{216,310}

Group II: Low-Speed Rotary Instruments

Many types of rotary instruments are used during endodontic procedures. In addition to regular burs adapted for endodontics, various types of root canal reamers are used to shape the canal space, to place or remove root canal filling materials, or to prepare a post space.



FIG. 8-17 Gates-Glidden (GG) burs made of stainless steel. (From Johnson WT: *Color atlas of endodontics*, St Louis, 2002, Saunders.)

BURS

In addition to conventional burs, burs with extended shanks for low-speed contra-angle handpieces are useful for providing good visibility during deep preparation of the pulp chamber. This is particularly important when using an operating microscope when performing such procedures after access to the pulp chamber has been achieved. Straight-line access to the initial point of curvature traditionally has been accomplished using rotary instruments such as Gates-Glidden burs and Peeso instruments. These reamers are available in a 32-mm length and a 28-mm length for posterior teeth (Figs. 8-17, 8-18). Use of these instruments should be limited to the straight portion of the canal preparation. The risk of perforation with these instruments becomes a real possibility with attempts to instrument beyond the point of curvature or if the instruments are used to cut laterally. The risk of lateral cutting resulting in perforation is lower with Gates-Glidden burs than with the other instruments mentioned. This risk is especially pronounced on the furcation sides of mesial roots of molars. Gates-Glidden instruments are also available in nickel-titanium. The Peeso reamer is used mostly for post space preparation (Fig. 8-19).

Group III: Rotary Instruments for Canal Preparation

COMPONENTS OF A FILE

To make the best use of files, the clinician should be familiar with the parts of each file and understand how variations in design affect instrumentation (Fig. 8-20). The *taper* usually is expressed as the amount the file diameter increases each millimeter along its working surface from the tip toward the file handle. For example, a size #25 file with a #.02 taper would have a 0.27 mm diameter 1 mm from the tip, a 0.29 mm diameter 2 mm from the tip, and a 0.31 mm diameter 3 mm from the tip. Some manufacturers express the taper in terms of percentage (e.g., a #.02 taper is a 2% taper). Historically, as an

ISO standard, a file was fluted and tapered at 2% for 16 mm, but now files incorporate a wide variation of lengths and tapers of working surfaces. The ability to determine cross-sectional diameter at a given point on a file can help the clinician determine the file size in the point of curvature and the relative stress being placed on the instrument.

The *flute* of the file is the groove in the working surface used to collect soft tissue and dentin chips removed from the wall of the canal. The effectiveness of the flute depends on its depth, width, configuration, and surface finish. The surface with the greatest diameter that follows the groove (where the flute and land intersect) as it rotates forms the *leading (cutting) edge*, or the *blade* of the file. The cutting edge forms and deflects chips from the wall of the canal and severs or snags soft tissue. Its effectiveness depends on its angle of incidence and sharpness. If a surface projects axially from the central axis as far as the cutting edge between flutes, this surface is called the *land* (or sometimes the *marginal width*) (Figs. 8-21 and 8-22). The land touches the canal walls at the periphery of the file and reduces

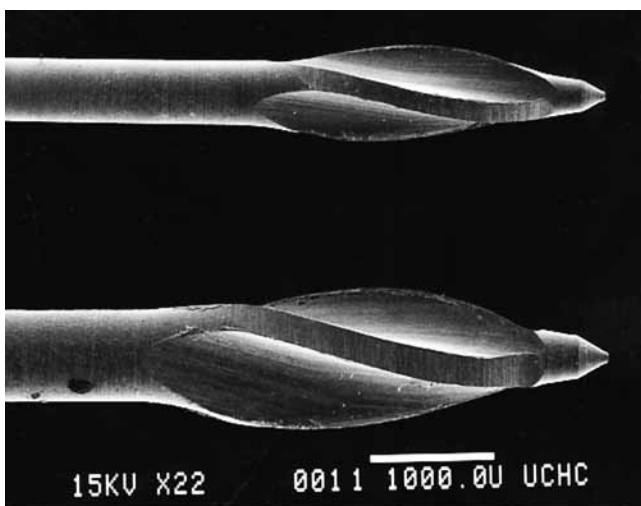


FIG. 8-18 Working part of a Gates-Glidden bur made of stainless steel. Note the rounded safety tip and the lack of sharp cutting edges. The instrument has a marginal land for centering the drill in the canal and to allow safer machining of the canal walls.

the tendency of the file to screw into the canal, reduces transportation of the canal, reduces the propagation of microcracks on its circumference, supports the cutting edge, and limits the depth of cut. Its position relative to the opposing cutting edge and its width determine its effectiveness. To reduce frictional resistance, some of the surface area of the land that rotates against the canal wall may be reduced to form the *relief* (Fig. 8-23). The angle the cutting edge forms with the long axis of the file, called the *helix angle*, augers debris collected in the flute from the canal. This angle is important for determining which file technique to use (see Fig. 8-23; Fig. 8-24).

If a file is sectioned perpendicular to its long axis, the *rake angle* is the angle formed by the leading edge and the radius of the file. If the angle formed by the leading edge and the surface to be cut (its tangent) is obtuse, the rake angle is said to be *positive* or *cutting*. If the angle formed by the leading edge and the surface to be cut is acute, the rake angle is said to be *negative* or *scraping* (Fig. 8-25). However, the rake angle may not be the same as the *cutting angle*. The cutting angle, or the *effective rake angle*, is a better indication of a file's cutting ability and is determined by measuring the angle formed by the cutting (leading) edge and the radius when the file is sectioned perpendicular to the cutting edge. If the flutes of the file are symmetric, the rake angle and the cutting angle are essentially the same.

The *pitch* of the file is the distance between a point on the leading edge and the corresponding point on the adjacent leading edge, or it may be the distance between corresponding

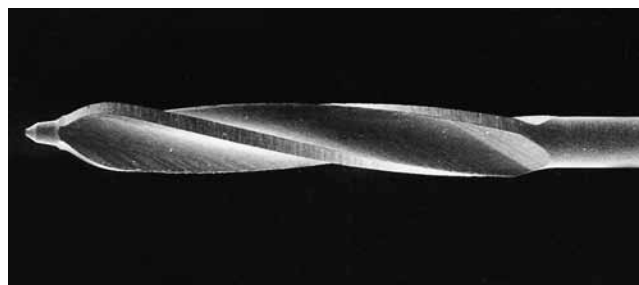


FIG. 8-19 Peeso Reamer (Union Broach, York, PA). Note the safety tip and marginal lands on the machining surfaces.

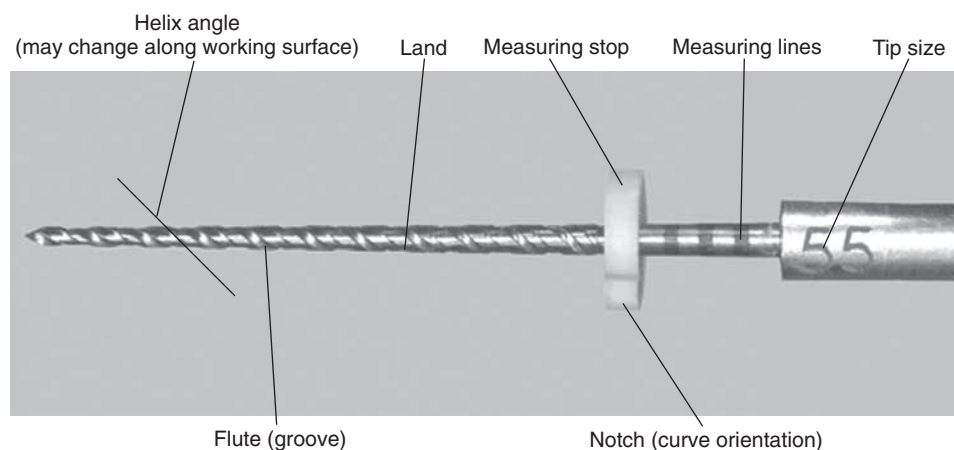


FIG. 8-20 Components of an endodontic rotary instrument. (Courtesy John T. McSpadden, Lookout Mountain, GA.)




FIG. 8-21 ProFile rotary NiTi instruments, #3, #5, and #6 (Dentsply Tulsa Dental, Tulsa, OK). The instruments have marginal lands that guide the instrument in the center of the canals and around curvatures.




FIG. 8-22 Rotary ProFile NiTi file, #5 (Dentsply Tulsa Dental, Tulsa, OK). Note the instrument's wide marginal land (arrows).




FIG. 8-23 Components of the Quantec NiTi rotary instrument (SybronEndo, Orange, CA). (Courtesy John T. McSpadden, Lookout Mountain, GA.)

points within which the pattern is not repeated. The smaller the pitch or the shorter the distance between corresponding points, the more spirals the file has and the greater the helix angle. Most files have a variable pitch, one that changes along the working surface. Because the diameter increases from the

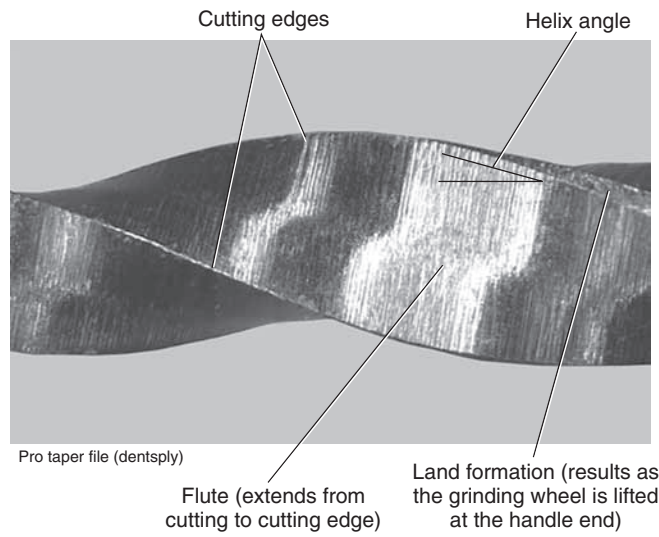


FIG. 8-24 Components of the ProTaper NiTi rotary instrument (Dentsply Tulsa Dental, Tulsa, OK). (Courtesy John T. McSpadden, Lookout Mountain, GA.)

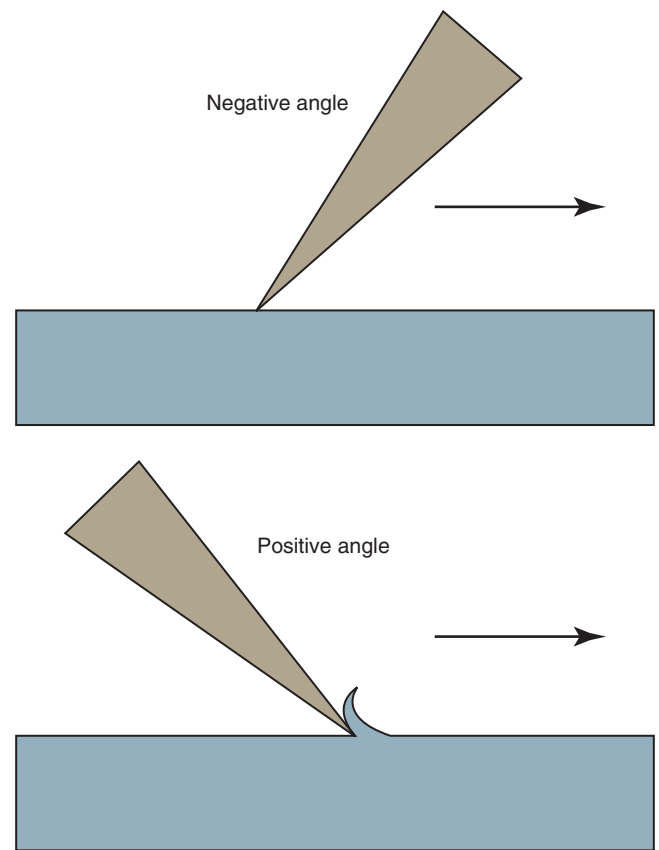


FIG. 8-25 Positive and negative rack angles. Negative angle results in scraping action; positive angle results in cutting action.

file tip toward the handle, the flute becomes proportionately deeper, resulting in a *core taper* that is different from the *external taper*.

The cutting angles, helix angles, and external and core tapers may vary along the working surface of the file, and the

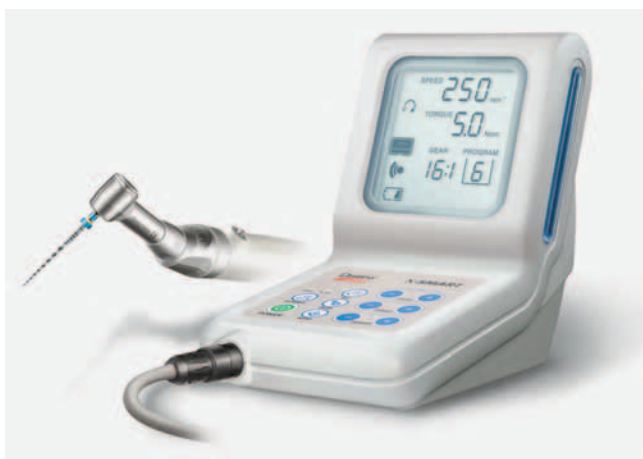

FIG. 8-26 Torque- and speed-controlled electric micromotor and handpiece (X-Smart Endodontic Motor). (Courtesy Dentsply-Maillefer, Ballaigues, Switzerland.)

ratios of these quantities can vary between instruments of the same series. A change in any of these features can influence the file's effectiveness or its propensity for breakage as it progresses into the canal space; this can explain why some files act uncharacteristically compared with other files in the same series. In one study, investigators using electric and air-driven handpieces with rotary NiTi instruments found no significant difference in file distortion or breakage between the two handpieces at 150 revolutions per minute (rpm).⁴⁰ Other researchers have shown that the ability to select precise rpm⁷¹ and torque¹²² settings affects the efficiency and durability of instruments (Fig. 8-26). Determining and maintaining a file's proper rotational speed is more difficult with an air handpiece than with an electric handpiece. For this reason, the clinician would be wise to use an electric handpiece when instrumenting with rotary files. The popularity of electric handpieces among clinicians appears to support the conclusion that regardless of the design used for rotary NiTi instruments, an electric handpiece—rather than an air-driven handpiece—should be used because it allows precise speed and torque control (see Fig. 8-26).

INSTRUMENT DESIGNS

Design changes are made in endodontic instruments to help prevent procedural errors, increase efficiency, and improve the quality of canal shaping. Examples of instruments commonly used today are the ProFile and ProFile GT, the ProTaper, the Lightspeed LSX, the Quantec, the Twisted File (TF),^{123,212} the RaCe, the EndoSequence, and the EZ-Fill SafeSider. For more information about these instruments and others, see Chapter 9. In many patients, the apical canal is larger than the largest file used at working length, so many design changes have been directed toward enabling the clinician to increase the size of the largest file used at working length. The following design components can be used to prevent excess stress on instruments.

1. The difference between the file's minimum and maximum diameters can be reduced so that the torque required for rotating the larger diameter does not exceed the plastic limit of the smaller diameter.

2. The space between the tip and the maximum diameter can be reduced so that the required torque does not exceed the ultimate strength of any part of the file.
3. A zero taper or nearly parallel and fluted working portion of the file can be provided for curved canals so that the apical portion of the canal can be enlarged without undue file stress and compression of debris.
4. The continuity of the blade engagement can be interrupted.
5. The number of flute spirals can be eliminated or reduced to the smallest number necessary to prevent excessive torque, which results from the accumulation of debris.
6. A means can be provided to complete the file function before the flutes fill with debris.
7. Any land width can be minimized to reduce abrasion on the canal surface.
8. The file can be given an asymmetric cross-section to help maintain the central axis of the canal.
9. The number of flutes with similar helix angles can be reduced. When helix angles are dissimilar, screwing-in forces are reduced; when flutes have no helix angles, screwing-in forces are eliminated.
10. Positive cutting angles can be incorporated to enhance the efficiency of canal enlargement.
11. Blades can be made appendages or projections from the file shaft rather than ground into the shaft.
12. Channels can be cut along the long axis of the file to facilitate its removal if it breaks.

Group IV: Engine-Driven Three-Dimensionally Adjusting Files

SELF-ADJUSTING FILE

The self-adjusting file (SAF; ReDent-Nova, Raanana, Israel) represents a new approach in file design and mode of operation.²⁶⁰ The file is a hollow device, designed as a cylinder of thin-walled, delicate NiTi lattice with a lightly abrasive surface (Figs. 8-27, 8-28). An initial glidepath is established with a #20 K-file to allow the insertion of the SAF file. The file is proposed to be compressed from its 1.5 mm diameter into dimensions equivalent to those of a #25 K-file (Fig. 8-29). It is operated with a modified KaVo handpiece (GENTLEpower 20LP with a 3LDSY head, KaVo Dental GmbH, Biberach/Riss, Germany) that generates in-and-out vibrations with 5000 vibrations per minute and 0.4 mm amplitude (Fig. 8-30). The overall concept is that the compressed file will adapt itself to the root canal walls, applying a uniform cutting action (see Fig. 8-28) gradually removing a uniform dentin layer from the canal walls.

As noted, the file is hollow, which allows for continuous irrigation through the file while operated in the root canal. The irrigant is delivered through a free-rotating hub to which a silicone tube is attached (see Fig. 8-30). Either a special irrigation unit (Fig. 8-31) (VATEA, ReDent-Nova, Raanana, Israel) or any appropriate dispenser-type unit may be used to deliver a constant flow of irrigant at 5 ml/min. This maintains a continuous flow of fresh, fully active irrigant that carries with its outflow tissue debris and the dentin powder generated by the file.²⁵⁶

One file is used throughout the procedure. It is initially compressed into the root canal (see Fig. 8-29) and gradually enlarges while cleaning and shaping the canal. The unique feature of this file is that it adapts to the shape of the canal not

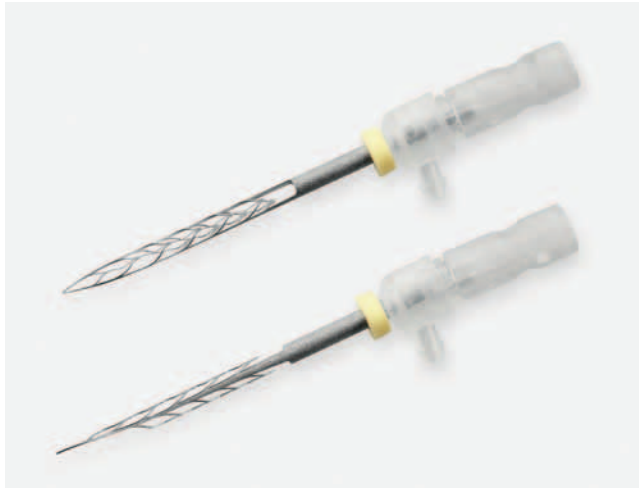

FIG. 8-27 The SAF instrument. The instrument is made as a hollow thin NiTi lattice cylinder that is compressed when inserted into the root canal and adapts to the canal's cross-section. It is attached to a vibrating handpiece. Continuous irrigation is applied through a special hub on the side of its shank. (Courtesy ReDent-Nova, Raanana, Israel.)




FIG. 8-28 The abrasive surface and details of the lattice of the SAF instrument. The extreme elasticity is the total of the elasticity of each of the delicate NiTi segments. (Courtesy ReDent-Nova, Raanana, Israel.)

only longitudinally, as every NiTi file does, but also to the cross-section of the canal. Consequently, the basic shape of the root canal is preserved: a root canal with a round cross-section is enlarged to one with a similar but larger cross-section, whereas a flat root canal will be enlarged to a flat root canal of bigger dimensions (see Fig. 8-31). This unique feature of the SAF file makes it different from any other currently available file system.

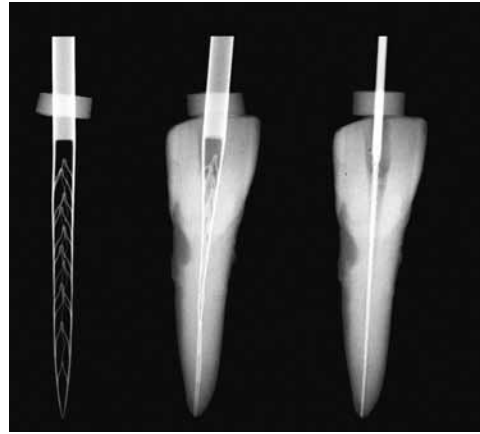


FIG. 8-29 The SAF instrument adapted into a root canal that was initially prepared with #20 K-file. *Right:* A #20 K-file in the canal. *Left:* The SAF file in its relaxed form. *Center:* The SAF file inserted into the same narrow canal. It will apply delicate pressure on the canal wall, attempting to resume its original shape. (Courtesy ReDent-Nova, Raanana, Israel.)

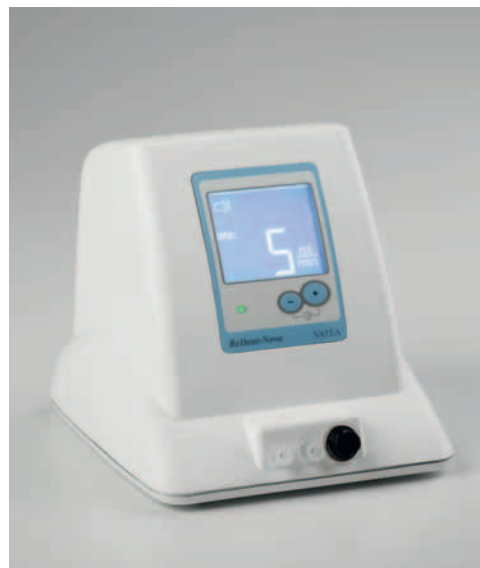

FIG. 8-30 The VATEA continuous irrigation unit used with the SAF instrument. The unit has two containers and provides a continuous flow (low pressure, 5 ml/min) of either irrigant (i.e., sodium hypochlorite and EDTA) through double silicon tubes that are connected to the hubs on the front of the device. It is controlled by finger-operated switches located on the handpiece. (Courtesy ReDent-Nova, Raanana, Israel.)

Because it has no rigid metal core, the file is also extremely adaptable longitudinally. The inherent tendency to straighten curved root canals and transport their apical part to the outer side of the curvature, which is typical of most other file systems, is greatly avoided. The absence of a metal core also makes the SAF extremely resistant to fracture. File separation—a major problem with other NiTi files—has not been reported to occur, and mechanical failure (a rare occurrence if it happens) is limited to local tears in the delicate NiTi lattice.²⁶⁰ It is clear

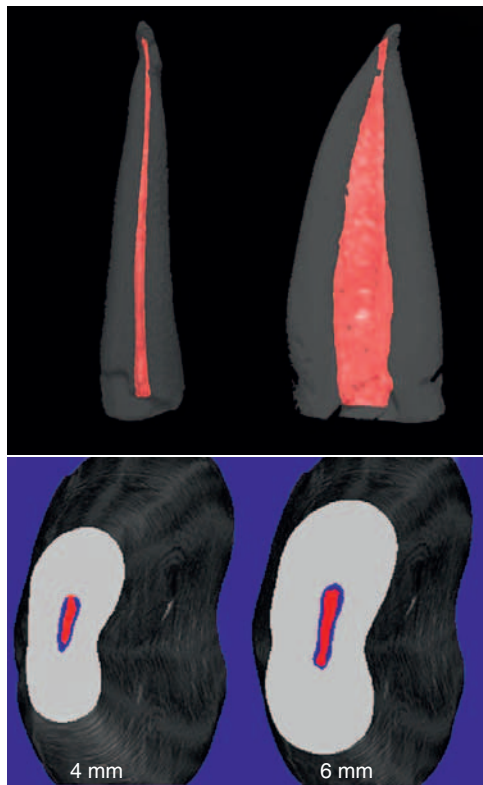


FIG. 8-31 A micro-computed tomography (microCT) analysis of the operation of the SAF instrument in a flat canal with extremely oval cross-section. *Upper:* Buccolingual and mesiodistal views of the root canal reconstructed from microCT. *Lower:* Cross-sections at 4 and 6 mm from the apex. *Red:* before, *blue:* after treatment. (Courtesy ReDent-Nova, Raanana, Israel.)

that this interesting conceptual device will be subjected to extensive independent study over the next few years.

Group V: Engine-Driven Reciprocating Instruments

ENDO-EZE RECIPROCATING FILES

The Giromatic handpiece, a rotary instrument in use since 1969, delivers 3000 quarter-turn reciprocating movements per minute. Rasps and barbed broaches are most often used in Giromatic handpieces, but K-type and H-type instruments also can be used. The Endo-Eze file system (Ultradent, South Jordan, UT) is a recently introduced addition for Giromatic handpieces. The set has four instruments that are designed to clean the middle third of the canal. The sizes and tapers are 0.10 #0.025 taper, 0.13 #0.35 taper, 0.13 #0.45 taper and 0.13 #0.06 taper. The use of stainless steel hand instruments is suggested for the apical third of the canal.

Group VI: Sonic and Ultrasonic Instruments

A radically different way of instrumenting root canals was introduced when clinicians became able to activate files by electromagnetic ultrasonic energy. Piezoelectric ultrasonic units are also available for this purpose (Fig. 8-32). These units activate an oscillating sinusoidal wave in the file with a frequency of about 30 kHz.



FIG. 8-32 P5 Neutron piezoelectric ultrasonic unit. (Courtesy Satelec, Merignac Cedex, France.)



FIG. 8-33 ENAC piezoelectric ultrasonic device. (Courtesy Osada USA, Los Angeles, CA.)

Two types of units, ultrasonic and sonic, are primarily available. Ultrasonic devices, which operate at 25 to 30 kHz, include the magnetostrictive Cavi-Endo (Caulk/Dentsply, Milford, DE), the piezoelectric ENAC (Osada, Tokyo) (Fig. 8-33), the EMS Piezon Master 400 (Electro Medical Systems [EMS] Vallée de Joux, Switzerland), and the P5 Neutron (see Fig. 8-32) (Satelec, Merignac Cedex, France). Sonic devices, which operate at 2 to 3 kHz, include the Sonic Air MM 1500 (Micro Mega, Prodonta, Geneva, Switzerland), the Megasonic 1400 (Megasonic Corp, House Springs, MO), and the Endostar (Syntex Dental Products, Valley Forge, PA). Ultrasonic devices use regular types of instruments (e.g., K-files), whereas sonic devices use special instruments known as Rispi-Sonic, Shaper-Sonic, Trio-Sonic, or Heli-Sonic files.

Although similar in function, piezoelectric units have some advantages over the magnetostrictive systems. For example, piezoelectric devices generate little heat, so no cooling is needed for the electric handpiece. The magnetostrictive system generates considerable heat, and a special cooling system is needed in addition to the irrigation system for the root canal. The piezoelectric transducer transfers more energy to the file

than does the magnetostrictive system, making it more powerful. Working with no water cooling becomes essential when using an operating microscope, because the water spray may obstruct visualization.

The file in an ultrasonic device vibrates in a sinus wave–like fashion. A standing wave has areas with maximal displacement (i.e., antinodes) and areas with no displacement (i.e., nodes). The tip of the instrument exhibits an antinode. If powered too high, especially with no contact with the canal wall, the instrument may break because of the intense vibration. Therefore files must be used only for a short time, must remain passive within the canal, and the power must be controlled carefully. The frequency of breakage in files used for longer than 10 minutes may be as high as 10%, and the breakage normally occurs at the nodes of vibrations.⁵

Ultrasonic devices have proved very efficient for irrigating root canal systems. During free ultrasonic vibration in a fluid, two significant physical effects are observed: cavitation and acoustic streaming. During oscillation in a fluid, a positive pressure is followed by a negative pressure. If the file's tensile strength is exceeded during this oscillation of pressure gradients, a cavity is formed in the fluid in the negative phase. During the next positive-pressure phase, the cavity implodes with great force; this is *cavitation*. Under normal clinical conditions, the power of dental ultrasonic units is too low to create significant cavitation effects on the dentin walls. *Acoustic streaming* creates small, intense, circular fluid movement (i.e., eddy flow) around the instruments. The eddying occurs closer to the tip than in the coronal end of the file, with an apically directed flow at the tip. Acoustic streaming increases the cleaning effect of the irrigant in the pulp space through hydrodynamic shear stress. The increased amplitude that occurs with the smaller file sizes enhances the acoustic streaming.⁶ This has proved valuable in the cleaning of root canals because conventional irrigation solutions do not penetrate small spaces well.

Acoustic streaming has little direct antimicrobial effect. Both cavitation and acoustic streaming are dependent on the free vibration of the file. The limits of the space in a root canal significantly inhibit the practical utility of ultrasonic devices for root canal cleaning. Depending on size and power, the file tip may have amplitudes that require a canal size of at least a #30 file through a #40 file for free oscillation. Any contact with the root canal walls dampens oscillation. As the contact with the canal wall increases, the oscillation is dampened and becomes too weak to maintain acoustic streaming. Using a small file size with minimal contact to the root canal wall provides optimal cleaning conditions.⁷

Ultrasonic devices have proved disappointing as instruments for improving the removal of dentin from the root canal walls. They do improve the ability to clean the pulp space (Fig. 8-34) and difficult-to-débride areas through acoustic streaming.^{12,68,402,403} However, it is unclear whether this can be achieved during regular preparation when the file is actively dampened and little acoustic streaming takes place. Cleaning is further enhanced by the excellent irrigation systems some of the devices provide. Application of a freely oscillating file with sodium hypochlorite (NaOCl) irrigation for several minutes to aid pulp space disinfection is believed to be useful after complete biomechanical instrumentation of the pulp space.³⁶¹



FIG. 8-34 Start-X ultrasonic tip #2 (Dentsply-Maillefer); designed for working on the pulp chamber floor and walls when looking for 2MB canals. Note the surface texture of the instrument that allows long-lasting active surface. (Courtesy Dentsply-Maillefer, Ballaigues, Switzerland.)

Sonic devices are more useful for true hard-tissue removal during root canal preparation. Because the files operate like a conventional handpiece, the file vibrations are less likely to be dampened by contact with the root canal walls. Therefore the special files used in these systems are true bulk dentin removers. New tip designs for piezoelectric ultrasonic units have also been found extremely effective in dentin removal in the pulp chamber and orifice of the canals (see Fig. 8-34).

National and International Standards for Instruments

As a result of concerns that arose nearly 45 years ago, efforts were made to standardize endodontic files and root filling materials. As mentioned previously, this resulted in an international standard for endodontic files, known in the United States as *ANSI standard No. 58* for Hedström files and *ANSI standard No. 28* for K-files (Table 8-1). The standards have several similarities, but some important differences exist. Fig. 8-35 shows the measurements dictated by the standards. The size designation is derived from the projected diameter at the tip of the instrument. This is an imaginary measurement and is not reflected in the real size of the working part of the instrument. The taper of the instruments is designed to be a 0.02 taper, namely a diameter-increase by .02 mm for each mm of length, starting at the tip. The working diameter is the product of the taper and the length of the tip. Three standard lengths are available at 21 mm, 25 mm, and 31 mm. The working part of the instrument must be at least 16 mm. As stated previously, tapers other than .02 and working parts of instruments less than 16 mm are now available and outside the standard.

This system of numbering files with at least 15 different sizes replaced the old, somewhat imperfect system that numbered the sizes from #1 through #6. Although the new standard

TABLE 8-1

Dimensions of Standardized K-File, H-File, and Gutta-Percha Cones (ANSI No. 28, 58, and 78*)

Size	D_0	D_{16}	Color
006	0.06	0.38	No color assigned
008	0.08	0.40	No color assigned
010	0.10	0.42	Purple
015	0.15	0.47	White
020	0.20	0.52	Yellow
025	0.25	0.57	Red
030	0.30	0.62	Blue
035	0.35	0.67	Green
040	0.40	0.72	Black
045	0.45	0.77	White
050	0.50	0.82	Yellow
055	0.55	0.87	Red
060	0.60	0.92	Blue
070	0.70	1.02	Green
080	0.80	1.12	Black
090	0.90	1.22	White
100	1.00	1.32	Yellow
110	1.10	1.42	Red
120	1.20	1.52	Blue
130	1.30	1.62	Green
140	1.40	1.72	Black

*Sizes in italics are for files that are commercially available but not covered by American National Standards Institute (ANSI) regulation No. 28 or No. 58. Colors are not required for instrument handles or gutta-percha cones, but the size must be printed on the handle. Tolerances are ± 0.02 ≥ 30 mm ± 2 mm.

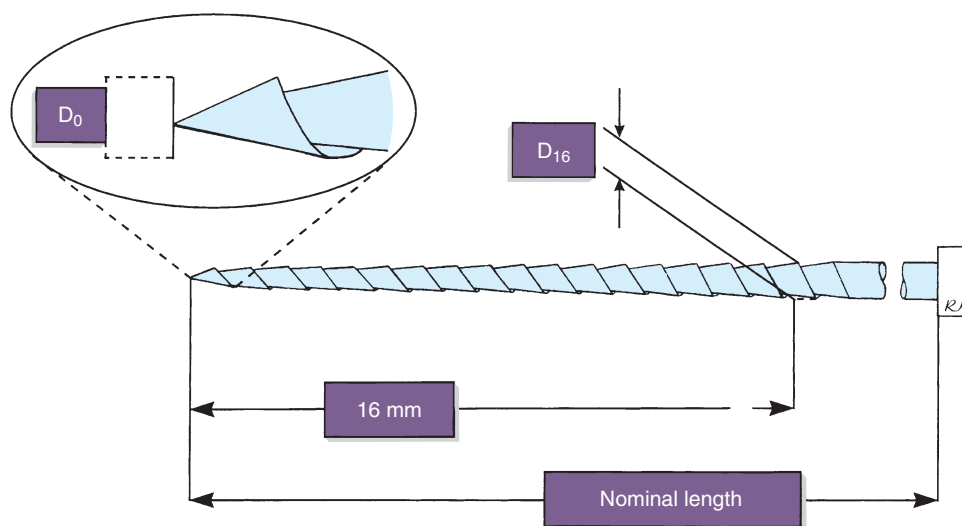


FIG. 8-35 Measuring points for American National Standards Institute (ANSI) and American Dental Association (ADA) regulations #28 and #58, which cover K-type and H-type instruments. The measuring point for the diameter of the instrument (size) is imaginary (D_0) and projects the taper of the instrument at the tip. Therefore an instrument with a short tip is more true to its size than an instrument with a long tip. D_{16} represents the diameter at the end of the working part, which must be at least 16 mm long.

includes many sizes, astute clinicians may include fewer instrument sizes for their special work habits.

In recent years, suggestions to change the numbering system for files with different sizes have been implemented by several manufacturers. One system has introduced “half” sizes in the range of #15 through #60, resulting in instruments in sizes #15, #17.5, #20, #22.5, and so on. Considering the fact that most manufacturers already are unable to size their instruments within the accepted range, the introduction of half sizes seems unnecessary. However, if standards are strictly adhered to, the use of half sizes seems more reasonable for instrument systems such as the LightSpeed, in which the strength of the instrument is such that full-size increments may generate stresses beyond the tolerance of the instrument. The standards are overdue for reevaluation in light of recent technologic changes.

Effectiveness and Wear of Instruments

Although the advertising literature is rich in claims of superiority of various file designs, few of these claims can be verified by well-designed studies in the peer-reviewed endodontic literature. No standards exist for either the cutting or machining effectiveness of endodontic files, nor have clear requirements been established for resistance to wear.

In any study of the effectiveness of an instrument, two factors must be investigated: (1) effectiveness in cutting or breaking loose dentin and (2) effectiveness in machining dentin. These two parameters are radically different. Methods exist for measuring machining, but currently no good method is available for measuring cutting. Some studies have attempted to evaluate cutting, but the methodologies have involved the use of a drilling motion with K-type instruments and at a speed higher than that used for clinical procedures.

Some studies of machining have evaluated the effectiveness of an instrument when used with a linear movement. These studies showed that instruments can differ significantly, not

only when comparing brands and types but also within one brand and type. For K-files, effectiveness varies 2 to 12 times between files of the same brand. The variation for Hedström files is greater, ranging from 2.5 to more than 50 times.³⁷⁹ The greater variation among Hedström files is easy to understand because the H-file is the result of more individual grinding during manufacture than the conventional K-file, which is difficult to alter much during the manufacturing process. For example, during the grinding of a Hedström file, the rake angle can be modified to neutral or even slightly positive; this is impossible to achieve with a K-file. The Hedström file, therefore, is approximately 10 times more effective at removing dentin than the K-file.

In the machining process, the rake edge shaves off dentin that accumulates in the grooves between the rake edges. The deeper and larger this space, the longer the stroke can be before the instrument is riding on its own debris, making it ineffective. These design variations and the rake angle of the edges determine the effectiveness of a Hedström file. Of the hybrid files, the K-Flex (SybronEndo, Orange, CA) file, which is a modified K-file, shows variables similar to those of K-files. The Flex-R file (SybronEndo, Orange, CA), which is a ground instrument, more closely resembles the H-files in its variation in effectiveness. It also is much more effective at substrate removal than the K-files but cannot measure up to the H-files' ability to machine.

Modern endodontic stainless steel instruments are fabricated from excellent metal alloys and have considerable resistance to fracture. The clinician who practices careful application of force and a strict program of discarding instruments after use should have few instrument fractures. Stainless steel files are so inexpensive that adequate cleaning and sterilization for reuse of files in sizes up to #60 may not be cost effective. If this is the case, files in the range up to #60 may be considered disposable instruments.

Devices for Periapical Débridement Through a Root Canal Access

The Apexum device (Apexum, Or-Yehuda, Israel) is currently the single representative of this group^{258,259} (Fig. 8-36). It represents a totally different concept than that applied by most root canal cleaning and shaping systems. The goals of most current concepts are to maintain the original apical constriction by all means and to avoid any substantial overinstrumentation past the apical foramen. The Apexum concept requires widening the apical foramen to create an opening 330 μm in diameter by passing a #30 file 1 mm beyond the apex. This may represent some enlargement of the apical foramen in certain cases, but in other cases, the natural apical foramen diameter may be larger than this.⁴³ Further instrumentation with larger instruments (#40 or #45) to a length 1 mm short of the apical foramen are then used to recreate an artificial apical stop and constriction.

Two miniature devices are then used to débride the periapical tissues through the root canal access. The first is the Coarse Apexum Ablator, which is made from a prebent memory-shape NiTi wire encased in a NiTi tube that serves as its sheath (see Fig. 8-36). The instrument, still encased in its sheath, is inserted to the artificial apical stop. Then the inner wire is gently pushed through the apical foramen and into the periapical lesion.

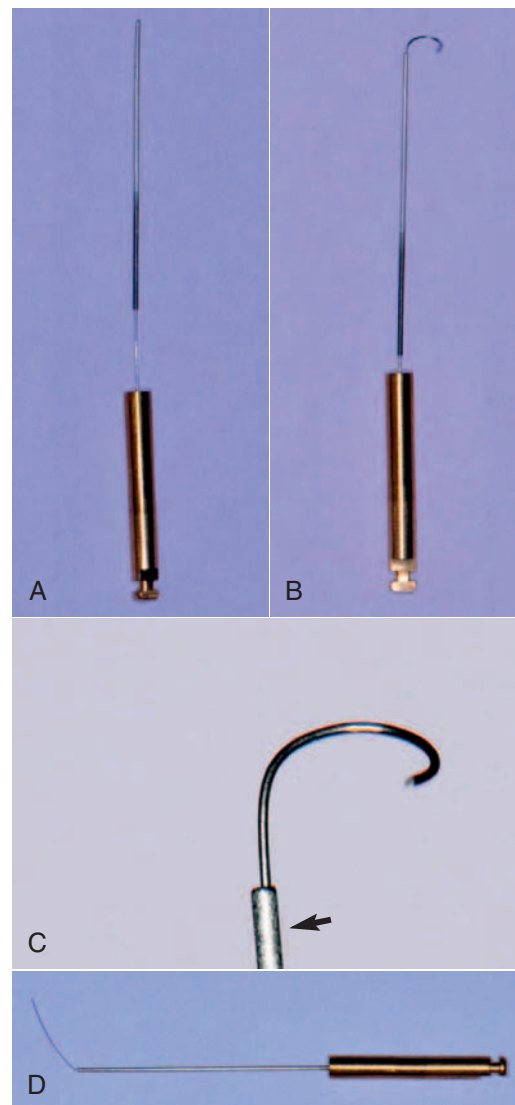


FIG. 8-36 Apexum device. **A**, The Coarse Apexum Ablator in its NiTi sheath (arrow in **C**). **B-C**, The active part was extruded and regained its preformed shape that allows it to rotate in the periapical lesion (250 rpm, 30 sec), mincing the soft tissue without engaging the walls of the bony crypt. **D**, The Fine Apexum Ablator, inserted into the lesion after the Coarse Apexum Ablator is removed; rotates at 7000 rpm for 30 seconds, turning the minced tissue into a thin suspension that can be washed out.^{258,259} (Courtesy Apexum, Or-Yehuda, Israel.)

While in the periapical area, it regains its prebent shape (Figs. 8-37 and 8-38). It is then attached to a low-speed hand-piece and rotated at 250 rpm for 30 seconds, thus coarsely mincing the periapical tissues. The first instrument is then removed, and the second instrument, the Fine Apexum Ablator, is inserted, passed through the apical foramen, and rotated at 7000 rpm for 30 seconds, turning the tissue into a thin suspension. The resulting suspension is then washed out coronally through the canal space using sterile saline solution delivered into the periapical area using a syringe and a thin, 30-gauge blunt needle.

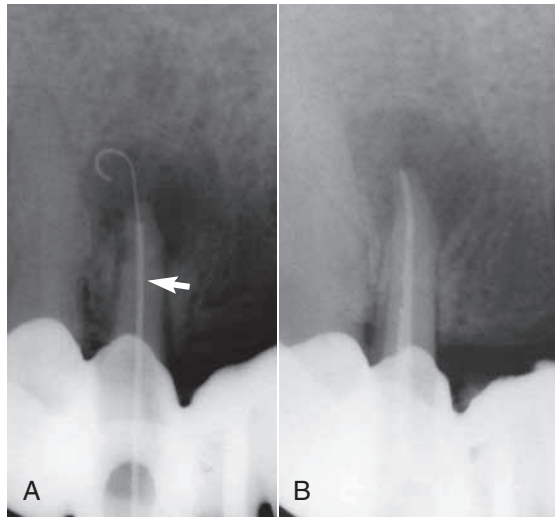


FIG. 8-37 Apexum in clinical use. **A**, The Coarse Apexum Ablator in a periapical lesion of an upper single rooted tooth. Note the sheath in the root canal (*arrow*). **B**, Root canal obturation (lateral condensation) immediately after the Apexum procedure has been completed.²⁵⁸ (Courtesy Apexum, Or-Yehuda, Israel.)

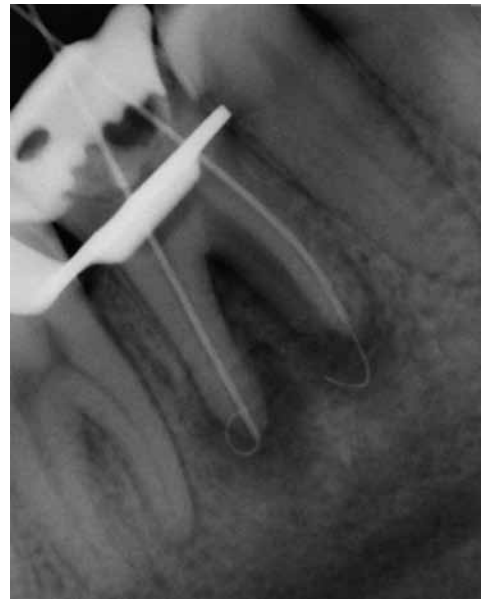

FIG. 8-38 Apexum in clinical use. A lower molar with two Coarse Apexum Ablator devices in the mesial and distal periapical lesions. Note the distance from the inferior alveolar nerve canal. Both instruments were inserted at the same time for purposes of illustration. (Courtesy Apexum, Or-Yehuda, Israel.)

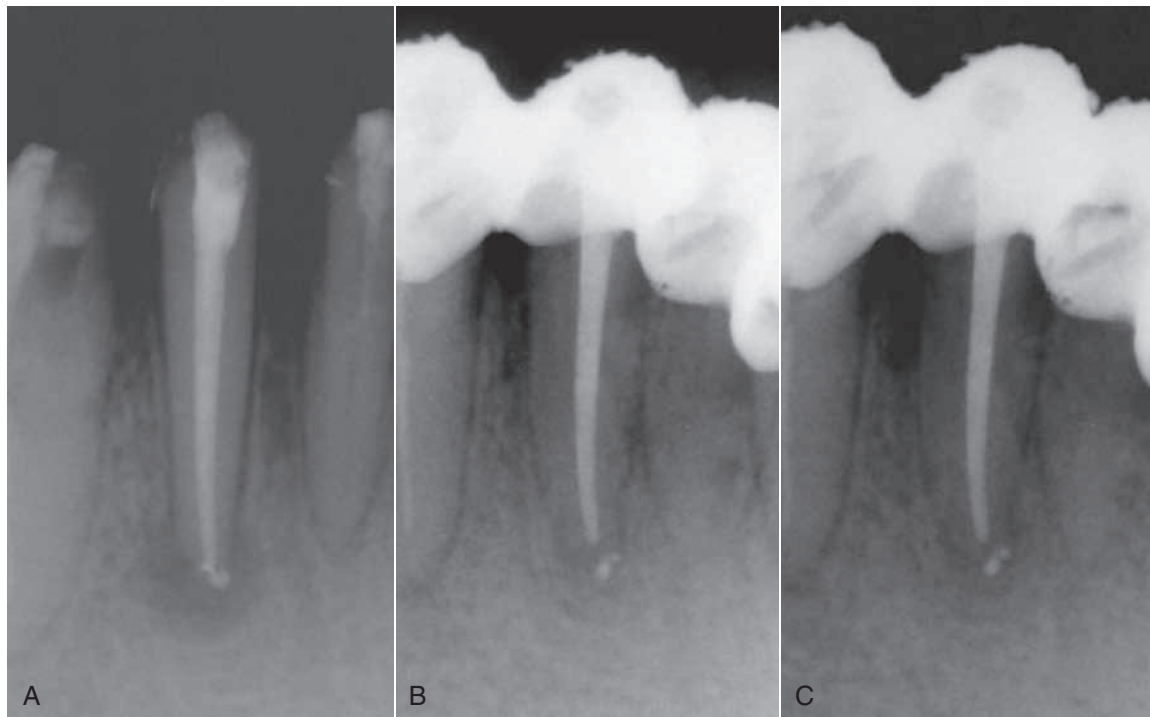


FIG. 8-39 Periapical healing after the Apexum procedure. **A**, Immediate postoperative radiograph. Note the periapical lesion. **B**, Three-month follow up. **C**, Six-month follow-up.²⁵⁸ (Courtesy Apexum, Or-Yehuda, Israel.)

The method is used as a supplementary treatment for enhancement the healing kinetics of periapical lesions for promoting faster healing (Fig. 8-39).^{258,259} The Apexum procedure is applied only after completion of cleaning, shaping, and disinfection of the root canal and before root canal obturation.

Devices for Measuring Root Canal Length

Radiographs, tactile sensation, the presence of bleeding on paper points, and knowledge of root morphology have been used to determine the length of root canal systems. Sunada³⁸¹ developed the original electronic apex locator when he sug-

gested that the apical foramen could be localized using a direct electric current. Currently the electronic apex locator is considered an accurate tool for determining working length.^{114,115} One study reported that the use of electronic apex locators in a dental student clinic resulted in a higher quality of obturation length control and an overall reduction in the number of radiographs taken.¹¹⁵ However, these devices must not be considered flawless, because several variables are known to affect their accuracy. For example, immature roots can present problems.¹⁸⁰ Once the roots mature (i.e., formed a narrow apical foramen) and the instruments are able to contact the canal walls, the electronic apex locator's accuracy greatly improves. Some investigators have found no statistical difference between roots with vital and necrotic tissue.^{135,250} Because apical root resorption is prevalent in necrotic cases with long-standing apical lesions, these researchers also concluded that apical resorption does not have a significant effect on the accuracy of electronic apex locators.

Recently some clinicians have advocated the use of the electronically determined working length in lieu of working length estimations using the placement of a file in the canal and a radiograph. However, combined use of both of these techniques has been shown to result in greater accuracy.⁹⁵ Furthermore, radiographs may also add essential anatomic information that may be missed if electronic apex locators are used exclusively.

The first two generations of electronic apex locators were sensitive to the contents of the canal and irrigants used during treatment. The development of an algorithm called the *ratio measurement method* distinguished the third generation of apex locators.¹⁹⁷ To arrive at this method, the impedance of the canal was measured with two current sources of different frequencies, and a quotient was determined using the electrical potentials proportional to each impedance.¹⁹⁷ This study found that electrolytes did not have a significant effect on the accuracy of the unit. Some third-generation apex locators are the Endex Plus, or Apit, (Osada, Los Angeles, CA),¹⁴¹ the Root ZX (Fig. 8-40) (J. Morita, Kyoto, Japan),^{114,211} and the Neosono

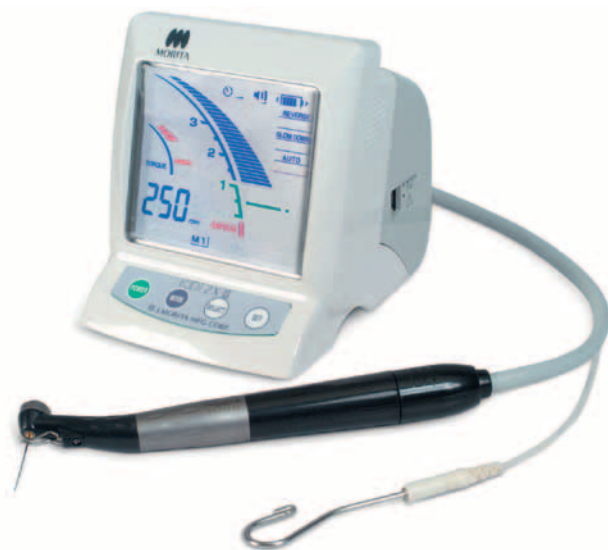

FIG. 8-40 Root ZX apex locator with lip clip and file holder. (Courtesy J. Morita USA, Irvine, CA.)

Ultima EZ (Satelec, Mount Laurel, NJ). The Endex Plus device uses 1 and 5 kHz and provides apex location based on subtraction. The Root ZX emits currents at frequencies of 8 and 0.4 kHz and provides apex location based on the resulting quotient.

A fourth-generation apex locator was introduced with the Elements Diagnostic Unit (see Fig. 8-44), the Apex Locator (SybronEndo), and the Bingo 1020/Ray-X4 (Forum Engineering Technologies, Rishon Lezion, Israel). The Bingo uses only one of its two frequencies at a time (8 Hz or 400 Hz). According to the manufacturer, the Elements unit (which operates at frequencies of 0.5 and 4 kHz) compares the resistance and capacitance information to a database to determine the distance between the file and the apex. When the file tip reaches the area of the apical foramen, the apex locator emits a signal.

Recently, miniaturized electronic apex locators were introduced by SybronEndo (Fig. 8-41) and MedicNRG, Kibutz Afikim, Israel (the Apex NRG^{277,278}) (Fig. 8-42).

An apex locator typically has four parts: (1) the lip clip, (2) the file clip, (3) the instrument itself, and (4) a cord connecting the other three parts. A display indicates the advancement of the file toward the apex (see Fig. 8-40).

These electrical instruments are generally safe, but manufacturers' instructions state that they should not be used on patients with pacemakers without consulting the patient's cardiologist.^{30,113} When connected directly to cardiac pacemakers in vitro, four of five electronic apex locators did not interfere with the function of the pacemaker.¹²⁶

Instruments for Root Canal Obturation

After the root canal has been properly cleaned and enlarged, the space is obturated with a manufactured material. A number of obturation methods are practiced, but lateral and vertical compactions are the two most common. Many specialized



FIG. 8-41 SybronEndo mini apex locator. (Courtesy SybronEndo, Orange, CA.)

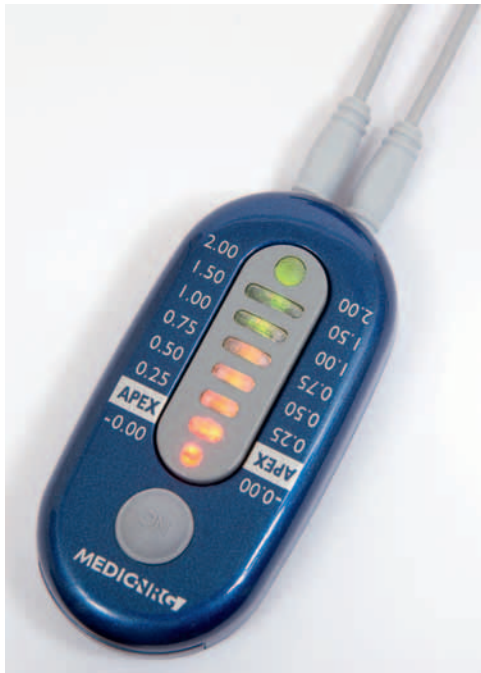

FIG. 8-42 NRG miniature electronic apex locator. (Courtesy Medic-NRG, Kibutz Afikim, Israel.)

instruments are available for every type of method. Spreaders and pluggers are the significant instruments for obturation. The spreader is a tapered, pointed instrument intended to displace gutta-percha laterally for insertion of additional accessory gutta-percha cones. The plugger is similar but has a blunt end. In smaller sizes, the spreader and plugger are often used interchangeably. These instruments are available with handles or as finger-held instruments. The instruments with handles are potentially dangerous because the tips of the working ends are offset from the long axes of the handles. This results in strong lateral wedging forces on the working ends if the instruments are not operated carefully. The risk of vertical damage to the root is greatly reduced with finger spreaders and pluggers. Each clinician must choose the appropriate spreader and plugger according to personal working preferences. Standardized instruments are available with the same taper as the files (e.g., #.02). Considering the greater taper of standardized accessory gutta-percha cones (Table 8-2), nonstandardized spreaders with a larger taper sometimes may be used to better accommodate the gutta-percha.

When using spreaders and accessory gutta-percha cones, the accessory cone selected must reach the depth of the penetration of the spreader. To accomplish that, the accessory cone must be *thinner* and/or with a *smaller taper* than the spreader used. If accessory cones which do not reach that depth are used, the procedure will result in voids at the apical end of each spreader penetration, leading the operator to an illusion that the root canal is properly obturated.

In recent years, spreaders and pluggers have become available in nickel-titanium. NiTi spreaders have been shown to reach deeper into canals than the stainless steel type when #.02 tapered gutta-percha is used in canals with a curvature of more than 20 degrees. When #.04 taper gutta-percha was used, the



FIG. 8-43 System B heating device for vertical compaction and removal of gutta-percha. (Courtesy SybronEndo, Orange, CA.)

TABLE 8-2

Size Designations for Auxiliary Gutta-Percha Cones*

Designation	D ₃	D ₁₆	Taper
XF	0.20	0.45	0.019
FF	0.24	0.56	0.025
MF	0.27	0.68	0.032
F	0.31	0.80	0.038
FM	0.35	0.88	0.041
M	0.40	1.10	0.054
ML	0.43	1.25	0.063
L	0.49	1.55	0.082
XL	0.52	1.60	0.083

*The cones are pointed. The diameters 3 mm (D₃) and 16 mm (D₁₆) from the tip are prescribed. Tolerance is ± 0.05 mm, and length is ≥ 30 mm ± 2 mm. XF, Extra-fine; FF, fine-fine; MF, medium-fine; FM, fine-medium; M, medium; ML, medium-large; L, large; XL, extra-large.

NiTi spreaders were more effective regardless of the degree of curvature.⁴²⁴

Heat carriers are used for vertical-compaction obturation techniques. Traditionally, heat carriers are handled similarly to pluggers. They are used to transfer heat to the gutta-percha in the root canal, allowing apical and lateral displacement of the gutta-percha. Electrical heat carriers are more common today, either as independent units such as Touch 'n Heat (SybronEndo) and System B (SybronEndo) (Fig. 8-43), or incorporated into multifunctional systems such as Elements (Fig. 8-44) (SybronEndo). Recently, battery-charged, handheld heat carriers were introduced, such as the vibrating heat carrier DownPack⁶⁷ (Hu-Friedy, Chicago, IL) (Fig. 8-45) or HotTip (Fig. 8-46) (Discus Dental, Culver City, CA). These devices can be heated to controlled levels with a self-contained cordless unit.



FIG. 8-44 Elements unit, combining a System B element with one delivering injectable gutta-percha. (Courtesy SybronEndo, Orange, CA.)

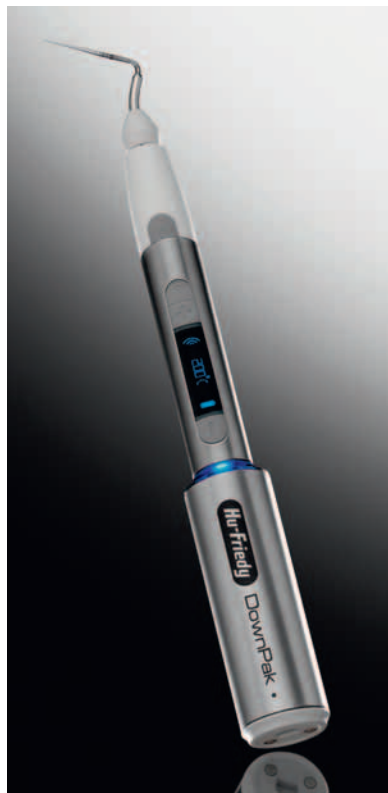

FIG. 8-45 DownPak: hand-held heating and vibrating unit for warm gutta-percha compaction. (Courtesy Hu-Friedly, Chicago, IL.)

A Lentulo spiral may be used for placement of the sealer, cement, and calcium hydroxide ($\text{Ca}[\text{OH}]_2$) dressings. The Lentulo spiral is a safe instrument if used correctly but if used carelessly, it may engage the wall of the root canal and break. It must be operated clockwise in the handpiece, inserted not rotating to working length, then retracted 1 to 2 mm to make



FIG. 8-46 HoTip: hand-held heating unit for warm gutta-percha compaction. (Courtesy Discus, Culver City, CA.)

sure it is free to rotate without engaging the canal walls. It should be started and rotated at a slow speed while being gradually withdrawn from the root canal. This instrument effectively drives the paste into the root canal. However, for optimal effect, the spiral must be as large as possible so that the paste is forced forward as the material is squeezed between the canal walls and the spiral. Endodontic files, paper points, and syringes also are commonly used to apply sealer in the root canal system, but they are all less effective than a Lentulo spiral if filling a root canal entirely with sealer is desired.

Devices for Removing Root Canal Obstructions

There are many devices available for removing natural and manufactured obstructions from within the canal. Please see Chapter 25 for details on these devices.

MATERIALS FOR DISINFECTING THE PULP SPACE

Chemomechanical Preparation

To increase the efficacy of mechanical preparation and bacteria removal, instrumentation must be supplemented with active irrigating solutions. *Irrigation* is defined as washing out a body cavity or wound with water or a medicated fluid. *Aspiration* is defined as the process of removing fluids or gases from the body with a suction device.

The objectives of irrigation are both mechanical and biologic. The mechanical objective involves flushing out debris, lubricating the canal, and dissolving organic and inorganic tissue. The biologic function of the irrigants is related to their antimicrobial effect.

Irrigation Hydrodynamics

The effectiveness of root canal irrigation in terms of debris removal and eradication of bacteria depends on several factors: penetration depth of the needle, diameter of the root canal, inner and outer diameter of the needle, irrigation pressure, viscosity of the irrigant, velocity of the irrigant at the needle tip, and type and orientation of the needle bevel (Box 8-3).¹⁸¹

The size and length of the irrigation needle relative to the canal space dimension is of utmost importance for the effectiveness of proper irrigation. If the external diameter of the needle is too large or rigid, it may inhibit introduction of the irrigant into the more apical extent of the root canal or into areas of curved canals. The internal diameter of the needle correlates to the necessary pressure for moving the syringe plunger and the velocity at which the irrigant is expressed. Narrow needles require more pressure of the plunger and will extrude the irrigant with higher velocity than large needle diameters. Although a needle with a larger internal diameter

BOX 8-3**Ideal Characteristics of an Endodontic Irrigant**^{58,149,390}

The ideal irrigant should:

1. Be an effective germicide and fungicide.
2. Be nonirritating to the periapical tissues.
3. Remain stable in solution.
4. Have a prolonged antimicrobial effect.
5. Be active in the presence of blood, serum, and protein derivatives of tissue.
6. Have low surface tension.
7. Not interfere with repair of periapical tissues.
8. Not stain tooth structure.
9. Be capable of inactivation in a culture medium.
10. Not induce a cell-mediated immune response.
11. Be able to completely remove the smear layer, and be able to disinfect the underlying dentin and its tubules.
12. Be nonantigenic, nontoxic, and noncarcinogenic to tissue cells surrounding the tooth.
13. Have no adverse effects on the physical properties of exposed dentin.
14. Have no adverse effects on the sealing ability of filling materials.
15. Have convenient application.
16. Be relatively inexpensive.

will extrude the irrigant with a larger volume over time, the irrigant cannot be introduced as deeply. Moser & Heuer²⁷⁶ measured the pressure necessary for activation of the plunger in different sizes and types of irrigation needles. They determined lower pressure was necessary for irrigation with larger needle diameter sizes (23 to 24 gauge) compared with smaller diameter sizes (24 to 30 gauge). However, larger needles placed at a greater distance from the apex were less efficient during irrigation than smaller diameter needles placed closer to the apex.¹⁷⁴ Common injection needles have an external diameter of 0.40 mm (27 gauge), but special irrigation tips with external diameters of 0.30 mm (30 gauge) are available as well (Table 8-3). To improve safety of irrigation and prevent apical extrusion of the irrigant, some of these needles release the solution through lateral openings and have a closed, safe-ended tip (Fig. 8-47). The Stropko Flexi-Tip (30 gauge) needle is fabricated out of NiTi to improve its flexibility and penetration into curved canals.

Sodium Hypochlorite

NaOCl is the most commonly used irrigating solution. It is an excellent antibacterial agent, capable of dissolving necrotic tissue, vital pulp tissue, and the organic components of dentin and biofilms.³⁴³

NaOCl solution, commonly known as *bleach*, is frequently used as a disinfectant or a bleaching agent. It is the irrigant of choice in endodontics, owing to its efficacy against pathogenic organisms and pulp digestion, and satisfies most of the preferred characteristics stated earlier.

History

Hypochlorite was first produced in 1789 in Javelle, France, by passing chlorine gas through a solution of sodium carbonate. The resulting liquid, known as “Eau de Javelle” or “Javelle

TABLE 8-3

Sizes and Manufacturers of Needles Used for Root Canal Irrigation

Manufacturer	Product	Gauge
Dentsply	Max-I-Probe	21–30
Ultradent, South Jordan, UT, USA	NaviTip	29, 30
	NaviTip FX Tip (brush-covered needle)	30
	Capillary Tip	25, 28
	Endo-Eze Tip/Deliver Eze	18, 19, 20, 22, 30, 31
	Endo-Eze Irrigator Tip/Deliver Eze Spülkanüle	27
KerrHawe, Bioggio, Switzerland	NaviTip	21–30
Hager & Werken, Duisburg, Germany	Miraject Endotec	21–25
Vista Dental Products	Stropko Flexi-Tip (NiTi)	30
KerrHawe	KerrHawe irrigation probe	
Transcoject, Neumünster, Germany	Spülkanülen Endo	23, 25, 27, 30

Adapted from Hülsmann M, Rödiger T, Nordmeyer S: Complications during root canal irrigation. *Endod Topics* 16:27, 2007.

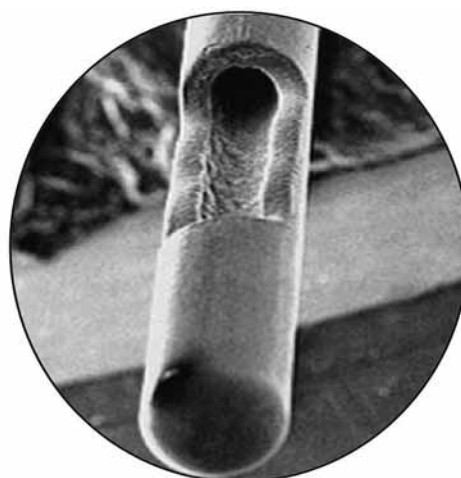


FIG. 8-47 Scanning electron microscope (SEM) image of 30-gauge safety needle. (Courtesy Dr F. Tay.)

water” was a weak solution of NaOCl. However, this process was not very efficient, and alternate production methods were sought. One such method involved the extraction of chlorinated lime (known as *bleaching powder*) with sodium carbonate to yield low levels of available chlorine. This method was

commonly used to produce hypochlorite solutions for use as a hospital antiseptic that was sold under the trade names “Eusol” and “Dakin’s solution.” NaOCl as a buffered 0.5% solution was recommended for the irrigation of wounds during World War I by Dakin.⁷⁴ Coolidge⁶⁹ later introduced NaOCl to endodontics.

Mode of Action

Please see Chapter 9 for further information on this subject.

Allergic Reactions to Sodium Hypochlorite

Although few reports have been published^{101,156} on allergic-like reactions to NaOCl, real allergies to NaOCl are unlikely to occur, since both sodium and chlorine are essential elements in the physiology of the human body. Nevertheless, hypersensitivity and contact dermatitis may occur in rare cases. In cases of hypersensitivity to NaOCl, chlorhexidine should not be used either (because of its chlorine content). Use of an alternative irrigant with high antimicrobial efficacy, such as iodine potassium iodide, should be considered, assuming there is no known allergy to the irrigant. Irrigants such as alcohol or tap water are less effective against microorganisms and do not dissolve vital or necrotic tissue. Ca(OH)₂ could be used as a temporary medicament because it dissolves both vital and necrotic tissue.^{10,161}

Increasing the Efficacy of Hypochlorite Preparations

One alternative approach to improving the effectiveness of hypochlorite irrigants in the root canal system⁴³⁹ could be to increase the temperature of low-concentration NaOCl solutions, which improves their immediate tissue-dissolution capacity. Furthermore, heated hypochlorite solutions remove organic debris from dentin shavings more efficiently. The antimicrobial properties of heated NaOCl solutions have also been evaluated. The bactericidal rates for NaOCl solutions are more than doubled for each 5° C rise in temperature in the range of 5° C to 60° C. This was corroborated in a recent study³⁵⁹ using steady-state planktonic *Enterococcus faecalis* cells. A temperature rise of 25° C increased NaOCl efficacy by a factor of 100. The capacity to dissolve human dental pulp using 1% NaOCl at 45° C was found to be equal to that of a 5.25% solution at 20° C. Additionally, the systemic toxicity of preheated low concentrations of NaOCl irrigants should be less than the that of a more concentrated unheated solution. However, there are no clinical studies available at this point to support the use of heated NaOCl.

In this context, it should also be noted that time is a factor that has gained little attention in endodontic studies. Even fast-acting biocides such as NaOCl require an adequate working time to reach their potential. Chlorine, which is responsible for the dissolving and antibacterial capacity of NaOCl, is unstable and consumed rapidly during the first phase of tissue dissolution, probably within 2 minutes.²⁶⁸ Continuous replenishment of the irrigant is essential, especially since rotary root canal preparation techniques have expedited the shaping process. The optimal time a hypochlorite irrigant needs to remain in the canal system is an issue yet to be resolved.

Chlorhexidine

History

Chlorhexidine (CHX) was developed more than 50 years ago at Imperial Chemical Industries in England and first marketed in the United Kingdom in 1953 as an antiseptic cream.¹⁰⁴ Since 1957 it has been used for general disinfection purposes and the treatment of skin, eye, and throat infections in both humans and animals.^{104,231}

Molecular Structure

CHX belongs to the polybiguanide antibacterial family, consisting of two symmetric four-chlorophenyl rings and two biguanide groups connected by a central hexamethylene chain. CHX is a strongly basic molecule and is stable as a salt. CHX digluconate salt is easily soluble in water.¹⁴⁷

Mode of Action

CHX is a wide-spectrum antimicrobial agent, active against gram-positive and gram-negative bacteria as well as yeasts.⁸¹ Owing to its cationic nature, CHX is capable of electrostatically binding to the negatively charged surfaces of bacteria,⁷² damaging the outer layers of the cell wall and rendering it permeable.^{165,178,179}

Depending on its concentration, CHX can have both bacteriostatic and bactericidal effects. At high concentrations CHX acts as a detergent; by damaging the cell membrane, it causes precipitation of the cytoplasm and thereby exerts a bactericidal effect. At low sublethal concentrations, CHX is bacteriostatic, causing low molecular-weight substances (i.e., potassium and phosphorous) to leak out without the cell being irreversibly damaged. It also can affect bacterial metabolism in several other ways, such as abolishing sugar phosphotransferase system (PTS) transport activity and inhibiting acid production in some bacteria.²⁵

Substantivity

Due to the cationic nature of the CHX molecule, it can be absorbed by anionic substrates such as the oral mucosa.^{237,240} CHX has the ability to bind to proteins such as albumin, present in serum or saliva, pellicle found on the tooth surface, salivary glycoproteins, and mucous membranes.^{317,398} This reaction is reversible.¹⁶⁹ CHX can also be adsorbed onto hydroxyapatite and teeth. Studies have shown that the uptake of CHX onto teeth is also reversible. This reversible reaction of uptake and release of CHX leads to substantive antimicrobial activity and is referred to as *substantivity*. This effect depends on the concentration of CHX. At low concentrations of 0.005% to 0.01%, a stable monolayer of CHX is adsorbed and formed on the tooth surface, which might change the physical and chemical properties of the surface and may prevent or reduce bacterial colonization. At higher concentrations (>0.02%), a multilayer of CHX is formed on the surface, providing a reservoir of CHX which can rapidly release the excess into the environment as the concentration of CHX in the surrounding environment decreases.⁹⁷

The antibacterial substantivity of three concentrations of CHX solution (4%, 2%, and 0.2%) after 5 minutes of application has shown a direct relationship between the concentration of CHX and its substantivity.²⁷¹ On the contrary, Lin et al.²²⁶ attributed the substantivity of CHX to its ability to adsorb onto

the dentin during the first hour. They stated that it is only after the saturation point is reached after the first hour that the antimicrobial capability of CHX increases with time. Furthermore, Komorowski et al.¹⁹⁹ revealed that a 5-minute application of CHX did not induce substantivity, so dentin should be treated with CHX for 7 days. Taken together, it seems that residual antimicrobial activity of CHX in the root canal system remains for up to 12 weeks.

Cytotoxicity

In the medical field, CHX is normally used at concentrations between 0.12% and 2.0%. According to Løe,²³¹ at these concentrations, CHX has a low level of tissue toxicity, both locally and systemically. In another report, when 2% CHX was used as a subgingival irrigant, no apparent toxicity was noted on gingival tissues.^{232,369} Moreover, CHX rinses have been reported to promote the healing of periodontal wounds.¹⁴ Based on these reports, Jeansonne et al.¹⁸⁴ assumed that the periapical tissues would be as tolerant to CHX as gingival tissues. In two studies when CHX and NaOCl were injected into subcutaneous tissues of guinea pigs and rats, an inflammatory reaction developed; however, the toxic reaction from CHX was less than that of NaOCl.^{289,432} Furthermore, when CHX was applied as a rinse in the extraction sites of the third molars on the day of surgery and several days after, it was reported to reduce the incidence of alveolar osteitis.⁵⁶ There are only a few reports in the literature of allergic and anaphylactic reactions to CHX.^{127,286}

Conversely, some studies have reported unfavorable effects of CHX on the tissues. Hidalgo¹⁶⁸ demonstrated that CHX is cytotoxic to some lines of cultured human skin fibroblasts. Recently the behavior of osteoblastic human alveolar bone cells in the presence of CHX and povidone iodine (PI) has been investigated. It has been reported that CHX has a higher cytotoxicity profile than povidone iodine.⁴⁹ Faria et al.¹⁰⁵ also demonstrated that CHX injected in the hind paw of mice could induce severe toxic reactions. They reported that CHX induced apoptosis at lower concentrations and necrosis at higher concentrations when added to cultured L929 fibroblast cells.

Another interesting observation has recently been reported whereby the byproduct of combining CHX with NaOCl is the formation of toxic breakdown products such as parachloroaniline (PCA) that may have a negative impact on tissues.²⁶ The toxicity level of CHX on periapical tissues when applied in the root canals, especially with other irrigants, merits further investigation.

Chlorhexidine Application in Endodontics

CHX has been extensively studied as an endodontic irrigant and intracanal medication, both in vivo^{20,228,239,293} and in vitro.* In vitro, CHX has at least as good or even better antimicrobial efficacy than Ca(OH)₂.³⁵⁴ Notably, 2% CHX was very effective in eliminating a biofilm of *E. faecalis*.²²³ In vivo, it inhibits experimentally induced inflammatory external root resorption when applied for 4 weeks.²²⁸ In infected root canals, it reduces bacteria as effectively as Ca(OH)₂ when applied for 1 week.²⁰ Unlike Ca(OH)₂, CHX has substantive antimicrobial activity that, if imparted onto the root dentin, has the potential to prevent bacterial colonization of root canal walls for prolonged periods of time.^{184,199} This effect depends on the concentration

of CHX, but not on its mode of application, which may be as a liquid, gel, or controlled-release device.²⁷

Chlorhexidine as an Endodontic Irrigant

CHX in liquid and gel form has been recommended as an irrigant solution, and its different properties have been tested in several studies, both in vitro¹³⁷ and in vivo.* Many investigations have conducted studies on the antibacterial effectiveness of CHX in different concentrations. It has been demonstrated that 2% CHX as an irrigant has a better antibacterial efficacy than 0.12% CHX in vitro, so the antibacterial efficacy of CHX evidently depends on its concentration level.²⁸ Since NaOCl is still the most commonly used irrigant, the antibacterial efficacy of CHX has been compared to that of NaOCl. The results from these studies are inconclusive, but in general, no significant difference between the two solutions has been reported. Unlike NaOCl, CHX lacks a tissue-dissolving property. Therefore, NaOCl is still considered the primary irrigating solution in endodontics.

The cleanliness of root canals by CHX in gel and liquid forms was evaluated using scanning electron microscopy in two separate experiments. In an in vitro study, the canals treated with 2% CHX gel were cleaner than those treated with 2% CHX liquid or 5.25% NaOCl, and it was suggested that the mechanical action of the gel might have facilitated the cleansing of the canals. Another in vitro study showed that the 2% CHX liquid was inferior to 2.5% NaOCl in cleaning the canals.⁴³¹

The antibacterial effectiveness of CHX in infected root canals has been investigated in several studies. Investigators³¹⁵ reported that 2.5% NaOCl was significantly more effective than 0.2% CHX when the infected root canals were irrigated for 30 minutes with either of the solutions.

In a controlled and randomized clinical trial, the efficacy of 2% CHX liquid was tested against saline using culture technique. All the teeth were initially instrumented and irrigated using 1% NaOCl. Then either 2% CHX liquid or saline was applied as a final rinse. The authors reported a further reduction in the proportion of positive cultures in the CHX group. Their results showed a better disinfection of the root canals using CHX compared to saline as a final rinse.⁴³⁷

In a recent study, the antibacterial efficacy of 2% CHX gel was tested against 2.5% NaOCl in teeth with apical periodontitis, with the bacterial load assessed using real-time quantitative polymerase chain reaction (RTQ-PCR) and colony forming units (CFU). The bacterial reduction in the NaOCl group was significantly greater than the CHX group when measured by RTQ-PCR. Based on culture technique, bacterial growth was detected in 50% of the CHX-group cases compared to 25% in the NaOCl group.⁴⁰⁵ On the other hand, another study based on this culture technique revealed no significant difference between the antibacterial efficacy of 2.5% NaOCl and 0.12% CHX liquid when used as irrigants during the treatment of infected canals.^{356,357}

Chlorhexidine as an Intracanal Medication

CHX in liquid, gel, or in a controlled-release device has been suggested as an alternative intracanal medication to replace Ca(OH)₂. This has been the focus of many in vitro^{78,199,217,354}

*References 24, 27, 28, 184, 199, and 217.

*References 99, 208, 220, 356, 357, 386, 405, and 437.

and in vivo studies.* The results of in vitro experiments were mostly in favor of CHX regardless of its mode of application. The results have also demonstrated the potential antibacterial substantivity of CHX in the root canals.

Researchers¹⁵⁵ developed an experimental model using dentin powder particles to investigate the possible inactivation of some antibacterial medicaments when they come in contact with dentin. The medicaments tested were $\text{Ca}(\text{OH})_2$, 1% NaOCl, 0.5% and 0.05% CHX acetate, and different concentrations of iodine potassium iodide (IKI). They showed that dentin powder had inhibitory effects on all medicaments tested. The effect was dependent on the concentration of the medicament and the duration of contact. The effect of $\text{Ca}(\text{OH})_2$ was totally abolished by the presence of dentin powder. The effect of 0.05% CHX and 1% NaOCl was reduced but not totally eliminated by the presence of dentin. No inhibition could be measured when full-strength solutions of CHX and IKI were used.

Contradicting results have been reported when evaluating the effect of different intracanal medications on sealing of the root canals. In an in vitro study using extracted human teeth, all root canals, after 10 days of intracanal medication, were obturated and then tested for microbial leakage. The root canals medicated with CHX gel demonstrated less resistance against bacterial leakage compared to the root canals medicated with $\text{Ca}(\text{OH})_2$.²³ In contrast, Wuerch et al.⁴³⁰ found no significant difference in leakage between the canals medicated with CHX and $\text{Ca}(\text{OH})_2$ and reported that 2% CHX gel and $\text{Ca}(\text{OH})_2$ paste did not adversely affect the apical seal of the root canal system.

In a human ex vivo model, the antibacterial efficacy of 0.2% CHX liquid applied for 24 hours was tested against a saline solution. After extraction, the infected teeth were endodontically treated using CHX or saline for irrigation and then further medicated with either of the solutions. Samples were obtained and evaluated using culture technique at each treatment step. In both groups, the numbers of bacteria were decreased after instrumentation and irrigation of the canals. However, after 24 hours of medication, it was reported that the numbers of bacteria were further decreased in the CHX group, in contrast to the saline group, where an increase was noted.⁷⁸ CHX may also have an effect on reduction of inflammatory external root resorption caused by infection. Lindskog et al.²²⁸ assessed the therapeutic effect of a 4-week intracanal application of CHX gel on inflammatory root resorption in replanted infected teeth of monkeys. They reported that the extent of inflammatory resorption was significantly reduced compared to nonmedicated teeth, suggesting that CHX may be a useful adjunct in the management of inflammatory root resorption.

These in vitro and animal studies suggest that CHX has the potential to replace $\text{Ca}(\text{OH})_2$ as an intracanal medicament, but the limitations of the in vitro experiments make the conclusions obtained difficult to extrapolate to actual clinical situations. In vivo human experiments are therefore required to test the efficacy of CHX as an intracanal medication.

Compared to the number of in vitro studies, very few in vivo studies have been conducted to assess the effectiveness of CHX as an intracanal medication. An in vivo investigation²⁰ assessed the antibacterial efficacy of three different intracanal

medications: camphorated paramonochlorophenol, $\text{Ca}(\text{OH})_2$, and 0.12% CHX liquid by applying them for 1 week in single-rooted teeth of patients. Using a culture method, it was reported that the proportions of positive cultures were not significantly different among the tested medications, but they were slightly lower in teeth medicated with CHX (0.12%) liquid than those medicated with camphorated paramonochlorophenol or $\text{Ca}(\text{OH})_2$.²⁰

Another in vivo study evaluated the antibacterial effectiveness of 2% CHX liquid as an intracanal medication in teeth with apical periodontitis.²⁹³ The results showed a moderate increase in bacterial counts during a medication period of 7 to 14 days that was similar to outcomes seen and reported for $\text{Ca}(\text{OH})_2$ by Peters et al.³⁰¹ It was speculated that the CHX liquid may have partially escaped from the apical foramen, and that the higher-viscosity gel form might have been better suited as an intracanal medication.²⁹³

However, a different study²³⁹ demonstrated that intracanal medication with $\text{Ca}(\text{OH})_2$, 2% CHX gel, or a mixture of $\text{Ca}(\text{OH})_2$ /CHX applied for 7 days did not reduce the bacterial concentration beyond what was achieved after chemomechanical preparation using 1% NaOCl. The results were not significantly different among the medication groups. Similar results were found by other investigators,²³⁸ where after a randomized controlled trial of 30 patients, they concluded that a final rinse with MTAD (mixture of tetracycline, acid, and detergent) and intracanal application of 2% CHX gel did not reduce bacterial counts beyond levels achieved by chemomechanical preparation using NaOCl.

Chlorhexidine and Calcium Hydroxide

During the last few years, researchers have studied the combination of $\text{Ca}(\text{OH})_2$ and CHX, with the concept that their antimicrobial properties interact in a synergistic fashion that enhances their efficacy. The high pH of $\text{Ca}(\text{OH})_2$ was unaffected when combined with CHX.²⁶ However, the results have not been conclusive. Some in vitro studies have reported an improved antibacterial action when both agents were combined,^{28,102,438} while other studies reported conflicting results.¹⁵⁷

Recent animal studies have evaluated the tissue reactions to the mix of $\text{Ca}(\text{OH})_2$ /CHX, showing that the combination exerts good antimicrobial properties³⁶⁴ and improves healing of the periapical tissues. In vivo studies have shown that the mix is at least as good as both agents applied separately in necrotic teeth with apical periodontitis,²³⁹ as well as in previously treated cases with persistent apical periodontitis. A more recent study utilizing a CHX-based protocol of 0.12% CHX as an irrigant followed by a 7-day intracanal medication of $\text{Ca}(\text{OH})_2$ /0.12% CHX has shown promising results. The authors concluded that chemomechanical canal shaping using 0.12% CHX solution as an irrigant significantly reduced the number of intracanal bacteria, but it failed to render the canals bacteria free. Further intracanal medication with a $\text{Ca}(\text{OH})_2$ /CHX paste significantly improved the results by reducing the number of bacteria.³⁵³ Taken together, it seems that the usefulness of mixing $\text{Ca}(\text{OH})_2$ with CHX remains unclear and controversial.

Chlorhexidine and Coronal Penetration of Bacteria

Because of its antimicrobial substantivity, it seems that CHX preparations delay entry of bacteria through the coronal

*References 20, 70, 83, 98, 228, 239, 293, and 441.

portion of the tooth into the root canal system. A laboratory study¹³⁸ investigated the time required for recontamination of the root canal system of teeth with coronal restorations medicated with $\text{Ca}(\text{OH})_2$, 2% CHX gel, or a combination of both. The canals without a coronal restoration but medicated with CHX showed recontamination after an average time of 3.7 days, the group with $\text{Ca}(\text{OH})_2$ after 1.8 days, and the group with CHX + $\text{Ca}(\text{OH})_2$ after 2.6 days. The canals medicated with CHX and restored with intermediate restorative material (IRM) showed recontamination within 13.5 days, the group with $\text{Ca}(\text{OH})_2$ + IRM after 17.2 days, and the group with CHX + $\text{Ca}(\text{OH})_2$ + IRM after 11.9 days. The group with no medication but restored with IRM showed recontamination after an average time of 8.7 days. There were statistically significant differences between the groups ($P < 0.05$). All groups without a coronal restoration were recontaminated significantly more quickly than those restored with IRM, except those teeth that had a restoration but no medicament. The groups with intracanal medication and a coronal restoration were not significantly different from each other.

An ex vivo study⁴⁰⁸ assessed coronal dye penetration of extracted human teeth after root canal treatment using 1% NaOCl, 1% NaOCl + 17% ethylenediamine tetra-acetic acid (EDTA), 2% CHX gel, 2% CHX gel + 1% NaOCl and distilled water. Results revealed that the least dye penetration occurred with 1% NaOCl + 17% EDTA and 2% CHX gel. NaOCl, distilled water, and 2% CHX gel + 1% NaOCl had more dye penetration with a significant difference compared with NaOCl + 17% EDTA and 2% CHX gel and compared with one another.

Lambrianidis and colleagues²¹⁰ have shown that viscous irrigants, including those containing CHX gluconate, were less soluble substances that can leave residue on root canal surfaces and potentially affect root canal obturation. The efficiency of removing $\text{Ca}(\text{OH})_2/\text{CHX}$ gel, $\text{Ca}(\text{OH})_2/\text{CHX}$ solution and $\text{Ca}(\text{OH})_2/\text{saline}$ pastes with the use of instrumentation and irrigation with NaOCl and EDTA solutions has been assessed. None of the techniques used in this study removed the interappointment root canal medicaments effectively. Overall, $\text{Ca}(\text{OH})_2/\text{CHX}$ (gel) paste was associated with significantly larger amount of residue, whereas the $\text{Ca}(\text{OH})_2/\text{CHX}$ mixture was associated with less residue than the other two medicaments. Overall, because of its substantivity, CHX as an intracanal medicament/irrigant may delay the coronal recontamination of the root canal system.

Interaction between CHX, NaOCl, and EDTA

A suggested clinical protocol⁴³⁹ for treating dentin prior to root canal obturation consists of irrigation with NaOCl to dissolve the organic components, irrigation with EDTA to eliminate the smear layer, and irrigation with CHX to increase the antimicrobial spectrum of activity and impart substantivity. Although such a combination of irrigants may enhance the overall antimicrobial effectiveness,²⁰⁸ possible chemical interactions between the irrigants must be considered. Some studies have reported the occurrence of color change and precipitation when NaOCl and CHX are combined^{26,439} (Fig. 8-48). Furthermore, concerns have been raised that the color change may have some clinical relevance because of staining, and the resulting precipitate might interfere with the seal of the root obturation. The formation of a precipitate could be explained by the acid-base reaction that occurs when NaOCl and CHX




FIG. 8-48 Color change and precipitation occur when NaOCl and CHX are combined.

are mixed together. CHX, a dicationic acid, has the ability to donate protons. NaOCl is alkaline and can accept protons from the dicationic acid. This proton exchange results in the formation of a neutral and insoluble substance referred to as the precipitate.²⁶ Basrani et al.²⁶ evaluated the chemical nature of this precipitate and reported that there was an immediate reaction when 2% CHX was combined with NaOCl, even at the low concentration (0.023%). They found that the amount of PCA directly increased with the increasing concentration of NaOCl. PCA has been shown to be toxic in humans with short-term exposure, resulting in cyanosis, which is a manifestation of methemoglobin formation. In another study, the effect on root dentin and dentinal tubules was evaluated subsequent to irrigating root canals with a combination of NaOCl and CHX. They concluded that the NaOCl/CHX precipitate tends to occlude the dentinal tubules and suggested that until this precipitate is studied further, caution should be exercised when irrigating with both NaOCl and CHX. In summary, the combination of NaOCl and CHX causes color changes and formation of a neutral and possibly toxic insoluble precipitate that may interfere with the seal of the root obturation. Alternatively, the canal can be dried using paper points before the final CHX rinse.⁴³⁹

The combination of CHX and EDTA produces a white precipitate, so a group of investigators³¹¹ did a study to determine whether the precipitate involves the chemical degradation of CHX. The precipitate was produced and redissolved in a known amount of dilute trifluoroacetic acid. Based on the results, CHX was found to form a salt with EDTA rather than undergoing a chemical reaction.

Dentin Bonding of Chlorhexidine

During the last 2 decades, chemical and technical advances have contributed to increases in resin-dentin bond strength. However, the premature loss of bond strength is one of the problems that still affects adhesive restorations²⁷⁰ and markedly reduces their durability.^{54,80,117} Researchers⁵³ evaluated the effect of CHX on resin-dentin bond stability ex vivo. They concluded that autodegradation of collagen matrices can occur in resin-infiltrated dentin, but this may be prevented by the application of a synthetic protease inhibitor such as CHX.³³ Because of its broad-spectrum matrix metalloproteinase (MMP)-inhibitory effect, CHX may significantly improve resin-dentin bond stability.

Allergic Reactions to Chlorhexidine

CHX, although reported to be a relatively safe solution, may induce allergic reactions. The sensitization rate has been reported in several studies to be approximately 2%.²⁰² One case of an anaphylactic shock was reported after the application of 0.6% CHX to intact skin that had signs of a rash following a minor accident.¹⁵ Further allergic reactions such as anaphy-

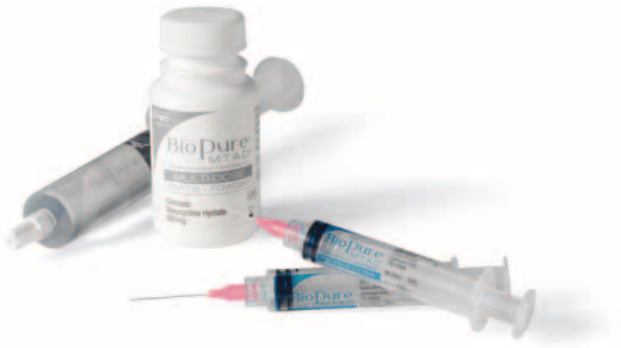

FIG. 8-49 BioPure MTAD. (Courtesy Dentsply Tulsa Dental, Tulsa, OK).

laxis, contact dermatitis, and urticaria have been reported following direct contact to mucosal tissue or open wounds.^{92,303,340,363} There are no publications reporting allergic reactions following root canal irrigation with CHX.¹⁸¹

MTAD and Tetraclean

Recently, MTAD (Fig. 8-49) and Tetraclean, two new irrigants based on a mixture of antibiotics, citric acid, and a detergent, have been developed. MTAD is the first irrigating solution created which is capable of removing the both the smear layer and disinfecting the root canal system.³⁹² It is a mixture of 3% doxycycline hyclate, 4.25% citric acid, and 0.5% polysorbate-80 (Tween 80) detergent.³⁹² Commercially available as BioPure MTAD (Dentsply Tulsa Dental, Tulsa, OK), it is mixed as a liquid and powder prior to use. MTAD has been recommended in clinical practice as a final rinse after completion of conventional chemomechanical preparation.*

Tetraclean (Ogna Laboratori Farmaceutici, Muggio, Italy) is another combination product similar to MTAD. The two irrigants differ in the concentration of antibiotics (doxycycline 150 mg/5 ml for MTAD and 50 mg/5 ml for Tetraclean) and the kind of detergent (Tween 80 for MTAD, polypropylene glycol for Tetraclean).

Mode of Action

There is no detailed information on the exact mechanism of action of MTAD in the removal of the smear layer and the killing of bacteria. In most studies, its effect on the smear layer is attributed to the existence of doxycycline and citric acid. These two components in solution have been separately reported as being effective in the removal of the smear layer.¹⁶³ Its antibacterial effect is mostly attributed to the doxycycline, an isomer of tetracycline. Tetracyclines—including tetracycline HCl, minocycline, and doxycycline—are broad-spectrum antibiotics that are effective against a wide range of microorganisms. Tetracycline is a bacteriostatic antibiotic which exerts its effect through the inhibition of protein synthesis. According to Torabinejad et al.,³⁹³ this property may be advantageous because in the absence of bacterial cell lysis, antigenic byproducts (i.e., endotoxin) are not released. In high concentrations, tetracycline may also have a bactericidal effect. The role of citric acid in killing bacteria is not well known. Tween 80, the other component of MTAD, seems to have limited antibacterial

*References 29, 31, 346, 347, 392, and 393.

activity, yet it may increase the antibacterial effect of some substances by directly affecting the bacterial cell membrane. It may also facilitate the penetration of MTAD into dentin. On the contrary, Tween 80 may also be a nutrient for some bacteria, and it may inactivate the antibacterial properties of some disinfecting agents such as CHX and povidone iodine. Doxycycline, citric acid, and Tween 80 together may have a synergistic effect on the disruption of the bacterial cell wall and on the cytoplasmic membrane.

Surface Tension

According to Grossman,¹⁵⁰ low surface tension is one of the ideal characteristics of an irrigant. Lower surface tension may help by allowing the irrigant to penetrate better into the dentinal tubules and inaccessible areas of the root canal system.³⁸⁸

To be more effective in debris removal and to penetrate more readily into the root canal system, irrigants must be in contact with the dentin walls. The closeness of this contact is directly related to its surface tension.¹³³ Irrigants with a low surface tension are more suitable as endodontic irrigants. To decrease the surface tension, Tween 80 has been added to the MTAD solution.

Smear Layer Removal

In two studies, the efficacy of MTAD or EDTA in the removal of the smear layer was confirmed, but no significant difference between these two solutions was reported.^{389,390}

Antibacterial Efficacy

Reported results regarding the antibacterial properties of MTAD are conflicting. The studies measuring zones of inhibition on agar plates have shown consistently that MTAD was an effective antibacterial agent against *E. faecalis*.^{73,201,393} Tay et al.^{389,390} also found larger zones of bacterial inhibition using dentin cores irrigated with MTAD compared to NaOCl-irrigated dentin cores. When they applied MTAD to dentin that was already irrigated with 1.3% NaOCl, however, they noticed a contradictory result: the diameters of the zones of inhibition were significantly smaller than those of MTAD alone but comparable to those irrigated with 1.3% NaOCl alone. They concluded that the antimicrobial effect of MTAD was lost due to oxidation of the MTAD by NaOCl.

A study using extracted human teeth contaminated with saliva showed that MTAD was more effective than 5.25% NaOCl in disinfection of the teeth.³⁴⁷ In contrast, Krause et al.,²⁰¹ using bovine tooth sections, showed that 5.25% NaOCl was more effective than MTAD in disinfection of dentin discs inoculated with *E. faecalis*.

In another study performed on extracted human teeth inoculated with *E. faecalis*, a protocol of 1.3% NaOCl followed by 5 minutes of MTAD was more effective in the disinfection of canals than a protocol of 5.25% NaOCl followed by 1 minute of 17% EDTA and then 5 minutes of 5.25% NaOCl as a final rinse.³⁴⁷ In a series of studies, MTAD has failed to show superior antibacterial efficacy against bacterial biofilms. Bacteria collected from the teeth of patients diagnosed with apical periodontitis were grown as a biofilm on hemisections of root apices. MTAD was an effective antibacterial agent in this model, but it was unable to completely disrupt the bacterial biofilm, compared to 6% NaOCl. NaOCl (5.25%) was the most effective irrigant against a biofilm of *E. faecalis* generated on

cellulose nitrate membrane filters, whereas the bacterial load reduction using MTAD was not significant.¹³⁴ The results of testing antibacterial efficacy of medicaments obtained from in vitro studies should be analyzed with caution. They may be influenced by factors such as the test environment, bacterial susceptibility, and the different methodologies used to evaluate the results.³⁵⁴

In vivo Clinical Trial

With the exception of one study³⁹⁴ that evaluated the effect of MTAD on postoperative discomfort, there have been no other in vivo studies to address the other characteristics of MTAD. Malkhassain et al.²³⁸ in a clinical controlled trial of 30 patients reported that the final rinse with MTAD did not reduce the bacterial counts in infected canals beyond levels achieved by chemomechanical preparation using NaOCl alone.

Protocol for Use

The clinical protocol for the use of MTAD was developed on the basis of a pilot project.³⁴⁶ The results of this project showed consistent disinfection of the infected root canals could occur after chemomechanical preparation using 1.3% NaOCl as a root canal irrigant followed by a 5-minute rinse of MTAD.

Ethylenediamine Tetra-acetic Acid

EDTA is often suggested as an irrigation solution because it can chelate and remove the mineralized portion of the smear layer (Fig. 8-50). It is a polyaminocarboxylic acid with the formula $[\text{CH}_2\text{N}(\text{CH}_2\text{CO}_2\text{H})_2]_2$. This colorless, water-soluble solid is produced on a large scale for many applications. Its prominence as a chelating agent arises from its ability to sequester di- and trivalent metal ions such as Ca^{2+} and Fe^{3+} . After being bound by EDTA, metal ions remain in solution but exhibit diminished reactivity.

History

The compound was first described in 1935 by Ferdinand Munz, who prepared the compound from ethylenediamine and chloroacetic acid. Today, EDTA is mainly synthesized from

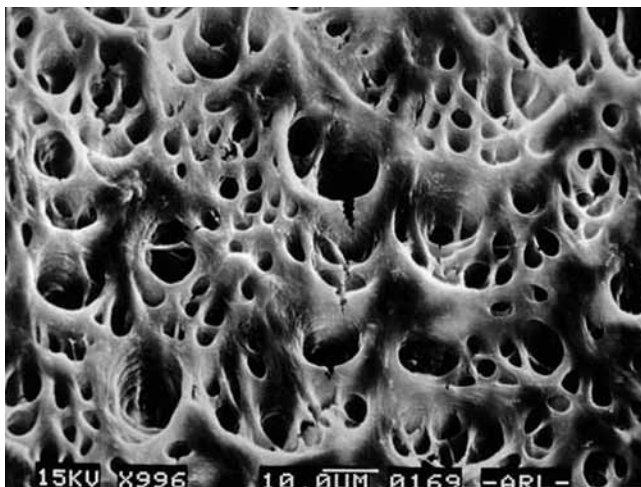


FIG. 8-50 Scanning electron microscope (SEM) image of root canal dentin exposed to 2 minutes of EDTA.

ethylenediamine (1, 2-diaminoethane), formaldehyde (methanal), and sodium cyanide.

Mode of Action

On direct exposure for extended time, EDTA extracts bacterial surface proteins by combining with metal ions from the cell envelope, which can eventually lead to bacterial death.

Applications in Endodontics

EDTA alone normally cannot remove the smear layer effectively; a proteolytic component (e.g., NaOCl) must be added to remove the organic components of the smear layer.¹³⁶ Commercial products with such combinations are available. Endo-Dilator N-Ø (Union Broach, York, PA) is a combination of EDTA and a quaternary ammonium compound. Such an irrigation fluid has a slight detergent effect in addition to the chelating effect. Two newer irrigating solutions, MTAD (discussed earlier) and Smear Clear (SybronEndo), have recently been studied. Smear Clear is a clear, odorless, water-soluble solution containing water, 17% EDTA salts, a cationic surfactant (cetrimide), and anionic surfactants.

EDTA is normally used in a concentration of 17% and can remove the smear layers when in direct contact with the root canal wall for less than 1 minute. The decalcifying process is self-limiting. For root canal preparation, EDTA has limited value alone as an irrigation fluid. Since it is capable of decalcifying up to 50 μm , it can open up an occluded, very fine canal. This depth, added from two opposite canal walls, will result in a 100- μm opening, equivalent to the tip of a #010 file.

Although citric acid appears to be slightly more potent at similar concentration than EDTA, both agents show high efficiency in removing the smear layer. In addition to their cleaning ability, chelators may detach biofilms adhering to root canal walls.¹⁵¹ This may explain why an EDTA irrigant proved to be highly superior to saline in reducing intracanal microbiota despite the fact that its antiseptic capacity is relatively limited.¹⁵¹ Although never shown in a randomized clinical trial, an alternating irrigating regimen of NaOCl and EDTA may be more efficient in reducing bacterial loads in root canal systems than NaOCl alone. Antiseptics such as quaternary ammonium compounds (EDTAC) or tetracycline antibiotics (MTAD) have been added to EDTA and citric acid irrigants, respectively, to increase their antimicrobial capacity. The clinical value of this, however, is questionable. EDTAC shows similar smear-removing efficacy as EDTA, but it is more caustic.

Interaction of EDTA and NaOCl

Investigators¹⁴⁶ studied the interactions of EDTA with NaOCl. They concluded that EDTA retained its calcium-complexing ability when mixed with NaOCl, but EDTA caused NaOCl to lose its tissue-dissolving capacity, with virtually no free chlorine detected in the combinations. Clinically, this suggests that EDTA and NaOCl should be used separately. In an alternating irrigating regimen, copious amounts of NaOCl should be administered to wash out remnants of the EDTA.

Hydrogen Peroxide

Hydrogen peroxide (H_2O_2) has been used as an endodontic irrigant for years, mainly in concentrations ranging between 3% and 5%. It is active against bacteria, viruses, and yeasts.

Hydroxy free radicals ($\cdot\text{OH}$) destroy proteins and DNA. The tissue-dissolving capacity of H_2O_2 is clearly lower than that of NaOCl .³³⁰ When used in combination with NaOCl , bubbling will occur as a result of nascent oxygen being released through the chemical reaction between these two liquids. Generally this is no longer recommended as a routine irrigant.

Iodine Potassium Iodide

IKI, used as a solution of 2% iodine in 4% potassium iodide, has been proposed and is used as an endodontic disinfectant because of its excellent antibacterial properties and low cytotoxicity. However, it may act as a severe allergen³⁰⁶ and also stains dentin.³³⁰

Choosing the Ideal Irrigant

Although iodine is less cytotoxic and irritating to vital tissues than NaOCl and CHX,^{370,371} it has a higher risk of causing an allergic reaction.³⁰⁶ The same is true for quaternary ammonium compounds. Sensitivities to hypochlorite and CHX are rare.⁴³⁹

Of all the currently used substances, NaOCl appears to be the most ideal because it covers more of the requirements for endodontic irrigant than any other known compound. Hypochlorite has the unique capacity to dissolve necrotic tissue and the organic components of the smear layer. It kills sessile endodontic pathogens organized in biofilms and in dentinal tubules as efficiently as CHX or iodine at comparable concentration.^{290,373,401} Inactivation of endotoxin by hypochlorite has been reported, but the effect is minor compared to that of a $\text{Ca}(\text{OH})_2$ dressing.

Intracanal Medication

When treatment cannot be completed in one appointment [see Chapters 4 and 15], the surviving intracanal bacteria often proliferate between appointments.^{47,415} To curtail bacterial regrowth and possibly even improve bacterial suppression, an intracanal medication can be advantageous. Interappointment antimicrobial medication acts to inhibit proliferation and further eliminate surviving bacteria, as well as minimize ingress through a leaking restoration.

Phenolic Preparations

Phenol ($\text{C}_6\text{H}_5\text{OH}$), or carbolic acid, is one of the oldest antimicrobial agents used in medicine. Despite the severe toxicity of phenolic preparations, derivatives of phenol, such as paramonochlorophenol ($\text{C}_6\text{H}_4\text{OHCl}$), thymol ($\text{C}_6\text{H}_3\text{OHCH}_3\text{C}_3\text{H}_7$), and cresol ($\text{C}_6\text{H}_4\text{OHCH}_3$), remain available. One survey noted a decrease in the use of classic phenolic intracanal medications with a corresponding increase in the use of $\text{Ca}(\text{OH})_2$ or no medication.¹²⁸

Phenol is a nonspecific protoplasm poison that has an optimal antibacterial effect at 1% to 2%. Many dental preparations use much too high a concentration of phenol (e.g., in the range of 30%). At such a concentration, the antimicrobial effect *in vivo* is lower than optimal and of very short duration.²⁵⁴

Derivatives of phenol are stronger antiseptics and toxins than phenol. Phenolic compounds are often available as camphorated solutions. Camphoration results in a less toxic phenolic compound because it slows the release of toxins to the surrounding tissues.

Studies *in vitro* have shown that phenol and phenol derivatives are highly toxic to mammalian cells, and their anti-

microbial effectiveness does not sufficiently balance their toxicity.^{370,371}

Phenols are ineffective antiseptics under clinical conditions.^{46,96}

Formaldehyde

Formaldehyde, used as formocresol, has been used extensively in endodontic therapy despite its high toxicity and mutagenic and carcinogenic potential.²²¹ The formaldehyde component of formocresol may vary substantially between 19% and 37%. Tricresol formalin, another formaldehyde preparation, contains 10% tricresol and 90% formaldehyde. All of these preparations have a formaldehyde content well above the 10% normally used for fixation of pathological specimens. Formaldehyde is volatile and releases antimicrobial vapors when applied to a cotton pellet for pulp chamber disinfection. All formaldehyde preparations are potent toxins with an antimicrobial effectiveness much lower than their toxicity.^{371,372}

There is no clinical reason to use formocresol as an antimicrobial agent for endodontic treatment, based on what is known at this time. The alternatives are better antiseptics with significantly lower toxicity.

Halogens

Chlorinated solutions have been used for many years to irrigate root canals. They are also used as an intracanal dressing in the form of chloramine-T, an *N*-chloro tosylamide sodium salt. Iodine, in the form of IKI, is a very effective antiseptic solution with low tissue toxicity. IKI is an effective disinfectant for infected dentin and can kill bacteria in infected dentin in 5 minutes *in vitro*.³²⁴ IKI releases vapors with a strong antimicrobial effect. The solution can be prepared by mixing 2 g of iodine in 4 g of potassium iodide; this mixture then is dissolved in 94 ml of distilled water. Tincture of iodine (5%) has proved to be one of the few reliable agents for disinfection of rubber dam and tooth surfaces during the preparation of an aseptic endodontic workfield.²⁷²

Calcium Hydroxide

Hermann introduced^{166,167} the use of $\text{Ca}(\text{OH})_2$ in endodontics in 1920. Although its use was well documented for its time, the clinical applications over the next 25 years were not well known. Its use in root canal treatment as an intracanal medication has been associated with periradicular healing and few adverse reactions. Its use in root canal treatment was promoted by a series of papers^{46,48} documenting the antibacterial efficacy of $\text{Ca}(\text{OH})_2$ in human root canals. Subsequent studies substantiated these reports,^{290,360} and the routine use of $\text{Ca}(\text{OH})_2$ as an interappointment intracanal medicament became widespread.³²⁷

$\text{Ca}(\text{OH})_2$ cannot be categorized as a conventional antiseptic, but it kills bacteria in the root canal space. The value of $\text{Ca}(\text{OH})_2$ in endodontic treatment of necrotic, infected teeth is now well documented. $\text{Ca}(\text{OH})_2$ normally is used as slurry of $\text{Ca}(\text{OH})_2$ in a water base. At body temperature, less than 0.2% of the $\text{Ca}(\text{OH})_2$ is dissolved into Ca^{++} and OH^- ions. Because $\text{Ca}(\text{OH})_2$ needs water to dissolve, water should be used as the vehicle for the $\text{Ca}(\text{OH})_2$ paste. In contact with air, $\text{Ca}(\text{OH})_2$ forms calcium carbonate (CaCO_3). However, this is an extremely slow process and of little clinical significance. $\text{Ca}(\text{OH})_2$ paste, with a significant amount of calcium carbon-

ate, feels granular because the carbonate has a very low solubility.

Ca(OH)₂ is a slow-acting antiseptic. Direct-contact experiments in vitro show that a 24-hour contact period is required for complete killing of enterococci.^{324,360} Another study of 42 patients found that NaOCl canal irrigation reduced the bacteria level by only 61.9%, but use of Ca(OH)₂ in the canals for 1 week resulted in a 92.5% reduction.³⁵⁰ These researchers concluded that Ca(OH)₂ should be used in infected cases to more predictably obtain disinfection.

In addition to killing bacteria, Ca(OH)₂ has the extraordinary ability to hydrolyze the lipid moiety of bacterial lipopolysaccharides (LPS), thereby inactivating the biologic activity of the lipopolysaccharide and reducing its effect.^{322,323} This is a very desirable effect because dead cell wall material remains after the bacteria have been killed and can continue to stimulate inflammatory responses in the periradicular tissue.

Ca(OH)₂ may be mixed with sterile water or saline; this formula is also available commercially from a number of manufacturers in sterile, single-dose packages (e.g., Calasept [J.S. Dental, Ridgefield, CT]; Calcijet [Centrix, Shelton, CT]; and DT Temporary Dressing, [Global Dental Products, North Bellmore, NY]) (Fig. 8-51). The mixture should be thick to carry as many Ca(OH)₂ particles as possible. This slurry is best applied with a Lentulo spiral. For maximum effectiveness, the root canal must be filled homogeneously to the working length. Saturated Ca(OH)₂ solution mixed with a detergent is an effective antimicrobial agent suitable for irrigation.

Limitations of Calcium Hydroxide

There are some concerns regarding the use of Ca(OH)₂. The handling and proper placement of Ca(OH)₂ present a challenge to the average clinician.^{233,358} Also, the removal of Ca(OH)₂ is frequently incomplete, resulting in a residue covering 20% to 45% of the canal wall surfaces, even after copious irrigation with saline, NaOCl, or EDTA.²¹¹ Residual Ca(OH)₂ can shorten the setting time of zinc oxide eugenol-based endodontic sealers.²⁴³ Most notably, it may interfere with the seal of the root filling and compromise the quality of treatment. An additional concern is that Ca(OH)₂ is not totally effective against

several endodontic pathogens, including *E. faecalis* and *Candida albicans*.⁴¹⁶ Recently the ability of Ca(OH)₂ to completely eradicate bacteria from the root canal has been questioned. For example, in vitro studies have shown that dentin can inactivate the antibacterial activity of Ca(OH)₂,^{155,307} and one clinical study³⁰¹ has shown that the number of bacteria-positive canals actually increased after Ca(OH)₂ medication. Other studies have also indicated that Ca(OH)₂ could not predictably eliminate bacteria or that cultures changed from negative to positive after Ca(OH)₂ placement.^{301,415}

When different studies report inconsistent results, a systematic review and meta-analysis technique can clarify conflicting research data and the current state of knowledge regarding specific issues. Therefore, based on the current best available evidence, Ca(OH)₂ has limited effectiveness in eliminating bacteria from human root canals when assessed by culture techniques. The quest for better antibacterial protocols and sampling techniques must continue to ensure that bacteria can be reliably eradicated prior to obturation.

Chlorhexidine

CHX is also used as an intracanal medication and has already been discussed extensively under its own heading.

Ledermix

Ledermix (Lederle Pharmaceuticals, Wolfratshausen, Germany) is a corticosteroid-antibiotic paste. Medicaments such as Ledermix paste have been recommended as routine intracanal medicaments. Ledermix paste is an ideal medication to be used as an initial dressing, particularly if the patient presents with endodontic symptoms.

Schroeder developed the material that is now commercially marketed as Ledermix paste.³³⁹ Ledermix paste contains triamcinolone acetonide as an antiinflammatory agent, at a concentration of 1%. When the Ledermix materials and other similar corticosteroid-containing formulations were commercially released, there was a considerable amount of opposition to their use.¹⁹⁵

Ledermix paste is a nonsetting, water-soluble paste material for use as root canal medicament or as a direct or indirect



FIG. 8-51 Calcijet is a calcium hydroxide prefilled, easy-to-use, single-dose syringe system. Centrix NeedleTube cartridges can be used for direct syringe injection into the root canal. (Courtesy Centrix, Shelton, CT.)

pulp capping agent. The release and dentin diffusion characteristics of triamcinolone from Ledermix paste when used as a root canal medicament have been investigated under different conditions.¹⁻³ These studies show that triamcinolone is released from Ledermix paste in the root canal and can reach the systemic circulation via diffusion through dentinal tubules, lateral canals, and the apical foramen. After the first 24 hours, 30% of the triamcinolone was released. By the end of 14 weeks, the remaining 70% had been released.

Immediate intracanal placement of Ledermix has been studied for replanted teeth, because it has been shown to inhibit root resorption after extended dry time. In a recent study done in dogs, the groups treated with Ledermix, triamcinolone and demeclocycline had significantly more favorable healing and more remaining root structure than the group filled with gutta-percha and sealer (positive control).⁵⁷

The Triple-Antibiotics Paste

The triple-antibiotics regimen, composed of metronidazole, ciprofloxacin, and minocycline, was first tested³²⁸ for its effectiveness against *Escherichia coli*-infected dentin *in vitro*. The same research group also tested its bactericidal efficacy against microbes from carious dentin and infected pulp. They found that the mixture of antibiotics is sufficiently potent to eradicate the bacteria.³⁹¹ The clinical effectiveness of the triple-antibiotic paste in the disinfection of immature teeth with apical periodontitis has been reported.⁴²⁵ One potential concern of using an intracanal antibiotic paste is that it may cause bacterial resistance. Additionally, intracanal use of minocycline can cause tooth discoloration, creating potential cosmetic complications.

Bioactive Glass

Research is underway in the use of bioactive glass as an intracanal medicament. In one study,⁴⁴⁰ the glass used was composed of 53% SiO₂ (w/w), 23% Na₂O, 20% CaO, and 4% P₂O₅ and was prepared from reagent-grade Na₂CO₃, CaHPO₄, 2H₂O, CaCO₃, and Belgian sand. When used in root canals, bioactive glass was found to kill bacteria, but the mechanism of action was not pH related, and dentin did not seem to alter its effect. Some new obturating materials (e.g., Resilon [Pentron Clinical Technologies, Wallingford, CT]) contain bioactive glass.

New Irrigation and Disinfection Techniques and Devices

Other than conventional irrigation, additional techniques for endodontic disinfection have been proposed and tested, including laser systems and gaseous ozone. Recently several new devices for endodontic irrigation and/or disinfection have been

introduced, among which are the EndoActivator System (Dentsply Tulsa Dental Specialties), passive ultrasonic irrigation, EndoVac (Discus, Culver City, CA), the Safety-Irrigator (Vista Dental Products, Racine, WI), the self-adjusting file (ReDent, Raanana, Israel), photoactivation disinfection, and ozone. These new devices use pressure, vacuum, oscillation, and/or a combination with suction. For most of these devices and techniques, no data exists on the clinical efficacy, risk, frequency, and intensity of apical irrigant extrusion or the problems encountered with the use of negative pressure or oscillation.

EndoActivator

The EndoActivator System uses safe, noncutting polymer tips in an easy-to-use subsonic handpiece to quickly and vigorously agitate irrigant solutions during endodontic therapy (Fig. 8-52).

In a recent study,⁸⁴ the safety of various intracanal irrigation systems was analyzed by measuring the apical extrusion of irrigant. They concluded that EndoActivator had a minimal, although statistically insignificant, amount of irrigant extruded out of the apex when delivering the subsonic activation of the irrigant into the pulp chamber and canal. Manual, ultrasonic, and Rinsendo (Dürr Dental, Bietigheim-Bissingen, Germany) groups had significantly greater amount of extrusion compared with EndoVac and EndoActivator.

Passive Ultrasonic Activation

Ultrasonic devices were first introduced in endodontics by Richman.³¹² Ultrasonically activated files have the potential to prepare and débride root canals mechanically. The files are driven to oscillate at ultrasonic frequencies of 25 to 30 kHz. They operate in a transverse vibration, setting up a characteristic pattern of nodes and antinodes along their length.^{413,414} Unfortunately, it proved difficult to control the cutting of dentin during ultrasonic preparation, which resulted in apical perforations and irregular canal shapes.^{235,380}

However, it has been shown that ultrasonically driven files are effective for the irrigation of root canals. Two types of ultrasonic irrigation have been described in the literature^{6,420}: one where irrigation is combined with simultaneous ultrasonic instrumentation (UI) and another without simultaneous instrumentation, called *passive ultrasonic irrigation* (PUI). During UI, the file is intentionally brought into contact with the root canal wall. UI has been shown to be less effective in removing simulated pulp tissue from the root canal system or smear layer from the root canal wall than PUI. This can be explained by a reduction of acoustic streaming and cavitation.⁶ Because the root canal anatomy is complex,³⁰² an instrument



FIG. 8-52 EndoActivator system. (Courtesy Dentsply Tulsa Dental, Tulsa, OK.)

will never contact the entire root canal wall.⁴²⁹ Thus, UI could result in uncontrolled cutting of the root canal wall without effective cleaning.

Passive ultrasonic irrigation was first described by Weller et al.⁴²⁰ The term *passive* does not adequately describe the process, since it is in fact active. When it was first introduced, the term *passive* related to the noncutting action of the ultrasonically activated file. PUI relies on the transmission of acoustic energy from an oscillating file or smooth wire to an irrigant in the root canal. The energy is transmitted by means of ultrasonic waves and can induce acoustic streaming and cavitation of the irrigant.⁶ After the root canal has been shaped to the master apical file (irrespective of the preparation technique used), a small file or smooth wire (for example, size #15) is introduced in the center of the root canal, as far as the apical region. The root canal is then filled with an irrigant solution, and the ultrasonically oscillating file activates the irrigant. Since the root canal has already been shaped, the file or wire can move freely, and the irrigant can penetrate more easily into the apical part of the root canal system,²⁰⁴ with the cleaning effect being more significant.²³⁵ Using this noncutting methodology, the potential to create aberrant shapes within the root canal are reduced to a minimum. A file larger than a #15 or #20 will only oscillate freely in a wide root canal. A #25 file may in fact produce less acoustic streaming than a #15 and #20 file.⁶ Consequently, using a file larger than a #20 may be considered fundamentally different from the basic principle of PUI. The cleaning efficacy of PUI implies the effective removal of dentin debris, microorganisms (planktonic or in biofilm), and organic tissue from the root canal. Because of the active streaming of the irrigant, its potential to contact a greater surface area of the canal wall will be enhanced.

If ultrasonic activation of the hypochlorite irrigant is to be used, it appears important to apply the ultrasonic instrument after canal preparation has been completed. A freely oscillating instrument will cause more ultrasound effects in the irrigating solution than a counterpart that binds to canal walls.³¹⁸ In addition, ultrasonic files can cause uncontrolled cutting of the canal walls, especially if used during preparation.³⁸⁰ Therefore, it appears best to insert a slim, noncutting instrument in a controlled fashion after canal preparation.^{402,403} As of recently, smooth wires fitting to an ultrasonic device have been commercially available. However, objective guidelines regarding their risks and benefits have not been ascertained.⁴³⁹

EndoVac

EndoVac is a combined irrigation/evacuation system. The irrigant is extruded from the system with pressure at the root canal orifice. The evacuator, a microcannula, extends to the apical region of the root canal; the dimensions of the needle are size #55 with a 2% taper. High-volume suction from the dental unit results in negative apical pressure and thus passively sucks the irrigant from the orifice to the apical part of the root canal, which is passively evacuated from the canal space. Apical extrusion of the irrigant will probably be reduced, since the canal is irrigated with negative (as opposed to positive) pressure.²⁸³ There is no peer-reviewed literature to demonstrate this device is safe and effective when there is an open (immature) apex or in cases where there is a pathologic perforating root resorption.

A similar device has been presented by Fukumoto et al.^{119,120} The irrigant is delivered by a needle (outer diameter 0.41 mm, inner diameter 0.19 mm) and a tubing pump (Masterflex, Cole Palmer Instruments, Vernon Hills, IL) to the coronal or middle part of the root canal and aspirated by a second needle (outer diameter 0.55 mm, inner diameter 0.30 mm), which is introduced into the apical part of the root canal. The aspiration pressure is -20 kPa. The irrigant is flushed from the coronal to the apical part of the root canal and there finally suctioned. This technique in an *in vitro* experiment on teeth with resected apices resulted in significantly less overextrusion of irrigant than a conventional irrigation technique with the needle tip placed 2 mm short of the apex. When the needle was placed 3 mm from the apex, the results did not significantly differ (Figs. 8-53 through 8-56).

Safety-Irrigator

The Safety-Irrigator is an irrigation/evacuation system that apically delivers the irrigant under positive pressure through a thin needle containing a lateral opening, and evacuates the solution through a large needle at the root canal orifice. As of this printing, no information on its safety or efficacy are available (Fig. 8-57). Absent clear evidence of safety and efficacy through peer-reviewed literature, the reader is advised to use caution in choosing an irrigating device.

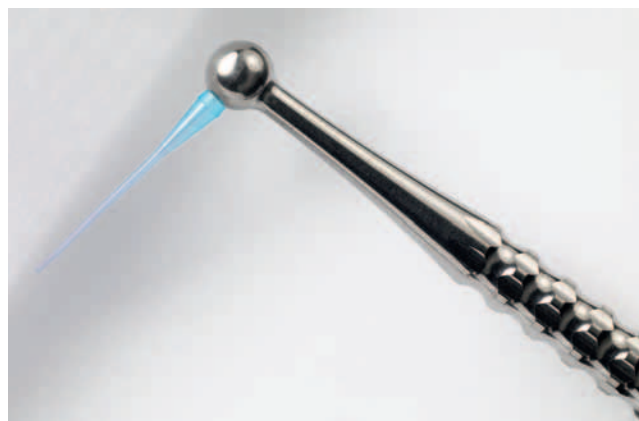

FIG. 8-53 EndoVac system for NaOCl delivery and vacuum evacuation. Open-ended microcannula. (Courtesy Discus, Culver City, CA.)




FIG. 8-54 EndoVac system for NaOCl delivery and vacuum evacuation. Closed-ended microcannula. (Courtesy Discus, Culver City, CA.)




FIG. 8-55 EndoVac system: magnification of the closed-ended micro-cannula. (Courtesy Discus, Culver City, CA.)

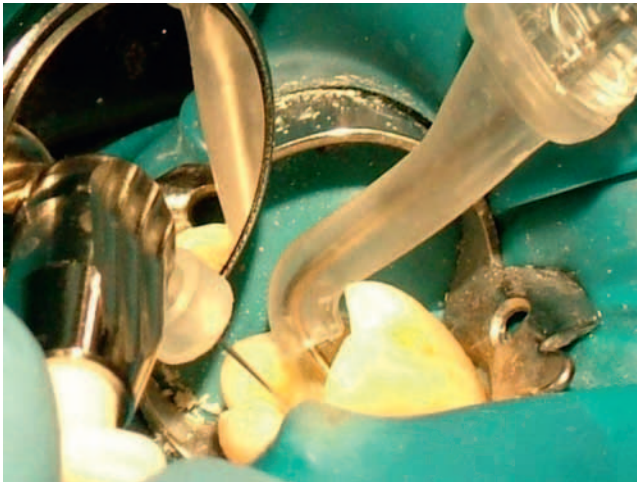

FIG. 8-56 Clinical use of the EndoVac system and Safety-Irrigator.

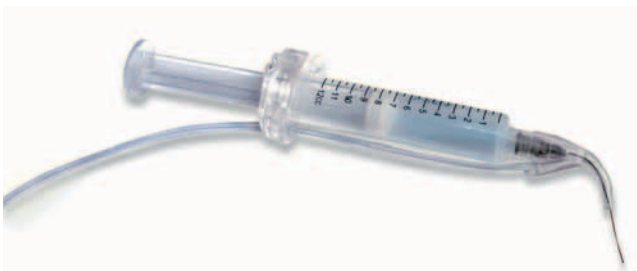

FIG. 8-57 The Safety-Irrigator. (Courtesy Vista Dental Products, Racine, WI.)

Self-Adjusting File

The SAF was recently introduced primarily as an endodontic file (discussed at length earlier under Instruments for Cleaning and Shaping the Root Canal Space). It should also be considered as an irrigation device since the file is hollow, which allows for continuous irrigation. The irrigant is delivered

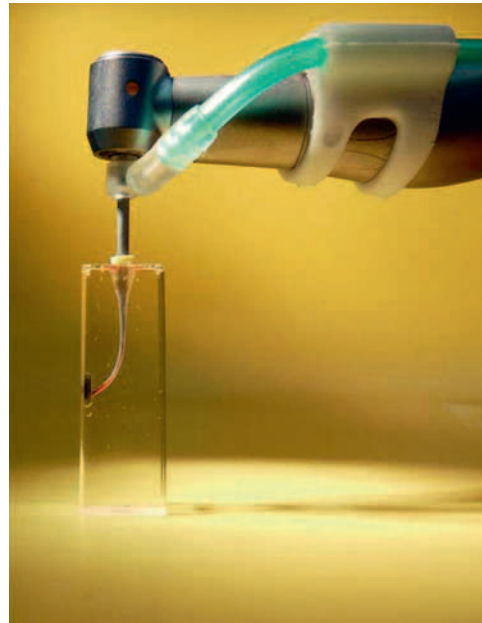

FIG. 8-58 The self-adjusting file (SAF; ReDent-Nova, Raanana, Israel). The hollow endodontic file is used also as a continuous irrigation device throughout the cleaning and shaping of the root canal. (Courtesy ReDent-Nova, Raanana, Israel.)

through a free-rotating hub to which a silicone tube is attached (Fig. 8-58). Either a special irrigation unit (see Fig. 8-30) (VATEA, ReDent, Raanana, Israel) or any physio-dispenser-type unit may be used to deliver a constant flow of irrigant at 5 ml/min. This maintains a continuous flow of fresh, fully active irrigant, facilitating an outflow of tissue debris and dentin powder that is generated by the file use. No positive pressure is thought to be created in the canal during this continuous irrigation procedure. The open metal lattice allows the irrigant to escape freely, minimizing the risk of irrigant transportation beyond the apical foramen.²⁶⁰ The replacement of irrigation fluid in the apical part of curved canals is demonstrated in Fig. 8-59.

HealOzone

Ozone (also known as triatomic oxygen or trioxygen) is a naturally occurring compound consisting of three oxygen atoms. It is found in nature in the form of a gas in the stratosphere at a concentration of 1 to 10 ppm, being continually created from and destroyed into molecular O₂. The reliable microbiologic and metabolic properties of ozone, in either the gaseous or aqueous phases, make it a useful disinfectant with a wide range of activity. Ozone, in the gaseous or aqueous phase, has been shown to be a powerful and reliable antimicrobial agent against bacteria, fungi, protozoa, and viruses. It is generally accepted that the oxidant potential of ozone induces the destruction of cell walls and cytoplasmic membranes of bacteria and fungi. During this process, ozone attacks glycoproteins, glycolipids, and other amino acids and inhibits the enzymatic control system of the cell. This results in increased membrane permeability, the key element of cell viability, leading to immediate functional cessation. The ozone molecules then readily enter the cell and cause the microorgan-

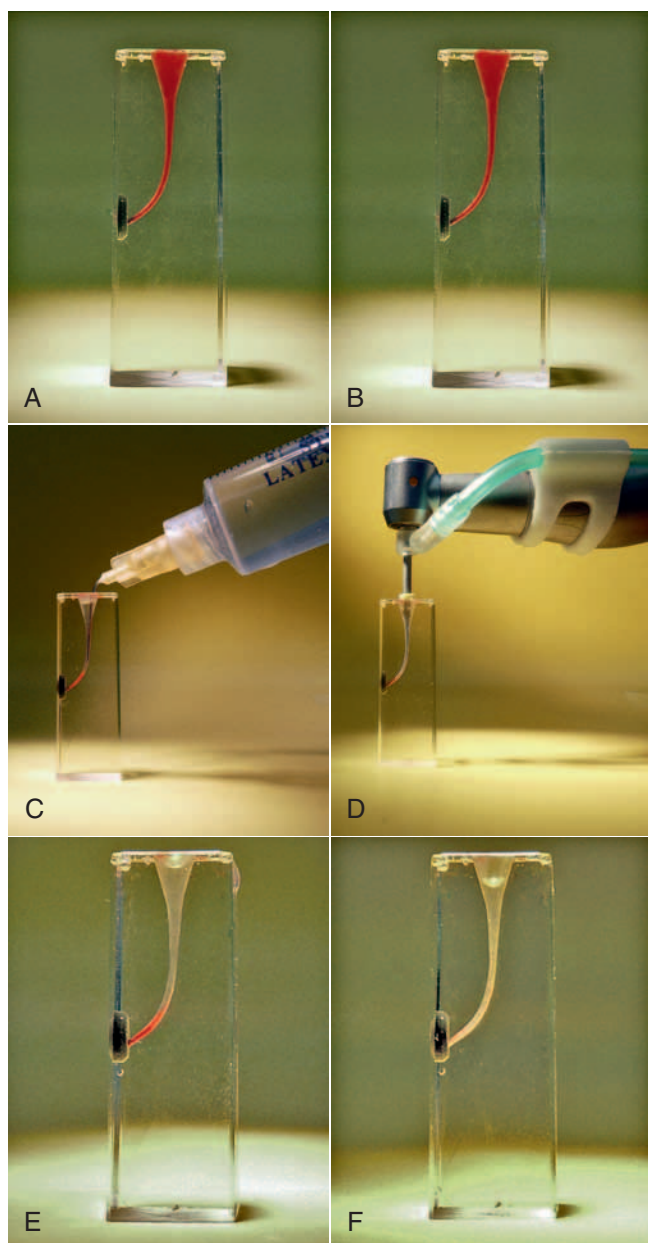


FIG. 8-59 Replacement of irrigation fluid in the apical part of curved canals. Transparent training blocks were filled with colored liquid (A-B), the canal was rinsed with either 20 ml of water using a syringe (C) or using the SAF instrument with a continuous flow of an equal amount of water (D). The short needle was unable to replace the liquid beyond the curve (E), but the SAF irrigation did it effectively (F).²⁶⁰

ism to die. Ozone can also attack many biomolecules, such as the cysteine, methionine, and histidine residues of proteins. By oxidizing the biomolecules featured in dental diseases, ozone has a severely disruptive effect on cariogenic bacteria, resulting in the elimination of acidogenic bacteria. The strongest naturally occurring acid—produced by acidogenic bacteria during cariogenesis—is pyruvic acid. Ozone can decarboxylate this acid to acetic acid. It has been shown that remineralization of incipient carious lesions can be encouraged when the produc-

tion of acetic acid, or other high *pKa* acids found in resting plaque, buffers plaque fluid.²⁴⁵

E.A. Fisch (1899–1966) was the first dentist to use ozonated water in his practice and introduced it to the German surgeon Erwin Payr (1871–1946) who used it from that time forward in surgery. He reported his results at the 59th Congress of the German Surgical Society in Berlin (1935). In dental surgery, ozonated water was used to promote hemostasis, enhance local oxygen supply, and inhibit bacterial proliferation. Theoretically, ozone can reduce the bacterial count in active carious lesions and therefore may temporarily arrest the progression of caries, resulting in preventing or delaying the need for tooth restorations.³¹³ For review on ozone use in dentistry see Azarpazhooh & Limeback¹⁷

Ozone in Endodontics

Four *in vitro* studies^{100,164,279,282} were identified investigating the bactericidal effect of ozone compared to 2.5% NaOCl, the standard irrigation solution in endodontics. The results of these studies^{164,279,282} are controversial. The hazards of ozone when used in endodontics have not been investigated. Care should be taken with regard to the patient's and the dentist's exposure to the gas. Fig. 8-60 shows ozone equipment with a special tip for intracanal application.

Superoxidized Water

Superoxidized water,¹⁵² also called electrochemically activated water^{241,365} or oxidative potential water,^{162,344} is saline that has been electrolyzed to form superoxidized water, hypochlorous acid, and free chlorine radicals. It is available as Sterilox (Sterilox Technologies, Radnor, PA). This solution is nontoxic to biologic tissues yet able to kill microorganisms. The solution is generated by electrolyzing saline solution, a process no different than that used in the commercial production of NaOCl.¹¹⁶ The difference, however, is that the solution accumulating at the anode is harvested as the anolyte and that at the cathode as the catholyte. These solutions display properties that are dependent upon the strength of the initial saline solution, the applied potential difference, and the rate of generation. The technology that allows harvesting of the respective solutions resides in the design of the anode and the cathode and originates either in Russia (electrochemically activated water) or Japan (oxidative potential water).^{240,241} Although the solutions bear different names, the principles in the manufacturing process are probably the same.

The use of superoxidized water is sparse in the endodontic literature but shows early promise. The solutions from both technologies have been tested for their ability to débride root canals,^{162,241} remove smear layer,^{344,365} and kill bacteria¹⁷² and bacterial spores.²³⁴ Results are favorable, while also showing biocompatibility with vital systems.¹⁸³

Anolyte and catholyte solutions generated from one such technology (Radical Waters Halfway House 1685, S. Africa) have shown promise as antibacterial agents against laboratory-grown, single-species biofilm models.¹³² Such solutions have been recommended as suitable for removing biofilms in dental unit water lines²⁴⁰ and have even been marketed for this purpose. Cautious clinicians may prefer to wait for more studies to demonstrate safety and efficacy under ordinary clinical setting conditions before adopting newer, less tested irrigating solutions.

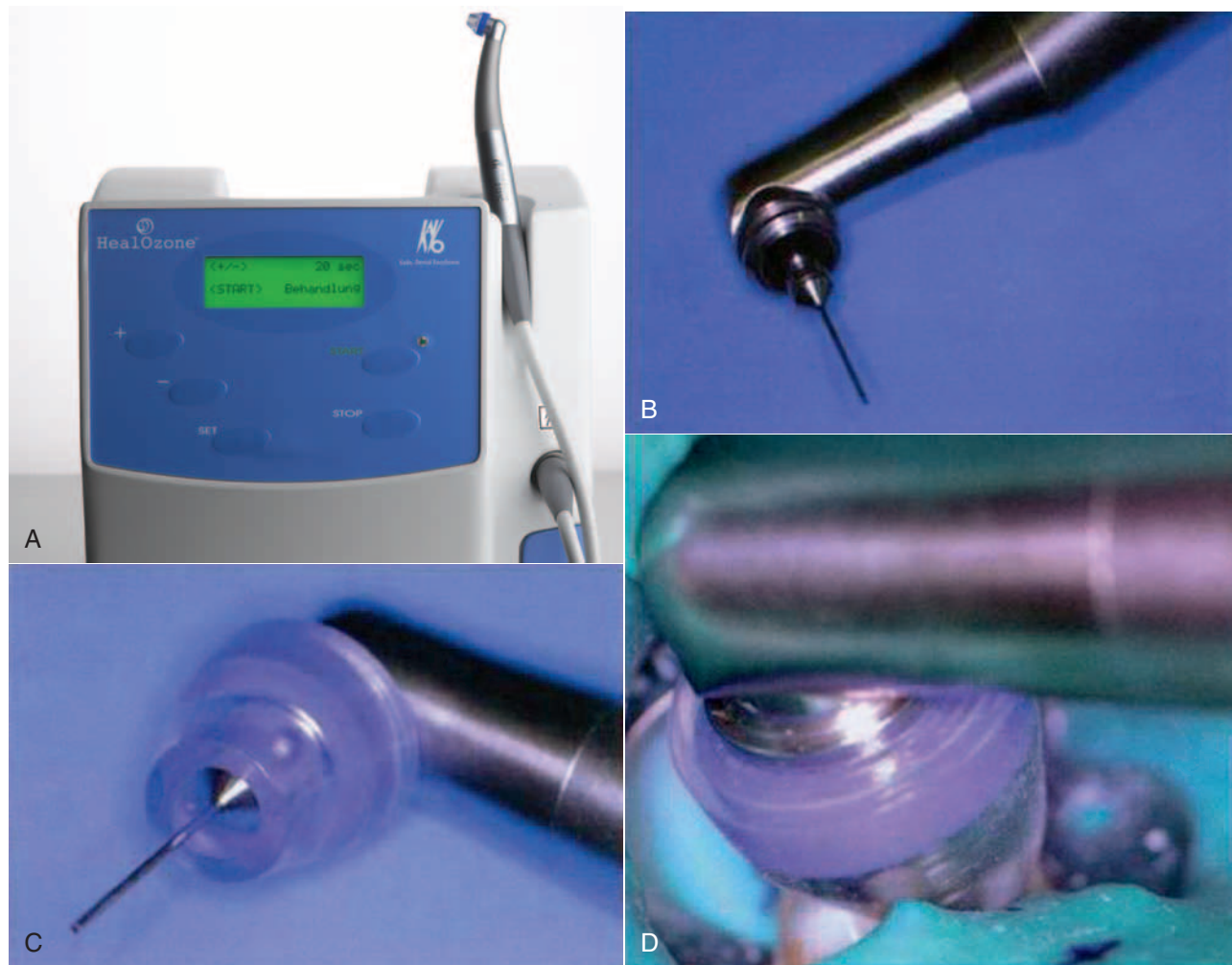


FIG. 8-60 HealOzone equipment with a special tip for intracanal application. (A, Courtesy KaVo Dental GmbH, Biberach/Riss, Germany.)

Photoactivation Disinfection

Photodynamic therapy (PDT) or light-activated therapy (LAT) may have endodontic applications because of its antimicrobial effectiveness.¹⁵⁹ In principle, the strategy utilizes a selectively accumulated or endogenously produced photosensitizer (photoactive compound). The activation of photosensitizer molecules by a specific wavelength of light produces deleterious chemical entities that kill bacteria. The strong oxidizer generated during the process can act on multiple targets in a microbial cell, resulting in membrane damage, enzyme inactivation, and genomic and plasmid DNA damage, resulting in instantaneous death. In addition, the light-activated killing of bacteria has a wide spectrum of antimicrobial activity with a minimal chance of giving rise to a resistant microbial population, making it an ideal disinfectant. Fighting biofilm-mediated localized human infections is one of the potential medical applications of LAT.⁴¹⁰ The principal agent involved in bacterial killing is the oxygen-based free radical.¹⁵⁹ Unlike systemic therapeutic agents, LAT has the advantage of dual selectivity. Only those cells which have selectively accumulated the photosensitizer or possessing endogenously produced photosensitizers will be affected upon irradiation. Separately, the low-intensity light and the nontoxic photosensitizer generally

used in LAT are harmless. In addition, the use of an optic fiber helps in directing the irradiation to the intended site of application. Studies have highlighted the possibility of killing antibiotic-resistant strains of pathogenic bacteria using LAT.^{409,411} Because of the wide spectrum of antimicrobial activity, instant bacterial killing, and ability to target biofilm bacteria, the application of LAT-based regimens has great promise in root canal disinfection.⁴⁰⁰ However, a thorough knowledge about the behavior of the photosensitizer and the physicochemical characteristics of the microenvironment prevailing in the root canal system is necessary for disinfection to be effectively achieved. In advanced stages of infection with mineralized biofilms, it may be necessary to do a minimal mechanical preparation of the root canal prior to LAT to achieve maximum disinfection.

IntraLight Ultraviolet Disinfection

Ultraviolet (UV) light is widely used for disinfection purposes. IntraLight (InterLight, Or-Yehuda, Israel) consists of an intracanal UV illuminator shaped with dimensions of an endodontic file, which allows uniform circumferential illumination of the root canal walls with 254 nm UV light. In a recent *in vitro* study,²⁵⁵ root canals were infected with *E. faecalis* bacteria that

were allowed to grow and establish a biofilm on the root canal walls. Treatment with 5% NaOCl for 10 minutes failed to result in negative cultures in 53% of the canals. Similar results were reported by others.^{255,257} An additional illumination of the canal walls with 254 nm UV light (300 mJ/cm²) rendered 96% of the canals free of cultivable bacteria. A wide range of bacteria are sensitive to 254 nm UV light, including those that are resistant to Ca(OH)₂.²⁵⁷ The device is used as a supplemental disinfection after NaOCl irrigation in the canal. Otherwise, bacteria in the inner layers of thick biofilms may be protected from the UV light, which is absorbed by bacteria in the outer layers.²⁵⁷

ROOT CANAL FILLING MATERIALS

Solid Materials

After the root canal system has been appropriately prepared, it must be obturated with a material capable of completely preventing communication between the oral cavity and the periapical tissue wound. Materials used for this purpose should be compatible with healing. This is achieved by attempting to seal the root canal system at both its coronal and apical ends, as well as throughout the canal system, to seal the openings of accessory canals. Apical and intracanal obturation blocks the exit to the periradicular tissues from organisms that have survived in the root canal after cleaning and shaping. Coronal obturation prevents reinfection of the pulp space from the oral environment. The required physical and biologic properties make the selection of obturation material critical. The materials commonly used for root canal fillings normally can be divided into a solid phase and a cementing medium (i.e., a sealer).

Gutta-Percha

Gutta-percha is the most commonly used root canal filling material. It is a linear crystalline polymer that melts at a set temperature, with a random but distinct change in structure resulting. (See Chapter 10 for further discussion of the physical properties of gutta-percha). It occurs naturally as 1,4-polyisoprene and is harder, more brittle, and less elastic than natural rubber.

The crystalline phase has two forms, the alpha phase and the beta phase. The forms differ only in the molecular repeat distance and single-bond form. The alpha form is the material that comes from the natural tree product. The processed, or beta, form is used in gutta-percha for root fillings.³³³ When heated, gutta-percha undergoes phase transitions. The transition from beta phase to alpha phase occurs at around 115° F (46° C). An amorphous phase develops at around 130° F to 140° F (54° C to 60° C). When cooled very slowly (i.e., 1° F per hour), gutta-percha crystallizes to the alpha phase. Normal cooling returns the gutta-percha to the beta phase. Gutta-percha cones soften at a temperature above 147° F (64° C).^{139,333} These cones can easily be dissolved in chloroform and halothane and dissolve less in turpentine or xylene.

Modern gutta-percha cones that are used for root canal fillings contain only about 20% gutta-percha (Box 8-4). The major component is zinc oxide (60% to 75%). The remaining 5% to 10% consists of various resins, waxes, and metal sulfates. Antiseptic gutta-percha with various antimicrobial agents has been suggested, and several studies are available

BOX 8-4

Composition of Gutta-Percha for Endodontic Use

Gutta-percha cones
 Gutta-percha (19%-22%)
 Zinc oxide (59%-79%)
 Heavy metal salts (1%-17%)
 Wax or resin (1%-4%)

concerning the effect of these additives (see Medicated Gutta-Percha).

Because gutta-percha cannot be heat sterilized, other decontamination methods must be used. The most practical method is to disinfect the gutta-percha in NaOCl before use. This can be done in 1 minute if the cone is submerged in a 5% solution of NaOCl.³⁴² However, after this disinfection and before its use for obturation, it is imperative that the gutta-percha be rinsed in ethyl alcohol to remove crystallized NaOCl; such crystals may impair the obturation seal.³⁴⁹

Obturation with gutta-percha normally requires some form of compaction pressure, but real compression of gutta-percha is practically impossible.³³³ Pressure applied during root canal filling procedures does not compress gutta-percha, but rather compacts the gutta-percha cones to obtain a more three-dimensionally complete fill of the root canal system.

After heating, while cooling, there is a slight shrinkage of approximately 1% to 2% when the gutta-percha has solidified. Prevention of shrinkage is practically impossible in vertical warm compaction.^{139,334} Careful control of the temperature during warm compaction is crucial to prevent focal areas of unnecessarily high temperatures. Better temperature control is available with electrically controlled heating devices as the Touch 'n Heat, System B, Elements units (Sybron Endo), or the recently introduced vibrating heat carrier, DownPack⁶⁷ (Hu-Frieday, Chicago, IL), or HotTip (Discus Dental, Culver City, CA), all of which are more commonly used for this purpose (see Figs. 8-41 through 8-44).

Gutta-percha oxidizes with exposure to air and light and eventually becomes brittle.^{198,242} It should be stored in a cool, dry place (e.g., a refrigerator) for better shelf life. Methods of "rejuvenating" aged gutta-percha have been suggested.¹⁸⁹

Gutta-percha cannot be used as the sole filling material; it lacks the adherent properties necessary to seal the root canal space. Therefore, a sealer (cement) is always needed for the final seal. (See the following sections on sealers).

Manufacturers now supply gutta-perch cones in tapers matching the larger tapered rotary instruments (#.02, #.04, and #.06) (Fig. 8-61). An international standard has been accepted for gutta-percha cones, based on similar size and taper standards set forth for the endodontic files (ANSI No.78) (see Table 8-1). The tolerance is much less stringent for gutta-percha compared to files. An endodontic file must be manufactured with a tolerance of +0.05 mm. Consequently, with the same size instrument and gutta-percha cone, a difference in diameter of 0.07 mm (more than one file size) is possible (see Table 8-2 for gutta-percha cone sizes).

Gutta-percha has been extensively investigated as a root canal filling material in animals and has been proven biocompatible. Compared with sealers used for root canal obturation,

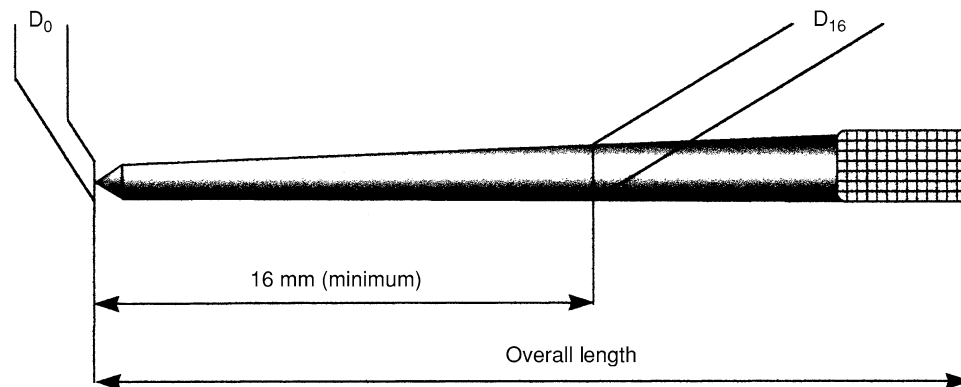


FIG. 8-61 Measurement points for gutta-percha cones as determined by ADA and ANSI standard #78.

it clearly has the lowest tissue toxicity. When compared to Resilon, both materials were equally biocompatible.³⁸ After subcutaneous implantation, gutta-percha normally becomes surrounded by a defined capsule rich in cells but without a significant number of inflammatory cells, although some macrophages are present.^{37,288,362} Results from more sensitive assays in vitro support the in vivo results, suggesting that gutta-percha used for root canal fillings has a low toxicity.²⁹⁵ Nevertheless, gutta-percha in the form of very small particles induces an intensive foreign body reaction, with massive accumulation of mononucleated and multinucleated macrophages.³⁶² This is not surprising, since materials that are normally considered inert (e.g., Teflon) cause similar reactions when presented to the tissues as an irregular surface or particle.⁵⁰

Resilon

Resilon (Pentron Clinical Technologies), a thermoplastic, synthetic, polymer-based root canal filling material, was developed in an attempt to create an adhesive bond between the solid-core material and the sealer. It is designed to be used with Epiphany (Pentron Clinical Technologies), a new resin sealer with a bonding capacity to dentin. Resilon can be supplied in the same ISO sizes and shapes (cones and pellets) as gutta-percha. The manufacturer has stated that it can be used with any current root canal obturation technique (lateral compaction, thermoplasticized, carrier, injection). When manufactured in cones, Resilon's flexibility is similar to that of gutta-percha. Based on polyester polymers, Resilon contains bioactive glass and radiopaque fillers (bismuth oxychloride and barium sulfate) with a filler content of approximately 65%. It can be softened with heat or dissolved with solvents such as chloroform. This characteristic allows the use of current retreatment techniques for nonhealing cases. Because it is a resin-based system, it is compatible with current restorative techniques in which cores and posts are placed with resin bonding agents (Figs. 8-62 through 8-64).³⁴⁸

Coated Gutta-Percha

Gutta-percha is now available that may achieve bonding between the solid core and a resin sealer. The uniform layer is placed on the gutta-percha cone by the manufacturer. When the material comes in contact with the resin sealer, a resin bond is formed. The manufacturer claims that this will inhibit leakage between the solid core and the sealer. The technique

calls for use of EndoRez sealer (Ultradent) with this new solid-core material (Fig. 8-65). The material with a resin sealer was compared with gutta-percha for microleakage. The results indicated a bonding between core and sealer resulting in far less microleakage than gutta-percha.³⁴⁸ Another study tested the apical sealer of methacrylate-coated gutta-percha, and it caused the least amount of leakage.⁴⁴⁵

Medicated Gutta-Percha

The melding of an antibacterial substance to a gutta-percha cone or other solid-core obturation materials may have utility in preventing root canal therapy failures due to coronal or apical microleakage. In an early study, $\text{Ca}(\text{OH})_2$ and CHX combined with zinc oxide and eugenol were found effective against the test organisms studied.³⁰⁵ It is interesting to note that gutta-percha and Resilon appear to have no antibacterial or antifungal effects in and of themselves. When tested against five common organisms found in necrotic root canal systems, both materials proved not to be effective.

Several studies have attempted to examine gutta-percha cones which were formed with various antibacterial and antifungal preparations. In one study,⁴² gutta-percha was impregnated with either CHX or $\text{Ca}(\text{OH})_2$ and tested against eight organisms commonly found in infected root canal systems. CHX demonstrated inhibition against all organisms studied, while $\text{Ca}(\text{OH})_2$ did not inhibit any of the same organisms. The antimicrobial effect of gutta-percha cones containing a mixture of both CHX and $\text{Ca}(\text{OH})_2$ was found superior when compared the antimicrobial effectiveness of either substance when tested separately.²⁹¹ Another study testing CHX or $\text{Ca}(\text{OH})_2$ with gutta-percha found CHX to be significantly more effective when tested in cultures of gingival fibroblasts.³⁸³ When epithelial tumor cells and gingival fibroblasts were used to test gutta-percha cones containing either CHX or $\text{Ca}(\text{OH})_2$, CHX samples showed significantly lower protein synthesis. Both tested materials induced cell growth-specific alterations.⁴²²

Early studies of medicated gutta-percha examined the use of iodoform in the solid-core material. While inhibitory against some pathogens, it was not inhibitory for all organisms.³⁵¹ A later study showed no differences between iodoform and regular gutta-percha samples in delaying microleakage of *E. faecalis*.⁵⁹ Gutta-percha discs impregnated with iodoform or other iodine combinations were tested against usual root canal system pathogens. Medicated gutta-percha inhibited all bacte-

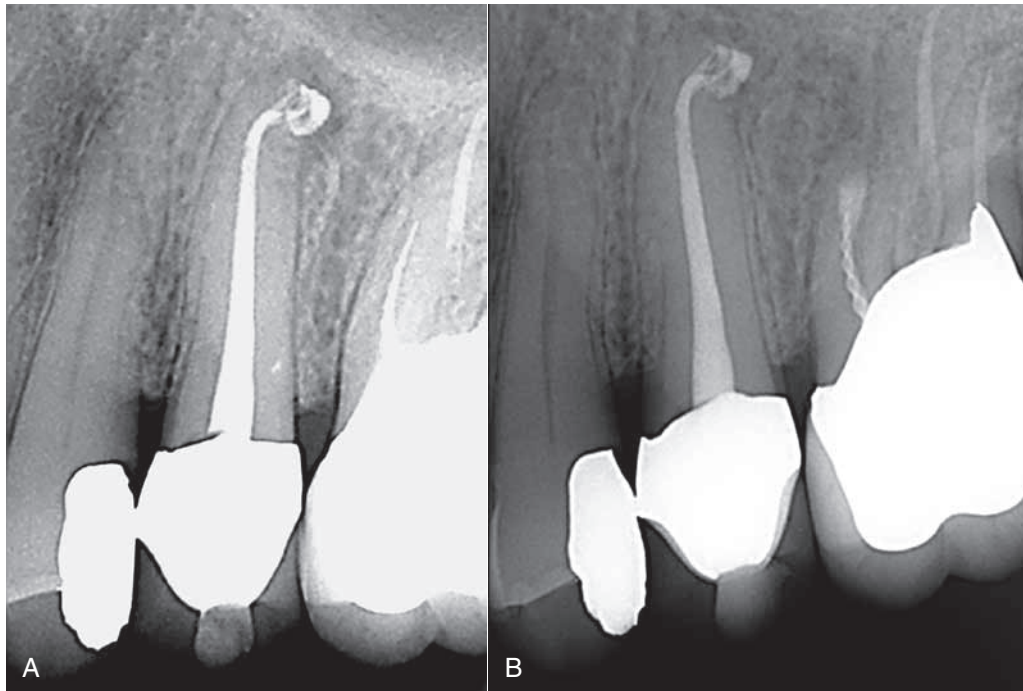


FIG. 8-62 A, Resilon/Epiphany cone root canal system obturation. **B**, Recall radiograph taken 8 months after initial treatment shows complete healing. (Courtesy Dr. Richard Rubenstein, Farmington Hills, MI.)

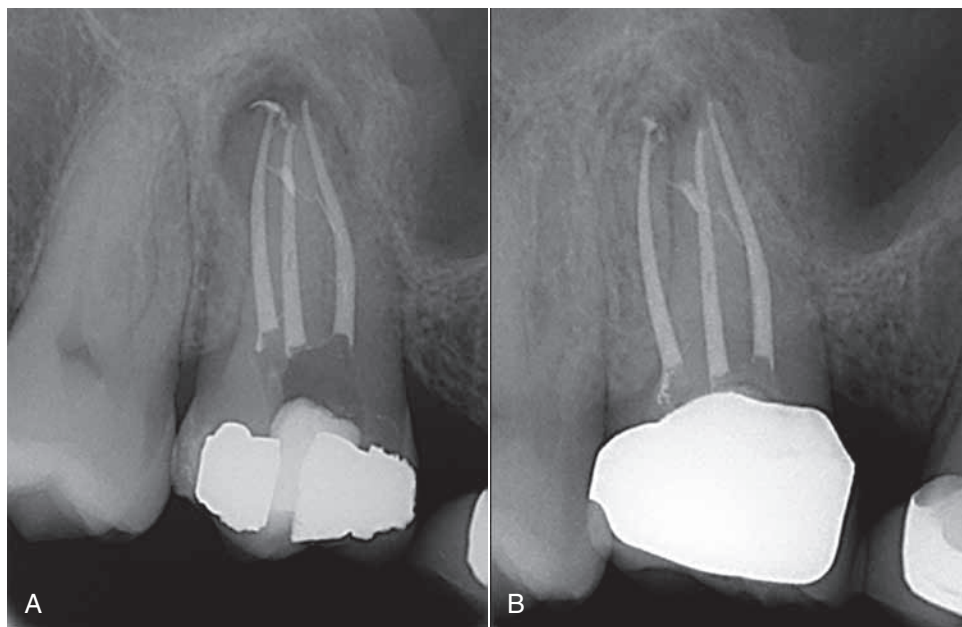


FIG. 8-63 A, Resilon/Epiphany root canal system obturation. **B**, Recall radiograph shows healing after 6 months. (Courtesy Dr. Richard Rubenstein, Farmington, MI.)

rial growth for 24 hours and was statistically more effective than regular gutta-percha.³⁵

When tetracycline impregnation was compared to iodoform-medicated gutta-percha cones and Resilon and tetracycline discs, the impregnated cones inhibited growth for all species tested.²⁵¹ Tetracycline integrated with gutta-percha

inhibited all test organisms when compared to conventional gutta-percha.³⁶

Although effective in the cited studies, medicated gutta-percha cones are not used on a regular basis. More testing must be done to investigate their toxicity, antibacterial and antifungal potentials, and potential for allergic reactions.

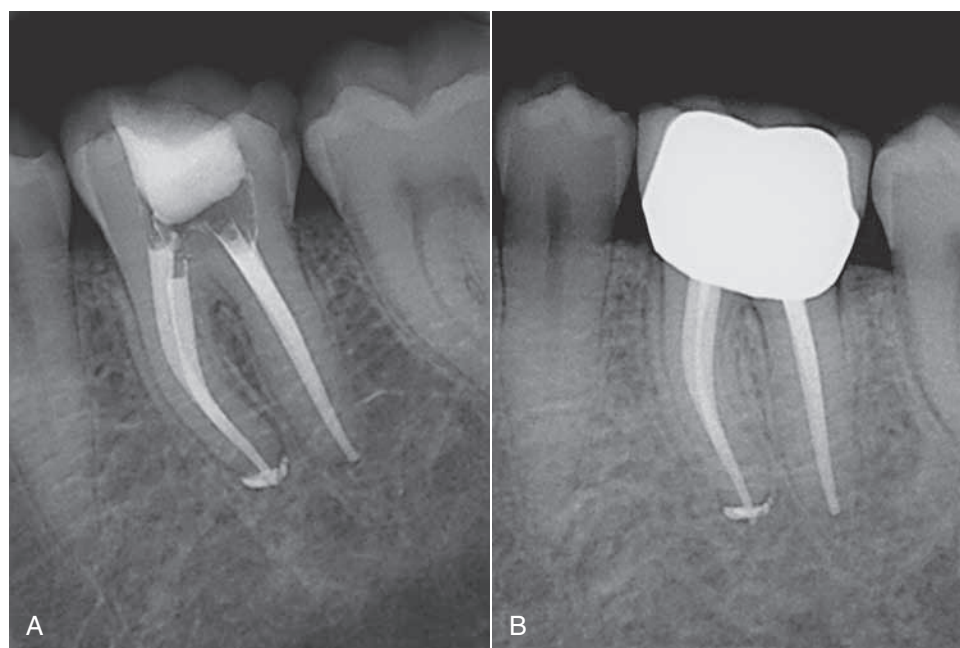


FIG. 8-64 A, Resilon/Epiphany root canal system obturation. **B,** Recall radiograph shows healing after 7 months. (Courtesy Dr. Richard Rubenstein, Farmington, MI.)

Sealers and Cements

Endodontic Sealers

The sealer plays an important role in the root canal filling. It fills all the space the solid-core material is unable to fill because of the solid core's physical limitations. A good sealer adheres strongly to the dentin and the core material. The sealer also must have cohesive strength to hold the obturation material together. Sealers ideally should be antimicrobial, which would be an important role in the success of root canal therapy. Sealers usually are made of a mixture that hardens through a chemical reaction. This reaction normally includes the release of toxic material, which makes the sealer less biocompatible. In general, the sealer is the critical component when the toxicity of material is assessed.

The sealer must have some degree of radiopacity to be visible on adequately exposed radiographs. Additives used to enhance radiopacity are silver, lead, iodine, barium, and bismuth. Compared with gutta-percha cones, most sealers have a slightly lower radiopacity and can be distinguished from gutta-percha alone or in combination with the sealer. A variety of sealers are available, and the clinician must be careful to evaluate all characteristics of a sealer before selecting one (Fig. 8-66, A-F).

Zinc Oxide Eugenol Cements

Many endodontic sealers are simply zinc oxide eugenol (ZnOE) cements that have been modified for endodontic use. The mixing vehicle for these materials is mostly eugenol. The powder contains zinc oxide that has been finely sifted to enhance the flow of the cement. The setting time is adjusted to allow for adequate working time. These cements easily lend themselves to the addition of chemicals; paraformaldehyde was sometimes added for antimicrobial and mummifying effects, germicides for antiseptic action, rosin or Canada balsam for

greater dentin adhesion, and occasionally corticosteroids for suppression of inflammatory reactions. However, the use of formaldehyde is completely unacceptable, given the possibility of its circulation to other body tissues and organs. Corticosteroids are generally not included in sealers in the United States; it appears that their effect is limited by the amount contained in the preparation.¹⁷⁶

Zinc oxide is a valuable component of the sealer. It is effective as an antimicrobial agent. The incorporation of rosins containing resin acids in sealers initially may have been for the adhesive properties.¹⁴⁸ Rosins (i.e., colophony), which are derived from a variety of conifers, are composed of approximately 90% resin acid. Resin acids are amphiphilic, with the carbon group being lipophilic, affecting the lipids in cell membranes. Thus the resin acids have a strong antimicrobial effect that in mammalian cells is expressed as cytotoxicity. The resin acids work similarly to quaternary ammonium compounds by increasing the cell membrane permeability of affected cells. Although toxic, the combination of zinc oxide and resin acids overall may be beneficial. Under certain conditions, resin acids may react with zinc, forming a resin acid salt (i.e., resinates). This matrix-stabilized zinc resinate is only slightly soluble in water,²⁴⁹ so ZnOE cements with resin components are less soluble than regular ZnOE cements.

The antimicrobial action of zinc oxide in both gutta-percha cones and many sealers create a low-level but long-lasting antimicrobial effect. In one study, a ZnOE sealer had a statistically significant larger mean zone of inhibition than three Ca(OH)₂ sealers.²⁶⁴ When a new preparation of ZnOE sealer (Fill Canal) was tested, it showed large zones of inhibition against all microorganisms tested.³⁵⁵

The setting of ZnOE cements is a chemical process combined with physical embedding of zinc oxide in a matrix of zinc eugenolate. The particle size of the zinc oxide, pH, and the presence of water regulate the setting and other additives

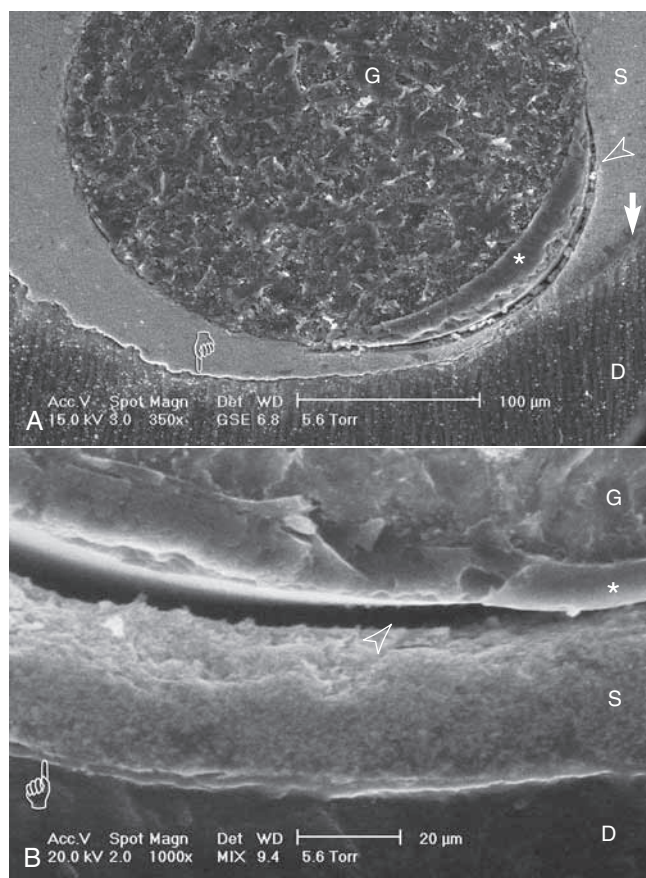


FIG. 8-65 **A**, EndoRez environmental scanning electron microscope (ESEM) image under hydrated conditions. When a gap appears, one can be certain that it is true, not an artifact. ESEM taken at relative humidity of 95%. **D**, Radicular dentin from coronal third of root canal wall; **G**, gutta-percha; **S**, EndoRez sealer; **asterisk**, proprietary coat in EndoRez GP cones; **open arrowhead**, true (not artifact) gap between root filling material and sealer; **pointer**: true gap along sealer-dentin interface; **pointer**: a gap-free region along sealer-dentin interface ($\times 350$). **B**, EndoRez ESEM, higher magnification of **(A)**, labels are similar. **Pointer**, Hybrid layer probably caused by demineralization of radicular dentin with 0.5M EDTA; **open arrowhead**, between sealer and gutta-percha ($\times 1000$). (Courtesy Dr. Franklin Tay, Medical College of Georgia, Augusta, GA.)

that might be included in special formulas. The formation of eugenolate constitutes hardening of the cement, and $\text{Ca}(\text{OH})_2$ accelerates this action, so canal systems containing $\text{Ca}(\text{OH})_2$ must be well irrigated before obturation. Free eugenol always remains in the mass and acts as an irritant.

Several of the companies producing ZnOE root canal cements have been replaced by new companies, resulting in new names for older preparations such as Rickerts sealer, Procosol, and Wach's sealer. Fill Canal (Ligas Odontologicas, Sao Paulo, Brazil), Tubli-Seal (SybronEndo), and Pulp Canal Sealer (SybronEndo) are three successors to the original ZnOE cements and have been recently investigated. *E. faecalis* is a highly resistant organism found in necrotic root canal systems. That organism was exposed to two ZnOE sealers, Roth's 811 and Kerr EWT. Roth's exhibited the largest zone of inhibition.²⁶³ Sultan, a ZnOE sealer, was one of the three most potent bacterial-growth inhibitors (*E. faecalis*).^{61,304,353} When *Candida*

albicans was used as the test organism, a ZnOE preparation demonstrated the largest zone of inhibition.²⁶⁹ A direct contact test determined that the virulence of endodontic pathogens determine response to sealers.²⁹⁸

Historically, formaldehyde was commonly mixed into endodontic sealers, but formaldehyde is a dangerous additive to any sealer; it adds to the already toxic effect of eugenol and prevents or delays healing. Chapters 11 and 27 further discuss why potential major liabilities exist for any dentist who unwisely chooses to use formaldehyde or paraformaldehyde during endodontic therapy.

Chloropercha

Chloropercha was another type of sealer used for many years. It is made by mixing white gutta-percha (i.e., alba) with chloroform. This allowed gutta-percha root filling to fit better in the canal. However, chloropercha has no adhesive properties and is no longer used as an obturation material in root canal therapy. The use of chloroform has been sharply curtailed for many years because of its demonstrated toxicity.⁴³⁶ In endodontics, the amounts normally used are insignificant and cause no detectable health hazard.^{39,60,338} Nevertheless, the clinician must take prudent steps to reduce vaporization during use, because chloroform is highly volatile. When used to soften gutta-percha during revision of old root fillings, the chloroform should be dispensed through a syringe and hypodermic needle and only passively expressed into the area of the pulp chamber. For other uses, the exposure time, amount used, and chloroform surface exposed should be kept to a minimum.

Some chloroform substitutes, such as halothane and turpentine, are in use. Compared to chloroform, halothane is less effective at softening gutta-percha, is similarly hepatotoxic, and has a higher local toxicity (Table 8-4). For these reasons, halothane is not a good substitute. Turpentine is not carcinogenic but is reported to cause allergic reactions.^{395,52} It has a high local toxicity and dissolves gutta-percha poorly. Therefore, no good substitute exists for the use of chloroform in endodontic procedures. With careful workplace hygiene, little risk is associated with the occasional use of minute amounts of chloroform in preparing customized master cones or when performing endodontic retreatments, provided no federal or state laws are violated.^{21,244}

Calcium Hydroxide Sealers

Several $\text{Ca}(\text{OH})_2$ -based sealers are now commercially available, such as Sealapex (Sybron Endo), RealSeal (Sybron Endo) Apexit and Apexit Plus (Ivoclar Vivadent). These sealers are promoted as having therapeutic effects because of their $\text{Ca}(\text{OH})_2$ content (Box 8-5). The antimicrobial effect of $\text{Ca}(\text{OH})_2$ is thought to occur because of its ability to release hydroxyl ions and by having a high pH.²⁹⁷ Short-term direct contact tests have shown Sealapex and Apexit to be mildly effective antimicrobial agents.

These sealers also have poor cohesive strength.³²⁵ No evidence supports the contention that a $\text{Ca}(\text{OH})_2$ sealer provides any advantage for root canal obturations or has any of the desirable biologic effects of $\text{Ca}(\text{OH})_2$ paste. In a study of diffusion of hydroxyl ions into surrounding dentin after root filling with Sealapex and Apexit, no traces were found in teeth filled with Apexit. Some hydroxyl ions could be detected in the dentin close to the root filling with Sealapex.³⁷⁸ In vivo

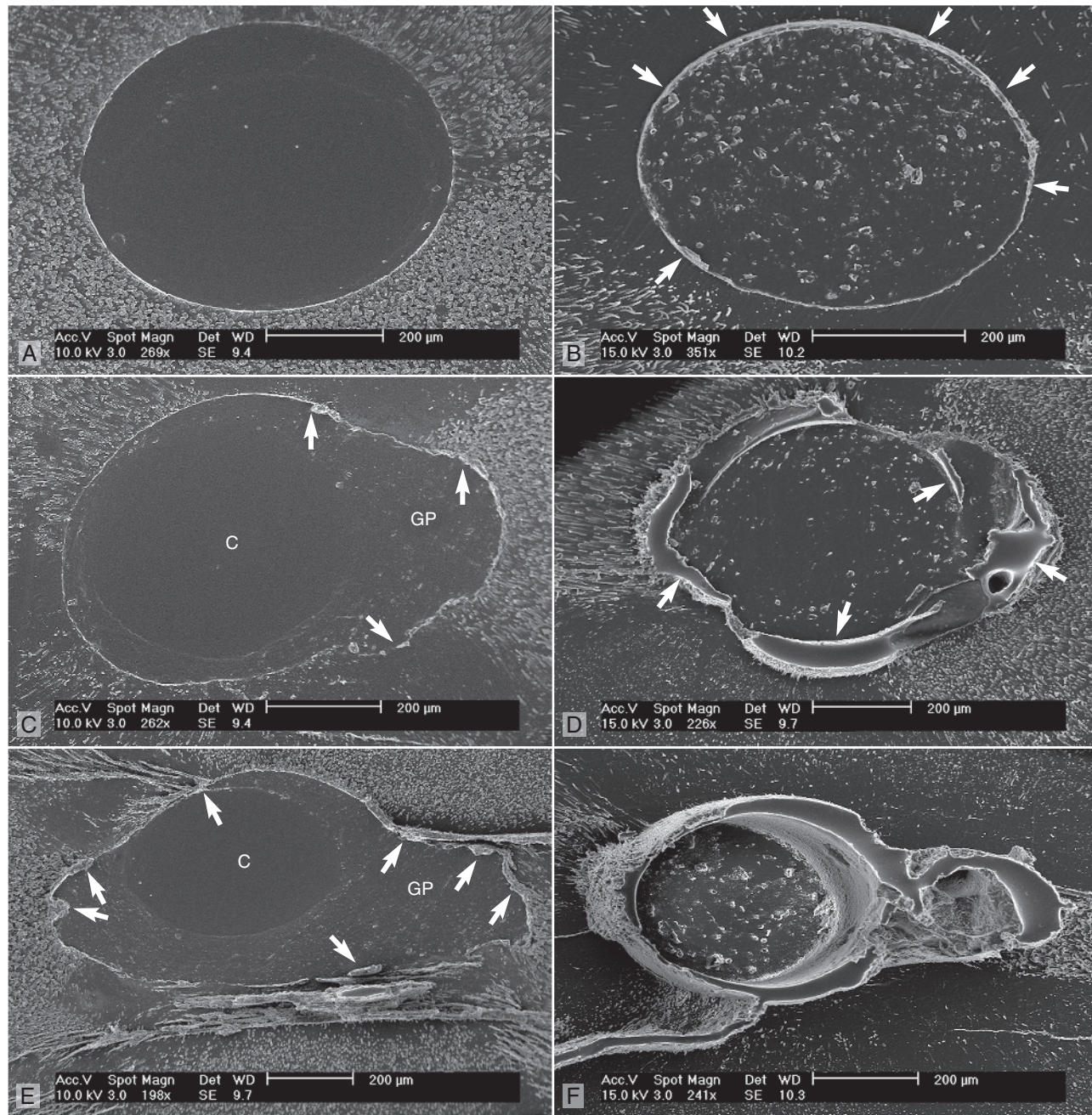


FIG. 8-66 Scanning electron microscope replicas comparing Resilon/Epiphany and Thermafil/AH Plus in variously shaped root canal systems. Impressions of the sectioned canals were taken with an ultraflow viscosity polyvinylsiloxane (PVS), and the replicas were directly examined. They are negative impressions of gaps, with PVS impression material flowing into the gaps. When the impression material was removed, a gap would appear as a flap of PVS material sticking out of the impression. All leaflets of PVS gaps appear blunt and stick out from the regions that represent root-filling material (arrows). Two views of each canal morphology are shown. **A**, Thermafil/AH Plus (×269), round, narrow canal shape. **B**, Resilon/Epiphany (×351), round, narrow canal shape. **C**, Thermafil/AH Plus (×198), wider, irregular canal shape. **D**, Resilon/Epiphany (×241), wider, irregular canal shape. **E**, Thermafil/AH Plus (×198), narrow, ribbon-like (rotary instrument) shape. **F**, Resilon/Epiphany (×241), narrow, ribbon-like (rotary instrument) shape. (Courtesy Dr. Franklin Tay, Medical College of Georgia, Augusta, GA.)

studies of Sealapex and CRCS (Coltene Whaledent, Altstätten, Switzerland) have demonstrated that these sealers easily disintegrate in the tissue, and both cause chronic inflammation.

Many studies have been conducted on various classes of root canal sealers, including $\text{Ca}(\text{OH})_2$. The majority of these studies report that *all sealers leak*.⁸⁵ $\text{Ca}(\text{OH})_2$ appears to be

effective in formation of dentin bridges when used as a direct capping material,^{4,107} which may indicate its ability to encourage formation of root-end hard tissue. It also appears to demonstrate acceptable antimicrobial activity. Success was seen at the same levels observed for mineral trioxide aggregate.³⁸⁷

TABLE 8-4

Toxic Effect of Gutta-Percha Solvents on L929 Cells In Vitro*

Time	Control	Chloroform	Halothane	Turpentine
AIR EVAPORATION				
Fresh Mix	7.2 ± 0.7	94.4 ± 3	102.5 ± 7.5	87.3 ± 2.2
1 day	10.1 ± 0.4	11.3 ± 1.8	12.6 ± 0.9	66.6 ± 5.3
7 days	9.5 ± 0.4	11.6 ± 0.9	14.8 ± 1	12.5 ± 2.8
LIQUID EVAPORATION				
Fresh Mix	7.2 ± 0.7	102.1 ± 6.4	98.4 ± 6.6	87 ± 2.1
1 day	10.1 ± 0.4	89.1 ± 6.7	103.9 ± 9	71.8 ± 4.7
7 days	9.5 ± 0.4	11.6 ± 5.8	10.1 ± 2.8	64.2 ± 3.9

*Gutta-percha (2.5 g) was dissolved in chloroform, halothane, or turpentine (5 ml). The cell injury was measured as mean percentage of release of ^{51}Cr ($M \pm SD$) at various times after mixing. The solvents were allowed to evaporate in air or through a liquid layer. The higher the release, the higher the toxicity. (From Barbosa SV, Burkard DH, Spångberg LSW: Cytotoxic effect of gutta-percha solvents. *J Endod* 20:6, 1994.)

Despite the favorable responses seen in the cited study, the results must be considered ambivalent and variable. Adhesion of the sealer to the prepared dentin wall and the solid-core obturation material also is a consideration. There is no creditable information that states that $\text{Ca}(\text{OH})_2$ sealers in and of themselves provide adhesive forces. One study does state that use of an erbium-doped yttrium aluminum garnet (Er:YAG) laser does increase the adhesiveness of $\text{Ca}(\text{OH})_2$ sealers.²⁷

Polymers

Polymers are macromolecules composed of 10,000 or more atoms. Rubber has a polymeric structure based on a repeating isoprene (monomer). Polymeric molecules, discovered in nature (rubber), have led to synthetic analogs with a variety of properties and applications, such as adhesives (root canal sealers). While it is more convenient to discuss polymer sealers according to their classification or type, it may be more meaningful to describe them according to their ability to act in a particular manner based on what or how each group of sealers' characteristics are when used, such as their adhesiveness, sealing ability, and similar properties.

When considering the adhesiveness of a sealer, it must have the ability to adhere to both the prepared dentin wall and the solid-core obturation material used. As such, adhesiveness becomes very important in the material's ability to seal the prepared root canal system from coronally and apically, since the preparation procedures appear unable to sterilize the root canal space and at most may only disinfect the system.

Other significant sealer considerations include their biocompatibility, radiopacity, cytotoxicity, and bond strength.

Most of the newer sealers are polymers, including AH26 and AH Plus (Caulk/Dentsply), Epiphany (Pentron Clinical Technologies), and EndoRez (Ultradent).

AH26

AH26 is an epoxy resin that was initially developed as a single obturation material. Because of its positive handling character-

BOX 8-5

Composition of Calcium Hydroxide Sealers: Sealapex, CRCS, and Apexit*

Sealapex

Base

Calcium hydroxide (25%)
Zinc oxide (6.5%)

Catalyst

Barium sulfate (18.6%)
Titanium dioxide (5.1%)
Zinc stearate (1%)

CRCS

Powder

Calcium hydroxide
Zinc oxide
Bismuth dioxide
Barium sulfate

Liquid

Eugenol
Eucalyptol

Apexit

Base

Calcium hydroxide (31.9%)
Zinc oxide (5.5%)
Calcium oxide (5.6%)
Silicon dioxide (8.1%)
Zinc stearate (2.3%)
Hydrogenized colophony (31.5%)
Tricalcium phosphate (4.1%)
Polydimethylsiloxane (2.5%)

Activator

Trimethyl hexanedioldiasalicylate (25%)
Bismuth carbonate basic (18.2%)
Bismuth oxide (18.2%)
Silicon dioxide (15%)
1,3-Butanedioldiasalicylate (11.4%)
Hydrogenized colophony (5.4%)
Tricalcium phosphate (5%)
Zinc stearate (1.4%)

*Proportions are unavailable for CRCS and incomplete for Sealapex.

istics, it has been extensively used as a sealer. It has a good flow, seals well to dentin walls, and has sufficient working time.²²⁴ Like most sealers, AH26 is very toxic when freshly prepared.²⁹⁵ Earlier research indicated that AH26 toxicity was limited and principally caused by release of small traces of formaldehyde.^{34,176} However, recent studies using more modern methods of analysis indicate that the sealer's mechanism for induced cytotoxicity may be due to activation of COX-2 in RNA gene expression,¹⁷⁵ leading to decreases in iNOS protein expression,²¹⁵ and the synergistic effects of root canal sealers on LPS induces COX-2 expression by macrophage cells.²¹⁴ Toxicity may decline rapidly during setting, and after 24 hours the cement may have one of the lowest toxicities of endodontic sealers.¹⁸⁷ A new formulation of AH26 is AH Plus. This is a two-paste mixing system that assures a better mixture and does not release formaldehyde upon setting.^{63,218} It is more radiopaque and has a shorter setting time (approximately 8 hours), lower solubility, and a better flow compared with AH26. One study demonstrated that AH Plus had a lower short- and long-

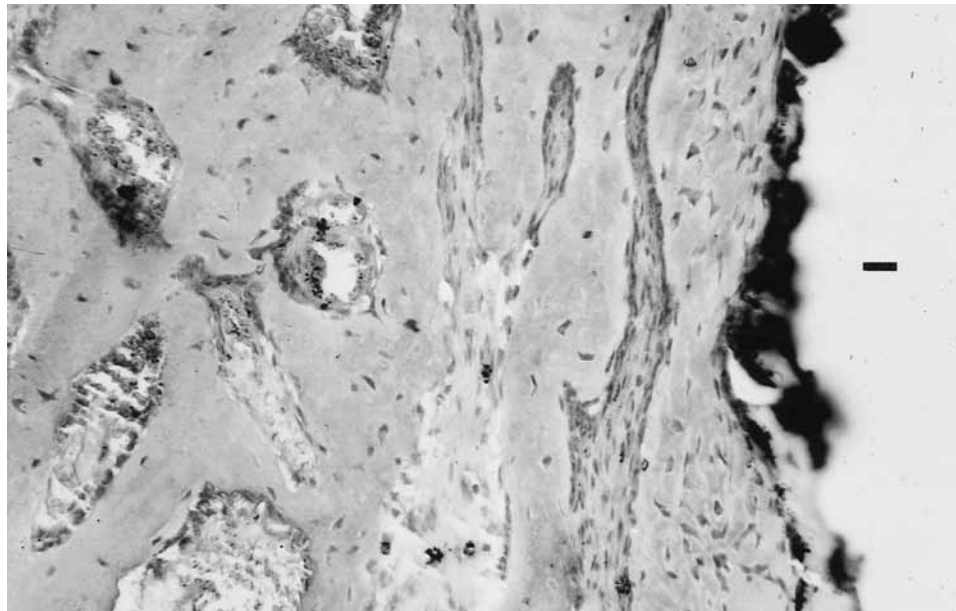


FIG. 8-67 AH26 implant in the mandible of a guinea pig 12 weeks after implantation. Bone has grown up and integrated with the implant. Remnants of the implant, which was lost during histologic preparation, can be seen as a black area at the top of the image. Complete healing was observed without signs of inflammation.

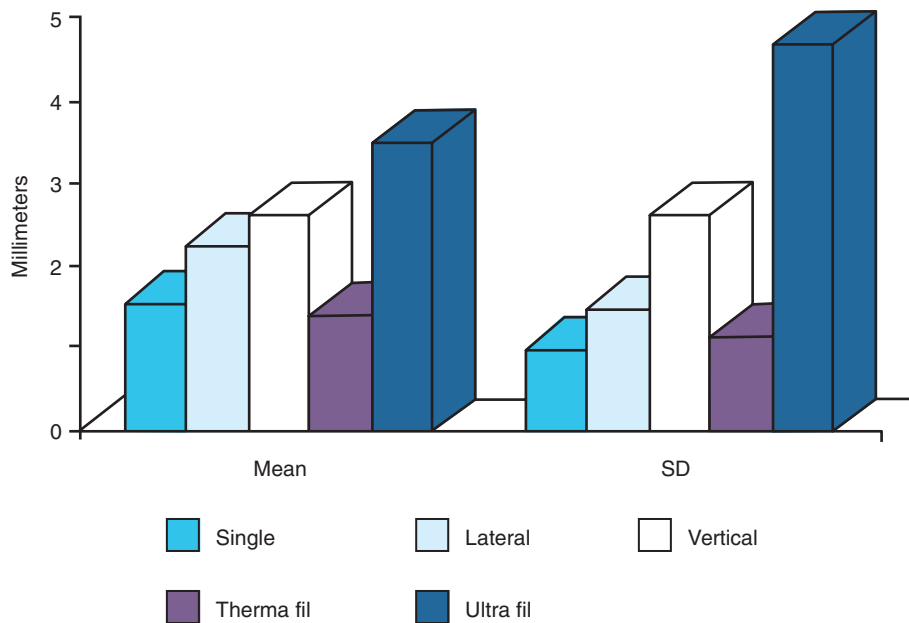


FIG. 8-68 Comparison of dye penetration after various obturation methods using AH26 sealer. The dye was delivered with a vacuum method, and penetration was measured as millimeters of leakage. The single cone technique and use of ThermaFil resulted in the least leakage, followed by lateral compaction, vertical compaction, and use of UltraFil. The standard deviation is high, as is common for leakage studies, reflecting the variability in the obturation method. The less complicated the obturation method, the lower the standard deviation.⁶⁹

term toxicity level and was less genotoxic than AH26 (Figs. 8-67 and 8-68).^{16,222}

Epiphany

Epiphany is a dual curable dental resin composite sealer composed of BisGMA, ethoxylated BisGMA, UDMA, and hydrophilic difunctional methacrylates with fillers of Ca(OH)₂, barium sulfate, barium glass, and silica. The total filler content of the sealer is approximately 70% by weight. Biocompatibility has been demonstrated both in vitro and in vivo, resulting in

approval by the U.S. Food and Drug Administration. Epiphany was designed for use with Resilon instead of gutta-percha, although it can also be used with either core material. Unlike other resin sealers, this system's sealer requires a self-etch primer before placement of the resin sealer.³⁴⁸ The newest iteration of the sealer utilizes a self-etching injectable paste that bonds to the prepared dentin walls and the solid-core material. Although not without controversy, used with Resilon cones, the subsequent obturated canal system may be fracture resistant.^{182,423}

EndoRez

EndoRez is a UDMA resin-based root canal sealer with hydrophilic properties that allow good penetration into dentinal tubules. In addition to its biocompatibility,^{442,445} it offers good radiopacity. EndoRez is as radiopaque as gutta-percha, which simplifies radiographic interpretation (Fig. 8-69).⁴⁴⁴ The system includes a sealer, solid cores (resin-coated gutta-percha) and an accelerator and does not rely on heat to soften the material or pluggers to exert pressure to move the core apically. Much like Resilon/Epiphany, the bonding to both the dentin and solid core is thought to make the completed obturation resistant to fracture.¹⁶⁰

Glass Ionomer Cement

Glass ionomer cements have been introduced as endodontic sealers (Ketac-Endo [ESOE]) and are known to cause little tissue irritation,⁴⁴³ with low toxicity in vitro. Questions remain about the quality of the seal achieved with Ketac-Endo, because dentin and sealer adhesive failures have been observed.⁷⁷ Some investigators have expressed concern about glass ionomers' solubility compared with other sealers.³³¹

Silicon-Based Sealer

RoekoSeal (Roeko, Langenau, Germany) is a polydimethylsiloxane-based root canal sealer. One in vitro study comparing it with eugenol-based Sealapex or Ca(OH)₂-based Kerr's Pulp Canal Sealer concluded that RoekoSeal was less cytotoxic.⁸ It has adequate solubility properties.³³¹ When its resistance to coronal and apical leakage was compared with that of AH26, no significant difference was observed.⁶¹ With both sealers, removal of the smear layer improved the coronal and apical

seal. Roeko recently introduced another version of its silicone sealer, GuttaFlow. It comes in a unidose capsule and is injected after mixing. The silicone is mixed with gutta-percha powder to form what the company calls a "two-in-one" cold filling system. GuttaFlow and RoekoSeal have recently been examined for spreadability on dentin and gutta-percha surfaces and compared to Roth 801 and AH26 sealers. Use of a sufficient load during lateral compaction is necessary for RoekoSeal and GuttaFlow to satisfactorily wet gutta-percha and dentin.²⁰⁰ Microleakage and sealing ability also have been tested. When RoekoSeal and GuttaFlow were compared to other sealers, leakage patterns were found to be similar to other sealers.⁷⁵ GuttaFlow showed similar leakage results when used with lateral compaction or System B techniques, but it demonstrated expanding capacity over time compared to compacted gutta-percha and AH26 over a 12-month period.²⁰⁰ When GuttaFlow was compared to two single-cone obturation systems, it was found that the apical seal was as effective as AH Plus used with vertical compaction.²⁷⁴ However, in a dual-chamber leakage model with *Streptococcus mutans* as a biologic marker, thermoplasticized gutta-percha with AH Plus using vertical compaction was more effective in minimizing bacterial leakage.²⁷³ Evaluating the long-term sealing ability of GuttaFlow compared to Epiphany, PCS, and AH Plus, GuttaFlow and Epiphany allowed less fluid movement.⁴¹

Sealers Containing Formaldehyde

A large group of endodontic sealers and cements had substantial paraformaldehyde additives. Some of the more common brands were Endomethasone, Riebler's paste (Amubarut; Wera Karl, Biensingen, Germany), and N2 (Indrag-Agsa, Bologne,




FIG. 8-69 Transmission electron microscope image illustrates the application of EndoRez sealer to smear layer–covered dentin (created by Profile nickel-titanium instruments) following use of 6.15% NaOCl initial rinse and sterile distilled water as final rinse. (Manufacturer recommends use of EDTA as final rinse). **A**, A gap (asterisk) seen between the sealer (S) and radicular dentin (D). Smear plugs (open arrowheads) retained along orifices of dentin tubules (T). The smear layer was originally loosely attached to the canal wall dentin surface. EndoRez was applied to canal walls after NaOCl and distilled water irrigation, the resin portion of EndoRez (fillers) did not penetrate the loosely arranged smear layer particles. **B**, During polymerization of EndoRez, shrinkage stresses pulled the smear layer (pointer) away from the dentin, resulting in the smear layer being attached to sealer (S). Gap filled with epoxy resin used for embedding. (Courtesy Dr. Franklin Tay, Medical College of Georgia, Augusta, GA.)

Italy). All of these sealers have essentially the same toxicity. N2 is also known as RC-2B or the *Sargenti technique*. Historically, it has been heavily commercialized. There are no creditable studies available as to establish this material's use clinically. (Chapter 11 presents a more comprehensive discussion.) There are no clinical conditions to justify the use of these pastes.

N2 is basically a ZnOE sealer. Its composition has varied extensively over the years. The significant amount of lead oxide and smaller amount of organic mercury that were formerly major toxic components are often missing in more recent formulations. However, N2 still contains unacceptable amounts of formaldehyde.⁴⁴ Because it contains 6% to 8% paraformaldehyde (and sometimes hydrocortisone and prednisolone), it loses substantial volume when exposed to fluid. It also absorbs more than 2% of fluid during the first week in situ.

N2 is extremely toxic in experiments in vitro and in animal experiments. The tissue reaction normally observed is a coagulation necrosis within a very short time. The coagulated tissue is altered to such an extent that it cannot undergo any repair for months because it is impregnated with formaldehyde. With time, the formaldehyde may be washed out of the necrotic tissue, allowing either bacteria to be established in the necrosis or, if the blood supply is adequate, repair to take place.

The Interstate Commerce Commission of the U.S. Government has banned the transport of N2 across state lines, effectively halting the sale of these types of sealers. Please read Chapters 11 and 27 to gain a fuller understanding of the legal consequences of using these unacceptable pastes in unwary patients.

Standards and Properties

Physical Properties

Endodontic sealers are listed under ANSI/ADA specification number 57, Endodontic Sealing Material 2000 (reaffirmed 2006). This specification is for material used in endodontics within the tooth to seal the root canal space. This specification in an adoption of ISO6876:2001. ANSI/ADA Standard 57 outlines various test methods for evaluation of the physical properties of endodontic sealer-filling materials. Sealers are classified into two categories, depending on the intended use: type I materials are intended to be used with core materials; type II materials are intended for use with or without core material or sealer. Type I materials are divided into three classes. Class 1 includes materials in the form of powder and liquid that set through a nonpolymerizing process; class 2 includes materials in the form of two pastes that set through a nonpolymerizing process; class 3 includes polymer and resin systems that set through polymerization. The subclasses for type II materials are the same as for type I materials, except that metal amalgams are also included. ANSI/ADA No. 57 describes testing methods for working time, setting time, flow, film thickness, solubility, and disintegration; it also establishes a specific requirement for radiodensity. The tests for endodontic core materials include determinations of the material's dimensions, brittleness, and flow. A separate ANSI/ADA standard (No. 78) examines prefabricated metallic or polymeric-based cones used in obturation procedures. Despite the standard's often detailed requirements, significant disagreement exists on the ideal

properties of endodontic sealers and fillers, so most of these expectations are guidelines that have not significantly affected the industry.

Biologic Properties

ANSI/ADA No. 41 recommends protocols for biologic evaluation of dental materials. This document covers recommended standard practices for biologic evaluation of the safety of materials used in dentistry and is not intended for use in the evaluation of pharmacologically active medicaments. This document outlines recommended test protocols for various dental materials, including certain guidelines for endodontic filling materials. These methods include general toxicity assessments (LD_{50}), cytotoxicity assessments in vitro, sensitization assays, mutagenicity assays, implantation tests, and usage tests. It was last updated in 2006. Several test methods are presented for each of these factors, depending on the type of material.

Root canal filling materials generally are toxic, and none fulfills the expectations set forth in ANSI/ADA No. 41. However, the methods described in this specification can be used to distinguish more toxic materials. Less toxic materials produce a less intense or shorter chemical insult to the remaining apical pulp or apical periodontium. If the wound area is free of bacteria when the initial chemical necrosis occurs, as results from sealers containing paraformaldehyde, tissue repair should occur as the initial irritant declines in intensity. Some tissue irritation may occur as a result of phagocytosis of particles of the material, but an expanding lesion would not develop.³⁶²

Endodontic sealers other than those that contain paraformaldehyde should not be implicated as the cause of a periradicular bone lesion. If the tissue in the apical root area is not sterile due to infection within the root canal system, presence of sealer should not cause a chemically induced periradicular necrosis. Thus, materials that cause extensive tissue necrosis inside the root canal may become vehicles for the development of failure of endodontic treatment. This supports the idea that treatment should focus on the proper application of asepsis and antisepsis, and that materials that are as biocompatible as possible should be used.

Sealers and cements are the very toxic component of gutta-percha root filling techniques. Therefore, the clinician must take great care in selecting materials and must have an understanding of what each material contributes to a disease process. ZnOE cements have a significant drawback in their release of free eugenol and loss of volume during the hydrolysis that takes place after setting. This is somewhat mitigated by its change into a relatively inert eugenolate substance within 24 to 48 hours. Several of the polymer materials have high toxicity during the polymerization phase but may become practically inert when polymerized. Sealers with inclusions of dissolvable components, such as $Ca(OH)_2$, lose these components in the tissue, resulting in compromise of the integrity of the obturation.

DELIVERY SYSTEMS FOR ROOT CANAL OBTURATION MATERIALS

The search for a more simplified and proficient obturation technique has led to the development of many new hybrid materials. Differences focus on alternative systems for introducing the solid-core material into the root canal system while

maintaining length control. The newer methods currently in use vary considerably. Most hybrid obturation methods require modification of the outline of the root canal preparation. One hybrid preparation technique involves the use of a rotating instrument that spins in the opposite direction of normal rotations and feeds the obturation material into the canal system instead of moving it out of the system. For optimal results, the clinician must consider technique variations before attempting a hybrid obturation method. A comparison of the more commonly practiced obturation methods, using an objective and sensitive vacuum dye penetration method, failed to show any major difference in the quality of the obturation.⁶⁹ However, dye penetration techniques have come into question in recent years. Other evaluation methods, such as dye extraction and fluid filtration techniques, seem to produce more consistent and credible data.⁵¹

The introduction of new materials, techniques, and delivery systems is challenging basic beliefs and concepts previously thought to be standard. For example, use of a single cone of gutta-percha with sealer historically has been considered unacceptable. However, with the introduction of new technology for cleaning and shaping and the development of innovative sealer delivery systems, a paradigm shift may be occurring toward improved canal preparation to receive more flowable sealers and a single insertion of a core material. To validate the long-term success of any of the obturation techniques, clinical studies to support evidence-based practice must be one of the goals of endodontic research.

Carrier-Based Systems

ThermaFil, ThermaFil Plus, ProTaper, and GT Obturators (Tulsa Dentsply) are obturation systems in which alpha-phase gutta-percha is preapplied to a flexible solid central carrier (Fig. 8-70). The gutta-percha obturator is heated in a proprietary heater (ThermaPrep Plus Oven, Dentsply Tulsa Dental, Tulsa, OK) (Fig. 8-71) to the appropriate softness, and after the placement of canal sealer, the obturator is placed into the canal. These devices are available with a plastic, stainless steel, or titanium carrier core. In one study, ThermaFil demonstrated a greater percentage of canal obturation than either System B compaction or lateral compaction.⁷⁶ If necessary, the plastic core material can be softened with chloroform or heated using a System B⁺ for easy removal. These obturators offer an alternative method of obturation with gutta-percha.

SimpliFill (Discus, Culver City, CA) (Fig. 8-72) is an obturation system designed to be used with the LightSpeed instrumentation system. The technique is based on a presized plug (5 mm long) of gutta-percha or Resilon which is attached to the end of a metal carrier. After sealer has been placed, the appropriate size SimpliFill is placed to working length, and the carrier is removed, leaving the apical segment obturated and the coronal segment open. Sealer is then injected with a syringe into the coronal segment, and a single cone (gutta-percha or Resilon) or post is inserted. In a study of coronal microbial leakage, an apical plug of SimpliFill in combination with FiberFill (Pentron Clinical Technologies, Wallingford, CT) in the coronal segment of canals was found to have significantly less leakage than lateral, vertical, and Obtura II (SybronEndo, Orange, CA) compaction techniques.³⁴⁸ A later study found that SimpliFill samples demonstrated the most complete coverage in both coronal and apical sections when compared to



FIG. 8-70 ThermaFill obturators. Currently, obturators are provided to fit many of the individual types of files used in the canal. In this case: ProTaper instruments sizes F₃ and F₄ with their corresponding obturators. (Courtesy Dentsply-Maillefer, Ballaigues, Switzerland.)



FIG. 8-71 ThermaPrep Plus oven. (Courtesy Dentsply-Maillefer, Ballaigues, Switzerland.)



FIG. 8-72 SimpliFill system. Gutta-percha cone carried on a file-like metal handle. (Courtesy Discus, Culver City, CA.)

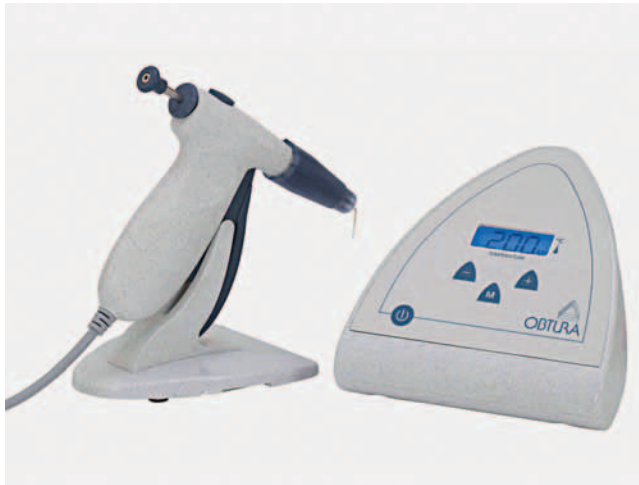

FIG. 8-73 Obtura gun for injectable gutta-percha. (Courtesy SybronEndo, Orange, CA.)

vertical compaction, Obtura II, System B and ThermaFil Plus.¹⁷⁷

Injection Techniques

Several techniques have been described for introducing gutta-percha into the root canal system after the gutta-percha has been plasticized with heat. The Obtura system (Fig. 8-73) is currently the most commonly used injection delivery system for gutta-percha.³⁸⁵ It dispenses a heavy form of gutta-percha heated to a high temperature. Although the temperature of the gutta-percha in the Obtura II injection gun is as high as 302° F to 338° F (150° C to 170° C), the temperature of the extruded material may range from 140° F (60° C) to 280° F (138° C).⁸⁹ When the Obtura II was compared to the System B heat source using different heat points, neither exceeded an increase of 10° C at any root level monitored.³⁸² Intracanal temperatures after delivery, measured with intracanal thermocouples, have ranged from 107.6° F to 192.2° F (42° C to 89° C). Periodontal injuries have been reported after excessive heat during endodontic treatment of teeth in the ferret and the dog.³²⁹ Recent studies testing the Obtura II found a 10° C increase in the mandibular anterior teeth in vitro,²²⁹ less temperature rise than when a gutta-percha carrier was combined with an injectable gutta-percha.²³⁰ Shrinkage of gutta-percha in these injectable gutta-percha systems does not appear to be different from the shrinkage of normally heated gutta-percha. When plasticized by heat, gutta-percha has a volume loss of approximately 2% after cooling.¹⁴⁵

Rotary Techniques

Frictional heat also can be used to soften gutta-percha. This was first suggested with the introduction of the McSpadden

Compactor device (Dentsply Maillefer). This technique has undergone many variations, with the development of several compaction instruments. The heat generated may exceed safe levels compared to other heat compaction techniques.³²⁹ One such device, Quickfil (J.S. Dental), has the ability to obturate root canals comparable to lateral compaction.⁶² Volumetric changes in the gutta-percha after friction heat compaction are similar to other types of gutta-percha compactions using heat. The major observed problem was the inability of the heated gutta-percha to fill the entire canal system due to the presence of sealer in the apical third of the preparation. Rotary techniques, although still used by practitioners, have become less popular in many instances with the introduction of the new solid-core resin polymer sealers.

Heating Systems

Although not injectable systems, Touch 'n Heat and System B (SybronEndo, Orange, CA), are involved with the placement and removal of gutta-percha from root canal systems using heat. Touch 'n Heat delivers a heated, pointed probe into a mass of gutta-percha, removing the material in small increments and down packing with pluggers after each removal. The gutta-percha is warmed approximately 5 mm ahead of the heating probe, and at a distance of 5 mm from the measured end of the master cone, a final down packing is made to move the remaining mass to the apex. The System B device is an outgrowth of the Touch 'n Heat and attempts to remove the greater bulk of gutta-percha to within 5 mm of the apex in one heated mass. These techniques are often combined with an injectable technique of obturation.

TEMPORARY RESTORATIONS

If endodontic therapy cannot be completed in one visit, the pulp space must be closed with a temporary restoration. The same is true whenever a root canal procedure is completed. This restoration must provide a satisfactory seal to prevent bacteria and fluids in the oral cavity from contaminating the pulp space. The restoration must have enough structural strength to withstand the masticatory forces and retain the occlusal seal. A literature search identified 28 materials that have been tested between 2000 and 2009 (Box 8-6). The most common such materials are IRM (Caulk, Dentsply), TERM (Caulk Dentsply), Cavit (3M ESPE) and Coltosol (Coltene Whaledent). IRM is a reinforced zinc oxide cement available as a powder-liquid mix in single-dose mixing capsules. Cavit is a premixed material composed of zinc oxide, calcium sulfate, glycol, and polyvinyl acetate, polyvinyl chloride, and triethanolamine. It sets upon contact with water. TERM is a filled composite resin that is light activated. When Cavit, IRM, TERM and Fermit (Ivoclar Vivadent, Schaan, Lichtenstein) (the latter two being light-cured preparations) were compared over a 21-day period, Cavit was found to be more resistant to leakage at 7 days.^{19,88} Coltosol and IRM were tested against two resins, and results showed they sealed statistically better than the resins. Coltosol is a non-eugenol preparation delivered by syringe.⁴³⁵ In another study,⁴⁴² coronal microleakage was evaluated after thermocycling, comparing Cavit, IRM, and a polycarboxylate cement (Ultratemp Firm). There was no statistically

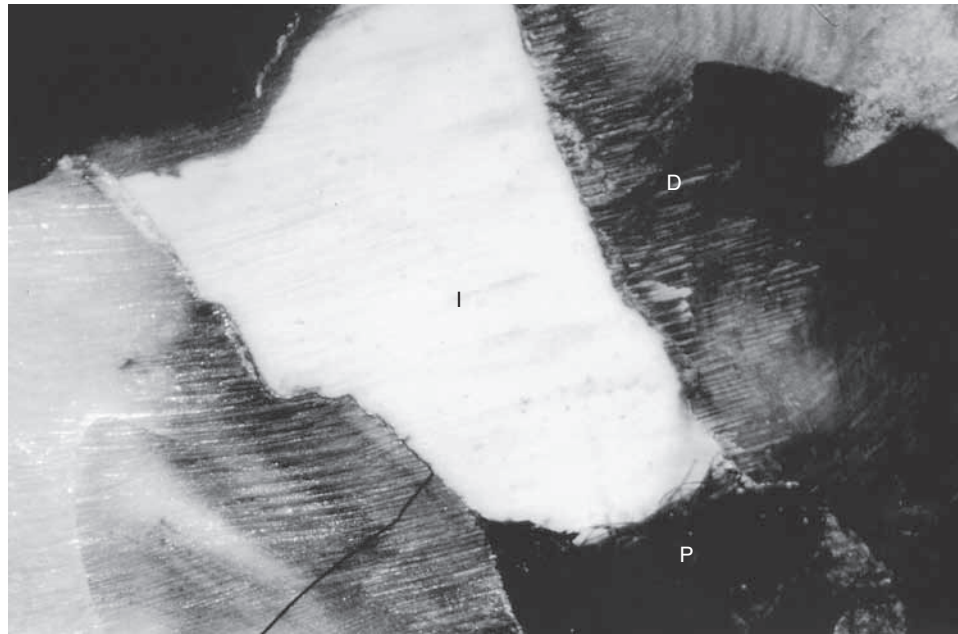


FIG. 8-74 Temporary filling of IRM (white I). The dye has penetrated the margins and dyed the content of the pulp chamber (P). The dentin (D) has been stained by the dye penetrating the margins.

BOX 8-6

Temporary Cements

Algenol
 Alsip
 Cavit, Cavit W,F
 Canseal
 Caviton
 Clearfil
 Coltosol
 Core Restore
 Dynest AP
 Dyract AP
 Fermit, Fermit N
 Fermin
 Fuji-IX-GP, Fuji II LC
 GI, GI Resin Modified
 IRM
 Ketac Fil, Ketac Fil Plus
 Ketac Silver
 Polycarboxylate Cement, Eugenol Free
 Scotch Bond
 Temp Bond
 TERM
 Ultratemp Firm
 Vidrion R
 Zinc oxide eugenol
 Zinc phosphate cement
 Z100 (Composite resin)

significant marginal microleakage between the three; IRM also absorbed the dye into the bulk of the material. IRM has extensive marginal leakage of fluid, whereas Cavit seems to absorb fluid into the entire body of the restoration.^{18,209} These findings are surprising; however, because of its eugenol content, IRM

may provide a bacterial barrier but allow leakage of other liquid substances (Figs. 8-74 and 8-75). Therefore, if Cavit or other types of relatively soft temporary cements are used, they must be placed at a thickness of at least 4 to 5 mm.⁴¹⁹ If a more robust temporary restoration is required for longer than 1 week, the soft cement must be covered with a harder cement such as IRM, glass ionomer cement, or resin.

The temporary coronal seal of endodontically treated teeth will not prevent coronal leakage if left for long time periods.¹⁹ The interval between sealing the canal system and placing the core buildup is possibly more important than the material used. In a *Colleagues for Excellence* newsletter, the American Association of Endodontists stated that “restoration ... should commence as soon as possible after RCT.”⁶⁵ Whenever possible, the bonded core buildup should be placed at the obturation appointment.

LASERS

Lasers are among the alternative methods used in endodontic treatment. Various laser wavelengths have properties that may be useful when applied to access cavity preparation, cleaning and shaping of root canal systems, and three-dimensional obturation procedures. The use of lasers for endodontics is becoming more predictable with the development of different wavelengths and radially emitting probes. One of the greatest strengths in using laser irradiation is its ability to cause a change in the hard tissue of the root canal space dentin. The change occurs in the morphology and physical aspects of dentin by melting and resolidifying dentin in a manner that closes the orifices of the dentinal tubules, which may harbor microorganisms and other organic pulpal remnants. However, this strength also turns out to be laser irradiation's greatest weakness. This occurs because of the dentin's location, con-




FIG. 8-75 Temporary filling with Cavit. Dye has been absorbed into the body of the restoration (C) but has not penetrated to the pulp chamber (P), which is filled with white cotton. The inner part of the Cavit is unstained.

fined to a space that is curved and cylindrical that cannot be viewed in a manner where the changes can be identified or visualized, such as can occur in cavity preparation procedures. A further weakness is the amount of energy needed to effect change of internal morphology. Intertubular dentin surfaces are in the shape of calcospherites rather than the relatively flat surfaces seen in extratubular coronal dentin, which can be easily visualized and affected by the laser. The amount of energy required for intertubular procedures generates increased temperatures that may cause harm to the attachment apparatus (cementum, periodontal ligament, and alveolar bone).

Dental lasers currently in use operate in several areas of the electromagnetic spectrum, including the infrared, visible, and ultraviolet ranges.^{374,375} Each laser wavelength in a particular range allows the device to target various tissues and carry out different procedures. Carbon dioxide (CO₂) is highly absorbed by tissues with high water content, and neodymium-doped yttrium aluminum garnet (Nd:YAG) can be absorbed by vascular tissues, having greater effect on gingiva and dental pulp tissue, respectively.

Early attempts using lasers to carry out cleaning and shaping functions were less than successful. The Nd:YAG laser used a contact probe that simulated a hand instrument, but it was composed of a fused silica (glass); it could not be pre-curved and could not be seen radiographically if it separated within the root canal system. In addition, the probe emitted energy at its end rather than radially over a 360-degree range. The result was a preparation that was neither fully clean nor shaped. Other lasers used noncontact probes that emitted the laser beams through a system of mirrors in an articulated arm (wave guide with CO₂). Their lack of contact with the dentin walls of the root canal system precluded a sense of touch available to the operator.^{194,248}

Neodymium-Doped Yttrium Aluminum Garnet Lasers

Several laser systems are now available that appear to be useful in root canal system preparation. Necessary to the success of these procedures is an understanding of the effects of irradiation on the morphology of the inner dentin walls. Nd:YAG lasers have been extensively studied in the past several years. A study showed that at increased power, the system produced globular formations and melting and glazing typical of earlier studies with this wavelength.³²⁶ The same group found that root canal systems treated with NaOCl and EDTA with Nd:YAG irradiation demonstrated partial obliteration of dentin tubules and removal of smear layer.¹⁰⁶ When an Nd:YAG laser was compared to a diode laser, scanning electron microscope (SEM) images showed fusion and resolidification of the dentin surface, more evident with the Nd:YAG group, but the diode group had more uniform changes.⁷⁹ The erbium/chromium-doped yttrium scandium gallium garnet (Er,Cr:YSGG) laser has also been extensively studied over the past several years since its inception, but to date, the studies have not demonstrated the same results seen with older laser systems. Improvement in the use of these systems will lead to a device that accomplishes all the requirements of a well-cleaned and shaped system and aid in three-dimensional obturation.²⁹⁴

More recent investigations have indicated that lasers are effective when used in infected root canal systems. When patients were treated using a step-back technique, half the teeth were treated with the Nd:YAG laser using NaOCl and H₂O₂ irrigants. Tenderness to percussion was less at 1 week and 3 months in the laser-treated groups compared to controls.¹⁹⁶

Removal of filling materials and broken files in retreatment cases is often difficult but effective if temperatures are con-

trolled.⁴³⁴ A recent study compared the removal of gutta-percha using two solvents with an Nd:YAG system, which raised root surface temperatures 4° C.⁴⁰⁷ Laser energy alone was found to be effective, whereas solvents did not appreciably improve removal.

Dentin exposed to the Nd:YAG laser was evaluated using five different irrigation solutions. The surfaces of the teeth were examined using a SEM, while dispersive x-ray fluorescence spectrometry assessed mineral content. Calcium levels and calcium/phosphorus ratios decreased significantly with NaOCl solutions, suggesting changes at the molecular level. Surface examination showed that the lowest scores for root cleaning occurred with the use of EDTA and the Nd:YAG laser.¹⁵⁴ The use of the Nd:YAG laser has been suggested as a more efficient way of handling this procedure. A study using the Nd:YAG laser using a flexible quartz fiber probe which is able to be concentrated in a specific area was used to remove gutta-percha and Sealapex or AH26 and was compared to use of Gates-Glidden drills and K-files. Results showed that the use of laser ablation was significantly shorter than conventional methods.¹¹

Erbium-Doped Yttrium Aluminum Garnet Lasers

Together with removal of obturation materials, lasers have been used in attempts to alter the dentin surfaces of root canal systems to create greater sealer adhesion. Single-rooted teeth were tested using an Nd:YAG laser. Black ink was used in one test group as an initiator, with two groups lasered without ink. Controls were not exposed to laser energy. Results demonstrated leakage in all groups at both coronal and apical test areas.⁸² Using an Er:YAG laser, extracted teeth were tested to determine whether increased adhesion occurred between ZnOE and resin sealers. The resin-based sealer (Sealer 26) adhered better to dentin prepared with and without laser exposure than ZnOE-based sealers.³⁶⁷ Increasing the frequency and use of EDTA increased adhesion when a resin sealer was used with either an Nd:YAG laser or Er:YAG laser.³⁶⁸ When a 980-nm diode laser was tested, bond strength again increased for the resin sealer (AH26) but did not affect adhesion of Epiphany sealer.⁹

When India ink was used to absorb energy to cause an effect, the Nd:YAG laser was found to remove smear layer and reduce apical leakage in extracted, obturated human teeth.¹⁴⁴ Others found the same results, showing that this laser wavelength was useful for reducing apical leakage in obturated root canal systems.^{55,236} The Nd:YAG laser was also used to seal the dentin surface after apicoectomy *ex vivo*.^{143,376,377}

The use of laser energy in endodontics receiving the most attention relates to cleaning and shaping (instrumentation) and laser-assisted endodontic procedures involving the use of laser irradiation within the confines of the root canal system. As noted earlier, this may cause increased temperatures extending to the outer root surface of the tooth and lead to damage to the attachment apparatus. An Er,Cr:YSGG laser used to instrument the root canal system walls for 7 seconds found average rises of temperature on the outer root surfaces were less than 8° C. An 810-nm diode laser recorded temperatures at less than 7° C when energy input was alternated with periods of no energy input. A 910-nm diode laser recorded differing

temperatures depending on what area of the root canal system was being affected. Highest temperatures were found in the apical third but were judged not to be in the range harmful to the attachment apparatus. An 810-nm diode laser was able to melt dentin, which resolidified and closed tubular orifices. Temperature rise was reported to be in the range of 1.6° C to 8.6° C, below those temperatures that would adversely affect the PDL.⁷⁴

The permeability of root dentin is an important consideration in endodontic therapy, and the laser has been suggested as a means of removing smear layer and melting and solidifying the walls of the preparation. Comparison of the Nd:YAG device to an Er:YAG laser showed that the former had lessened radicular dentin permeability with various irrigation regimens.⁴⁵ An *in vitro* study using extracted teeth that were inoculated with *E. coli* and *E. faecalis* found that Nd:YAG, Ho:YAG (holmium-doped yttrium aluminum garnet), and Er:YAG lasers eliminated 99% of the organisms without causing unfavorable temperature increases at the settings used.¹¹⁰

Temperature rise is an important consideration in the use of any laser energy. One study used 20 extracted human teeth and an Er:YAG laser at two irradiation intensities with water spray.¹⁹³ A temperature increase of less than 6° C was recorded at the apical third and less than 4° C in the midportion of the root, suggesting that the thermal effect on periodontal tissues may be minimal.

Although no widespread agreement exists on the need to remove the smear layer in root canal preparations, the Er:YAG laser has proved effective at accomplishing this task. An Er:YAG laser was compared with a CO₂ laser for ability to remove the smear layer.³⁸⁴ A comparison was also made with NaOCl, H₂O₂, and EDTA irrigation regimens. The Er:YAG laser was found to be the most effective of these methods at removing the smear layer. A more recent study, using radially emitting probes with Er:YAG and Er,Cr:YSGG lasers, increased the action of EDTA in removing thick, artificially created smear layers.¹³¹ An associated study found that the use of a radial-firing tip and Er,Cr:YSGG laser was a suitable tool for the elimination of microorganisms and removal of smear layer from root canal systems. A study in modification of root canal dentin found that by varying the electromagnetic wavelength, Er:YAG energy induced different modifications to the root canal surface, which may have some utility in preparation procedures.⁹¹

Sterilization of root canal systems has continued to be an aim of successful endodontic therapy. Chemical and other liquid medicaments have been utilized alone or in combination in an attempt to sterilize these systems, with no lasting effect. The idea of removing smear layer appears to be necessary in sterilization, and lasers have been suggested for that use and altering the intracanal dentin through melting and resolidification, causing closure of dentinal tubule orifices. An Er:YAG laser was used in posterior dogs' teeth that were necrotic with chronic periradicular lesions. Group 1 was treated by biochemical preparation, and group 2 was also bio-prepared but with laser irradiation. Teeth were sampled for anaerobes, aerobes, and total colony-forming units (CFU) 7 days post treatment. Results showed increased CFU for all microorganisms and significant reduction of anaerobes in group 1 and anaerobes and total CFU in group 2.²¹⁹ Using an

Er:YAG laser, other investigators⁴⁰⁴ found statistically similar results between laser-treated and conventionally treated groups. One study found that treatment with an Er:YAG laser showed effective antimicrobial action against *E. coli* and *Staphylococcus aureus*.³³⁷ The results were significantly better than those achieved with NaOCl. More recently, lasers were found to be effective against *Candida albicans* and four other test organisms. However, 70% of specimens lased 3 mm short of the apex remained infected.²⁹⁹

Diode Lasers

New laser systems using diodes are now available. In the presence of methylene blue or other dyes, diode lasers activate the dyes and cause photochemical reactions that produce reactive oxygen species. The process is termed *photoactivated disinfection* (PAD) and has the potential to eradicate persistent endodontic infections in cases where conventional methods may be unsuccessful. When used against four common root canal microorganisms (*Fusobacterium nucleatum*, *Peptostreptococcus micros*, *P. intermedia*, *Streptococcus intermedius*), significantly higher numbers were killed. When pathogens in planktonic phase and *E. coli* biofilms were sensitized with methylene blue and treated with red light, all organisms were eliminated. When energy levels were raised, 97% of *E. faecalis* was also eliminated. Other studies resulted in the conclusion that the use of photoactivated disinfection resulted in maximum elimination of microorganisms, especially *E. faecalis*.*

However, when comparing teeth treated conventionally, using rotary instrument NaOCl and EDTA versus the added use of Er:YAG laser system, neither method eliminated infection.¹⁸⁵ An in vitro study using the Er:YAG laser system found that it was effective against six of the bacterial species examined. The numbers of viable cells in the biofilms were significantly decreased with atrophic changes in bacterial cells and biofilm density.²⁸⁵ When an Nd:YAG laser was used to kill microorganisms seeded on dentin discs with three endodontic pathogens, bacterial eradication occurred. However, when microcolonies were found in biofilms, bacterial eradication was reduced.

Erbium/Chromium-Doped Yttrium Scandium Gallium Garnet Lasers

The Nd:YAG system was found to be more effective than the Er,Cr:YSGG laser, with the former demonstrating a reduction of 97% and 98% of organisms.⁴¹⁷ Researchers⁹⁴ found the Er,Cr:YSGG system to be less effective than a 3% solution of NaOCl, with the latter inhibiting growth of *E. faecalis* in all root canal systems tested. A later study found that the same system eliminated bacteria and smear layer debris in root canals, with only moderate elevation of temperature on the outer root surfaces.³³⁶ Others have demonstrated the same results when comparing the Er,Cr:YSGG system to NaOCl, using a radically emitting laser probe for 2 minutes; 99.7% bacterial reduction occurred with the laser.¹⁴² A high-powered 810-nm diode laser was used to examine the ability to achieve

disinfection in deep layers of dentin. A group of 10 extracted teeth were treated with rotary files, 0.5% NaOCl, 17% EDTA, and irradiated, with a second group treated the same but without laser exposure. A third group was treated only with saline irrigation. Results showed 100% and 98.3% disinfection when compared with the control group.⁸⁶ However, few of the investigators cited were willing to call the effects *sterilization* as opposed to *disinfection*. There are also differences in results that appear to be dependent on wavelength. *Therefore, the use of lasers still remains somewhat controversial for use in sterilization of root canal systems.*

Laser irradiation has been used in the preparation of root-end restorations. The root-end areas prepared with burs expose dentinal tubules, which may allow leakage of microorganisms and their byproducts. When preparations using an Er:YAG laser were compared to an Nd:YAG laser and high-speed burs, the lasers demonstrated lower infiltration indices than high-speed burs.²⁸⁷ In a similar study, results determined that a transversely excited atmospheric pressure (TEA) CO₂ laser and an Er:YAG laser showed clean, smooth root-end preparation surfaces with sealed tubules and a reduction of permeability to methylene blue dye.¹⁴³ An Er:YAG laser was compared to root-end ultrasonic preparation using three filling materials (MTA, Super EBA, IRM). The laser-treated areas demonstrated lower microleakage values for all three materials.¹⁸⁸ When comparing use of a low-speed bur and an Er,Cr:YSGG laser for reverse root-end preparations using cyanoacrylate and MTA as filling materials, MTA and laser samples presented significantly higher permeability rates.⁴²⁶ Alternating Er:YAG and Nd:YAG irradiation preparations with high-speed hand piece preparation showed no differences between either group exposed to lasers and no differences between bur preparations in microleakage percentages.¹³ Diode lasers are available at much lower costs than other systems and can also be used for root-end preparations. Groups treated with a 980-nm laser were compared to non-laser groups, demonstrating absence of smear layer and reduced leakage when compared with nonlased teeth.⁴¹⁸ However, *when used in combination with MTA for reverse filling, the laser radiation did not improve apical sealing.*⁸⁷

Laser energy may prove useful for treating diseases of the root canal system and periradicular regions, but years of successful endodontic care have demonstrated the value of several already proven methods. Until independently supported, reproducible studies are published in peer-reviewed journals—wherein findings match present marketing claims—the reader is advised to exercise prudent caution before embracing these newer laser technologies.

SUMMARY

An explosion in knowledge and technology has created an exciting time in the specialty of endodontics. New instruments and materials seem to appear faster than clinicians can learn about the preceding versions. This has created an educational challenge for practitioners, universities, and manufacturers, requiring a greater degree of cooperation among these groups than ever before. Clinicians should only use those instruments and materials that have been shown safe and effective by independent studies.

*References 33, 108, 111, 112, 124, 125, and 366.

REFERENCES

1. Abbott PV, Hethersay GS, Hume WR: Release and diffusion through human tooth roots in vitro of corticosteroid and tetracycline trace molecules from Ledennix® paste. *Endod Dent Traumatol* 4:55-62, 1988.
2. Abbott PV, Hume WR, Hethersay GS: Barriers to diffusion of Ledennix® paste in radicular dentine. *Endod Dent Traumatol* 5:98, 1989.
3. Abbott PV, Hume WR, Hethersay GS: Effects of combining Ledennix® and calcium hydroxide pastes on the diffusion of corticosteroid and tetracycline through human tooth roots in vitro. *Endod Dent Traumatol* 5:188, 1989.
4. Accorinte ML, Loguerico AD, Reis A, Costa CA: Response of human pulps capped with different self-etch adhesive systems. *Clin Oral Invest* 12:119, 2008.
5. Ahmad M: An analysis of breakage of ultrasonic files during root canal instrumentation. *Endod Dent Traumatol* 5:78, 1989.
6. Ahmad M, Pitt-Ford TR, Crum LA: Ultrasonic debridement of root canals: acoustic streaming and its possible role. *J Endod* 13:490, 1987.
7. Ahmad M, Roy RA, Ghanikamarudin A, Safar M: The vibratory pattern of ultrasonic files driven piezoelectrically. *Int Endod J* 26:120, 1992.
8. Al-Awadhi S, Spears R, Gutmann JL, Opperman LA: Cultured primary odontoblast viability and apoptosis in the presence of root canal sealers. *J Endod* 30:527, 2004.
9. Alfredo E, Silva SR, Ozbrio JE, Souza-Neto MD, Brugnera-Junior A, Silva-Sousa YT: Bond strength of AH Plus and Epiphany. *Int Endod J* 41:733, 2008.
10. Andersen M, Lund A, Andreassen JO, Andreassen FM: In vitro solubility of human pulp tissue in calcium hydroxide and sodium hypochlorite. *Endod Dent Traumatol* 8:104, 1992.
11. Anjo T, Ebihara A, Takeda A, Takashima M, Sunakawa M, Suda H: Removal of two types of root canal filling material using pulsed Nd:YAG laser irradiation. *Photomed Laser Surg* 22: 470, 2004.
12. Archer R, Reader A, Nist R, Beck M, Meyers WJ: An in vivo evaluation of the efficacy of ultrasound after step-back preparation in mandibular molars. *J Endod* 18:549, 1992.
13. Arisu HD, Sadik B, Bala O, Turkoz E: Computer assisted evaluation of microleakage after apical resection with laser and conventional techniques. *Laser Med Sci* 23:415, 2008.
14. Asboe-Jorgensen V, Attstrom R, Lang NP, Loe H: Effect of a chlorhexidine dressing on the healing after periodontal surgery. *J Periodontol* 45:13, 1974.
15. Autegard JE, Pecquet C, Huet S, Bayrou O, Leynadier F: Anaphylactic shock after application of chlorhexidine to unbroken skin. *Contact Dermatitis* 40:215, 1999.
16. Azar NG, Heidari M, Bahrami ZS, Shokri F: In vitro cytotoxicity of a new epoxy resin root canal sealer. *J Endod* 26:462, 2000.
17. Azarpazhooh A, Limeback H: The application of ozone in dentistry: A systematic review of literature. *J Dent* 36:104, 2008.
18. Balto H: An assessment of microbial coronal leakage of temporary filling material in endodontically treated teeth. *J Endod* 28:762, 2002.
19. Balto H, Al-Nazha N, Al-Mansour K, Al-Otaibi M, Siddiqui Y: Microbial leakage of Cavit, IRM, and Temp Bond in post-prepared root canals using two methods of gutta-percha removal: an invitro study. *J Contemp Dent Pract* 6:53, 2005.
20. Barbosa CA, Goncalves RB, Siqueira JF, Jr., De Uzeda M: Evaluation of the antibacterial activities of calcium hydroxide, chlorhexidine, and camphorated paramonochlorophenol as intracanal medicament. A clinical and laboratory study. *J Endod* 23:297, 1997.
21. Barbosa SV, Burkard DH, Spångberg SW: Cytotoxic effects of gutta-percha solvents. *Pediatr Dent* 16:102, 1994.
22. Barkhordar RA, Kempler D: A comparison between xeroradiography and conventional radiography in the diagnosis of endodontic lesions. *Oral Surg Oral Med Oral Pathol* 66:489, 1988.
23. Barthel CR, Zimmer S, West G, Roulet JF: Bacterial leakage in obturated root canals following the use of different intracanal medicaments. *Endod Dent Traumatol* 16:282, 2000.
24. Basrani B, Ghanem A, Tjäderhane L: Physical and chemical properties of chlorhexidine and calcium hydroxide-containing medications. *J Endod* 30:413, 2004.
25. Basrani B, Lemonie C: Chlorhexidine gluconate. *Aust Endod J* 31:48, 2005.
26. Basrani B, Manek S, Sodhi R, Fillery E, Manzur A: Interaction between sodium hypochlorite and chlorhexidine gluconate. *J Endod* 33:966, 2007.
27. Basrani B, Santos JM, Tjäderhane L, et al: Substantive antimicrobial activity in chlorhexidine-treated human root dentin. *Oral Surg Oral Med Oral Pathol Oral Radiol Endod* 94:240, 2002.
28. Basrani B, Tjäderhane L, Santos JM, et al: Efficacy of chlorhexidine- and calcium hydroxide-containing medications against *Enterococcus faecalis* in vitro. *Oral Surg Oral Med Oral Pathol Oral Radiol Endod* 96:618, 2003.
29. Baumgartner JC, Johal S, Marshall JG: Comparison of the antimicrobial efficacy of 1.3% NaOCl/Biopure MTAD to 5.25% NaOCl/15% EDTA for root canal irrigation. *J Endod* 33:48, 2007.
30. Beach CW, Bramwell JD, Hutter JW: Use of an electronic apex locator on a cardiac pacemaker patient. *J Endod* 22:182, 1996.
31. Beltz RE, Torabinejad M, Poursmail M: Quantitative analysis of the solubilizing action of MTAD, sodium hypochlorite, and EDTA on bovine pulp and dentin. *J Endod* 29:334, 2003.
32. Bender IB, Landau MA, Fonsecca S, Trowbridge HO: The optimum placement-site of the electrode in electric pulp testing of the 12 anterior teeth. *J Am Dent Assoc* 118:305-310, 1989.
33. Bergmans L, Moisiadis P, Huybrechts B, Van Meerbeek B, Quirynen M, Lambrechts P: Effect of photo-activated disinfection on endodontic pathogens ex vivo. *Int Endod J* 41:227, 2008.
34. Bernath M, Szabo J: Tissue reaction initiated by different sealers. *Int Endod J* 36:256, 2003.
35. Bodrumlu E, Alacam T: Evaluation of antimicrobial effects of iodoform-integrating gutta-percha. *J Can Dent Assoc* 72:733, 2006.
36. Bodrumlu E, Alacam T, Semiz M: The antimicrobial and antifungal efficacy of tetracycline-integrated gutta-percha. *Indian J Dent Res* 19:112, 2008.
37. Bodrumlu E, Muglali M, Sumer M, Guvenç T: The response of subcutaneous connective tissue to a new filling material. *J Biomed Mater Res B Appl Biomater* 84:463, 2008.
38. Bodrumlu E, Tonga U: The apical sealing ability of a new root canal filling material. *Am J Dent* 20:295, 2007.
39. Bodrumlu E, Uzam O, Topuz O, Semiz M: Efficacy of 3 techniques in removing root canal filling material. *J Can Dent Assoc* 74:721, 2008.
40. Bortnick KL, Steiman HR, Ruskin A: Comparison of nickel-titanium file distortion using electric and air-driven handpieces. *J Endod* 27:57, 2001.
41. Bouillaguet S, Shaw L, Barthelemy J, Krejci I, Wataha JC: Long-term sealing ability of Pulp Canal Sealer, AH-Plus, GuttaFlow and Epiphany. *Int Endod J* 41:219, 2008.
42. Bozza FL, Molgattini SL, Perez SB, Tejerin DP, Perez Tito RI, Kaplan AE: Antimicrobial effect in vitro of chlorhexidine and calcium hydroxide impregnated gutta-percha points. *Acta Odontol Latinoam* 18:51, 2005.
43. Brise o-Marroquin B, El-Syed MAA, Willershausen-Zonnchen B: Morphology of the physiological foramen: I. Maxillary and mandibular molars. *J Endod* 30:321, 2004.
44. Brown BDK, Kafrawy AH, Patterson SS: Studies of Sargenti technique of endodontics: autoradiographic and scanning electron microscope studies. *J Endod* 5:14, 1979.
45. Brugnera A, Zanin F, Barbin EL, Spano JC, Santana R, Pecora JD: Effect of Er:YAG and Nd:YAG laser irradiation on radicular dentine permeability using different irrigating solutions. *Lasers Surg Med* 33:256, 2003.
46. Byström A, Claesson R, Sundqvist G: The antimicrobial effect of camphorated paramono-chlorphenol, camphorated phenol, and calcium hydroxide in the treatment of infected root canals. *Endod Dent Traumatol* 1:170, 1985.
47. Byström A, Sundqvist G: Bacteriologic evaluation of the effect of 0.5 percent sodium hypochlorite in endodontic therapy. *Oral Surg Oral Med Oral Pathol* 55:307, 1983.
48. Byström A, Sundqvist G: The antibacterial action of sodium hypochlorite and EDTA in 60 cases of endodontic therapy. *Int Endod J* 18:35, 1985.
49. Cabral CT, Fernandes MH: In vitro comparison of chlorhexidine and povidone-iodine on the long-term proliferation and functional activity of human alveolar bone cells. *Clin Oral Invest* 11:155, 2007.
50. Calan J: The use of inert plastic material in reconstructive surgery. *Br J Plast Surg* 16:1, 1963.
51. Camps J, Pashley D: Reliability of the dye penetration studies. *J Endod* 29:592, 2003.
52. Canadian Center for Occupational Health and Safety, ChemInfo, Record 728, 1994.
53. Carrilho MR, Carvalho RM, De Goes MF, et al: Chlorhexidine preserves dentine bond in vitro. *J Dent Res* 86:90, 2007.
54. Carrilho MR, Carvalho RM, Tay FR, Yiu C, Pashley DH: Durability of resin-dentin bonds related to water and oil storage. *Am J Dent* 18:315, 2005.
55. Carvalho CA, Valera MC, Gown-Soares S, dePaula Eduardo C: Effects of Nd:YAG and Er:YAG lasers on the sealing of root canal fillings. *J Clin Laser Med Surg* 20:215, 2002.
56. Caso A, Hung LK, Beirne OR: Prevention of alveolar osteitis with chlorhexidine: A meta-analytic review. *Oral Surg Oral Med Oral Pathol Oral Radiol Endod* 99:155, 2005.
57. Chen H, Teixeira FB, Ritter AL, Levin L, Trope M: The effect of intracanal anti-inflammatory medicaments on external root resorption of replanted dog teeth after extended extra-oral dry time. *Dent Traumatol* 24:74, 2008.
58. Cheung GS, Stock CJ: In vitro cleaning ability of root canal irrigants with and without endosonics. *Int Endod J* 26:334, 1993.
59. Chogle S, Mickel AK, Huffaker SK, Neibaur B: An in vitro assessment of iodoform gutta-percha. *J Endod* 31:814, 2005.
60. Chutich MJ, Kaminski EJ, Miller DA, Lautenschlager EP: Risk management of the toxicity of gutta-percha used in endodontic retreatment. *J Endod* 24:213, 1998.
61. Cobankara FK, Altinoz HC, Ergani O, Kav K, Belli S: In vitro antibacterial activities of root canal sealers using two different methods. *J Endod* 30:57, 2004.
62. Cohen BD, Combe ED, Lilley JD: Effects of thermal placement techniques on some physical properties of gutta-percha. *Int Endod J* 25:292, 1992.
63. Cohen BI, Pagnillo MK, Musikant BL, Deutsch AS: Formaldehyde evaluation from endodontic materials. *Oral Health* 88(12):37-39, 1998 Dec.
64. Cooley RL, Robison SF: Variables associated with electric pulp testing. *Oral Surg Oral Med Oral Pathol* 50:66, 1980.
65. Coronal Leakage: Clinical and Biological Implications, Endodontics: Colleagues for Excellence, American Association of Endodontics, Fall/Winter 2002.
66. Cotti E, Campisi G, Garau V, Puddu G: A new technique for the study of peripical bone lesions: Ultrasound real-time imaging. *Int Endod J* 35:142, 2002.
67. Cotton TP, Geisler TM, Holden DT, Schwartz SA, Schindler WG: Endodontic applications of cone 381 beam volumetric tomography. *J Endod* 33:1121, 2007.
68. Cunningham WT, Martin H: A scanning electron microscope evaluation of root canal debridement with the endo-sonic ultrasonic synergistic system. *Oral Surg Oral Med Oral Pathol* 53:527, 1982.

69. Dalat DM, Spångberg LSW: Comparison of apical leakage in root canals obturated with various gutta-percha techniques using a dye vacuum tracing method. *J Endod* 20:315, 1994.
70. Dammaschke T, Schneider U, Stratmann U, Yoo JM, Schafer E: Effect of root canal dressings on the regeneration of inflamed periapical tissue. *Acta Odontol Scand* 63:143, 2005.
71. Daugherty DW, Gound TG, Comer TL: Comparison of fracture rate, deformation rate, and efficiency between rotary endodontic instruments driven at 150 rpm and 350 rpm. *J Endod* 27:93, 2001.
72. Davies A: The mode of action of chlorhexidine. *J Periodontol Res* 12(Suppl):68, 1973.
73. Davis JM, Maki J, Bahcall JK: An in vitro comparison of the antimicrobial effects of various endodontic medications on *Enterococcus faecalis*. *J Endod* 33:567, 2007.
74. Decosta Rebeiro A, Nogueira GE, Antoniazzi JH, Moritz A, Zezell DM: Effects of diode lasers (810 nm) irradiation on root canal walls: Thermographic and morphological studies. *J Endod* 33:252, 2007.
75. De-Deus G, Brandao MC, Fidel RA, Fidel SR: The sealing ability of GuttaFlow in oval-shaped canals: an ex vivo study using polymicrobial leakage model. *Int Endod J* 40:794, 2007.
76. De-Deus G, Gurgel-Filho ED, Magalhaes KM, Coutinho-Filho T: A laboratory analysis of gutta-percha filled area obtained using Thermafil, System B and lateral condensation. *Int Endod J* 39:378, 2006.
77. De Gee AJ, Wu MK, Wesselink PR: Sealing properties of a Ketac-Endon glass ionomer cement an AH26 root canal sealer. *Int Endod J* 27:239, 1994.
78. Delany GM, Patterson SS, Miller CH, Newton CW: The effect of chlorhexidine gluconate irrigation on the root canal flora of freshly extracted necrotic teeth. *Oral Surg Oral Med Oral Pathol* 53:518, 1982.
79. deMoura-Netto C, deMoura AA, Davidowicz H, Aun CE, Antonio MP: Morphologic changes and removal of debris on apical dentin surfaces after Nd:YAG laser and diode laser irradiation. *Photomed Laser Surg* 26:263, 2008.
80. De Munck J, Van Landuyt K, Peumans M, et al: A critical review of the durability of adhesion to tooth tissue: methods and results. *J Dent Res* 84:118, 2005.
81. Denton G: Chlorhexidine. In Block SS, editor: *Disinfection, Sterilization and Preservation*, 4th ed. Philadelphia, 1991, Lea & Febiger.
82. Depraet FJ, DeBruyne MA, DeMoor RJ: The sealing ability of an epoxy root canal sealer of Nd:YAG laser irradiation. *Int Endod J* 38:302, 2005.
83. De Rossi A, Silva LA, Leonardo MR, Rocha LB, Rossi MA: Effect of rotary or manual instrumentation, with or without a calcium hydroxide, 1% chlorhexidine intracanal dressing, on the healing of experimentally induced chronic periapical lesions. *Oral Surg Oral Med Oral Pathol Oral Radiol Endod* 99:628, 2005.
84. Desai P, Himel V: Comparative safety of various intracanal irrigation systems. *J Endod* 35:545, 2009.
85. Desai S, Chandler N: Calcium hydroxide-based root canal sealers: a review. *J Endod* 35:475, 2009.
86. DeSouza EB, Cai S, Simionato MR, Lage-Marques JL: High power diode laser in a disinfection in depth of the root canal dentin. *Oral Surg Oral Med Oral Pathol* 106:e68, 2008.
87. DeSouza EB, deAmorim CV, Marques JL: Effect of diode laser irradiation on the apical sealing of MTA retrofills. *Braz Oral Res* 20:231, 2006.
88. Deveaux E, Hildebert P, Neut C, Romond C: Bacterial micro-leakage of Cavit, IRM, TERM, and Fermit: A 21-day in vitro study. *J Endod* 25:653, 1999.
89. Donley DL, Weller RN, Kulild JC, Jucak JJ: In vitro intracanal temperatures produced by low- and high temperature thermoplasticized injectible gutta-percha. *J Endod* 17:307, 1991.
90. Dove SB, McDavid WD, Hamilton KE: Analysis of sensitivity and specificity of a new digital conventional radiography and computed tomography. *Oral Surg Oral Med Oral Pathol Oral Radiol Endod* 92:682, 2001.
91. Ebihara A, Majaron B, Liaw LL, Krasieva TB, Wilder-Smith P: Er:YAG laser modification of root canal dentine: influence of pulse duration, repetitive irradiation and water spray. *Laser Med Sci* 17:198, 2002.
92. Ebo DG, Stevens WJ, Bridts CH, Matthieu L: Contact allergic dermatitis and life-threatening anaphylaxis to chlorhexidine. *J Allergy Clin Immunol* 101:128, 1998.
93. Ehrmann EH: Pulp testers and pulp testing with particular reference to the use of dry ice. *Aust Dent J* 22:272, 1977.
94. Eideniz AU, Ozer F, Hadimli HH, Erganis O: Bacterial efficacy of Er, Cr:YSGG laser irradiation against *Enterococcus faecalis* compared with NaOCl irrigation: an ex vivo pilot study. *Int Endod J* 40:112, 2007.
95. El Ayouti A, Weiger R, Löst C: The ability of Root ZX apex locator to reduce the frequency of overestimated radiographic working length. *J Endod* 28:116, 2002.
96. Ellerbruch ES, Murphy RA: Antimicrobial activity of root canal medicament vapors. *J Endod* 3:189, 1977.
97. Emilson CG, Ericson T, Heyden G, Magnusson BC: Uptake of chlorhexidine to hydroxyapatite. *J Periodontol Res* 12(Suppl):17, 1973.
98. Ercan E, Dallı M, Duulgerli CT, Yaman F: Effect of intracanal medication with calcium hydroxide and 1% chlorhexidine in endodontic retreatment cases with periapical lesions: An in vivo study. *J Formos Med Assoc* 106:217, 2007.
99. Ercan E, Ozekinci T, Atakul F, Gul K: Antibacterial activity of 2% chlorhexidine gluconate and 5.25% sodium hypochlorite in infected root canal: in vivo study. *J Endod* 30:84, 2004.
100. Estrela C, Estrela CRA, Decurcio DA, Hollanda ACB, Silva JA: Antimicrobial efficacy of Ozonated Water, Gaseous Ozone, Sodium Hypochlorite And Chlorhexidine In Infected human root canals. *Int Endod J* 40:85, 2007.
101. Eun HC, Lee AY, Lee YS: Sodium hypochlorite dermatitis. *Contact Dermatitis* 11:45, 1984.
102. Evans MD, Baumgartner JC, Khemaleelakul SU, Xia T: Efficacy of calcium hydroxide: chlorhexidine paste as an intracanal medication in bovine dentin. *J Endod* 29:338, 2003.
103. Fanibunda KB: The feasibility of temperature measurement as a diagnostic procedure in human teeth. *J Dent* 14:126, 1986.
104. Fardal O, Turnbull RS: A review of the literature on use of chlorhexidine in dentistry. *J Am Dent Assoc* 112:863, 1986.
105. Faria G, Celes MR, De Rossi A, Silva LA, Silva JS, Rossi MA: Evaluation of chlorhexidine toxicity injected in the paw of mice and added to cultured L929 fibroblasts. *J Endod* 33:715, 2007.
106. Faria MI, Souza-Gabriel Ae, Marchesan MA, Sousa-Neto MD, Silva-Sousa YT: Ultrastructural evaluation of radicular dentin after Nd:YAG irradiation combined with different chemical substances. *Gen Dent* 56:641, 2008.
107. Fernandes AM, Silva GA, Lopes N Jr., Napimoga MH, Benatti BB, Alves JB: Direct capping of human pulps with a dentin bonding system and calcium hydroxide: an immunohistochemical analysis. *Oral Surg Oral Med Oral Pathol Oral Radiol Endod* 105:385, 2008.
108. Fimple JL, Fontana CR, Foschi F, et al: ••• *J Endod* 34:728, 2008.
109. Folk RB, Thorpe JR, McClanahan SB, Johnson JD, Strother JM: Comparison of two different direct digital radiography systems for the ability to detect artificially prepared periapical lesions. *J Endod* 31:304, 2005.
110. Folwaczny M, Mehl A, Jordan C, Hickel R: Antibacterial effect of pulsed Nd:YAG laser radiation at different energy settings in the root canals. *J Endod* 28:24, 2002.
111. Fonseca MB, Junior PO, Pallota RC, et al: Photodynamic therapy for root canals in fected with *Enterococcus faecalis*. *Photomed Laser Surg* 26:209, 2008.
112. Foschi F, Fontana CR, Ruggiero K, et al: Photodynamic inactivation of *Enterococcus faecalis* in dental root canals in vitro. *Las Surg Med* 39:782, 2007.
113. Fouad AF, Hopson JR, Martins JB, Krell KV, Drews TA, Jensen ME: Effects of selected electronic dental instruments on patients with cardiac pacemakers. *J Endod* 16:188, 1990.
114. Fouad AF, Krell KV, McKendry DJ, Koorbusch GF, Olson RA: A clinical evaluation of five electronic root canal length measuring instruments. *J Endod* 16:446, 1990.
115. Fouad AF, Reid LC: Effect of using electronic apex locators on selected endodontic treatment parameters. *J Endod* 26:364, 2000.
116. Fraiss S, Ng Y-L, Gulabivala K: Some factors affecting the concentration of commercially available sources of sodium hypochlorite. *Int Endod J* 34:206, 2001.
117. Frankenberger R, Pashley DH, Reich SM, Lohbauer U, Petschelt A, Tay FR: Characterisation of resin-dentine interfaces by compressive cyclic loading. *Biomaterials* 26:2043, 2005.
118. Friedman J, Marcus MI: Transillumination of the oral cavity with use of fiber optics. *J Am Dent Assoc* 80:801, 1970.
119. Fukumoto Y: Intracanal aspiration technique for root canal irrigation: Evaluation of smear layer removal (in Japanese). *Kokubyo Gakkai Zasshi* 72:13, 2005.
120. Fukumoto Y, Kikuchi I, Yoshioka T, Kobayashi C, Suda H: An ex vivo evaluation of a new root canal irrigation technique with intracanal aspiration. *Int Endod J* 39:93, 2006.
121. Fuss Z, Trowbridge H, Bender IB, Rickoff B, Sorin S: Assessment of reliability of electrical and thermal pulp testing agents. *J Endod* 12:301, 1986.
122. Gabel WP, Hoen M, Steiman HR, Pink FE, Dietz R: Effect of rotational speed on nickel-titanium file distortion. *J Endod* 25:752, 1999.
123. Gambarini G, Pongione G, Rizzo F, Testarelli L, Cavalleri G, Gerosa R: Bending properties of nickel-titanium instruments: a comparative study. *Minerva Stomatol* 57:393, 2008.
124. Garcez AS, Nunez SC, Hamblin MR, Ribeiro MS: Antimicrobial effects of photodynamic therapy on patients with necrotic pulps and periapical lesions. *J Endod* 34:138, 2008.
125. Garcez AS, Ribeiro MS, Trope MS, et al: Antimicrobial therapy combined with conventional endodontic treatment to eliminate root canal biofilm infection. *Lasers Surg Med* 39:59, 2007.
126. Garofalo RR, Ede EN, Dorn SO, Kuttler S: Effect of electronic apex locators on cardiac pacemaker function. *J Endod* 28:831, 2002.
127. Garvey LH, Roed-Petersen J, Husum B: Anaphylactic reactions in anaesthetized patients—Four cases of chlorhexidine allergy. *Acta Anaesthesiol Scand* 45:1290, 2001.
128. Gatewood RS, Himel VT, Dorn SO: Treatment of the endodontic emergency: A decade later. *J Endod* 16:284, 1990.
129. Gazelius B, Edwall B, Olgart L, Lundberg JM, Hokfelt T, Fisher JA: Vasodilatory effects and coexistence of calcitonin gene-related peptide (CGRP) and substance P in sensory nerves of cat dental pulp. *Acta Physiol Scand* 130:33, 1987.
130. Gazelius B, Olgart L, Edwall B, Edwall L: Non-invasive recording of blood flow in human dental pulp. *Endod Dent Traumatol* 2:219, 1986.
131. George R, Meyers IA, Walsh LJ: Laser activation of endodontic irrigants with improved conical laser fiber tips for removing smear layer with apical third of the root canal. *J Endod* 34:1524, 2008.
132. Ghorri S, Gulabivala K, Premdas C, Spratt DA: Evaluation of the antimicrobial efficacy of electrochemically activated water on selected isolates from the root canal. *Int Endod J* 35:85, 2002.
133. Giardino L, Ambu E, Becce C, Rimondini L, Morra M: Surface tension comparison of four common root canal irrigants and two new irrigants containing antibiotic. *J Endod* 32:1091, 2006.
134. Giardino L, Ambu E, Savoldi E, Rimondini R, Cassanelli C, Debbia EA: Comparative evaluation of antimicrobial efficacy of sodium hypochlorite, MTAD, and tetraclean against *Enterococcus faecalis* biofilm. *J Endod* 33:852, 2007.

135. Goldberg F, De Silvio AC, Manfré S, Nastri N: In vitro measurement accuracy of an electronic apex locator in teeth with simulated apical root resorption. *J Endod* 28:461, 2002.
136. Goldman M, Kronman JH, Goldman LB, Clausen H, Grady J: New method of irrigation during endodontic treatment. *J Endod* 2:257, 1976.
137. Gomes BP, Ferraz CC, Vianna ME, Berber VB, Teixeira FB, Souza-Filho FJ: In vitro antimicrobial activity of several concentrations of sodium hypochlorite and chlorhexidine gluconate in the elimination of *Enterococcus faecalis*. *Int Endod J* 34:424, 2001.
138. Gomes BP, Sato E, Ferraz CC, Teixeira FB, Zaia AA, Souza-Filho FJ: Evaluation of time required for recontamination of coronally sealed canals medicated with calcium hydroxide and chlorhexidine. *Int Endod J* 36:604–609, 2003.
139. Goodman A, Schilder H, Aldrich W: The thermomechanical properties of gutta-percha II. *Oral Surg Oral Med Oral Pathol* 37:954, 1974.
140. Gopikrishna V, Pradeep G, Venkateshbabu N: Assessment of pulp vitality: A review. *Int J Paediatr Dent* 19:3, 2009.
141. Gordon MP, Chandler NP: Electronic apex locators. *Int Endod J* 37:425, 2004.
142. Gordon W, Atabakhsh VA, Meza F, et al: The antimicrobial efficacy of the erbium, chromium: yttrium-scandium-gallium-garnet laser with radial emitting tips on root canal dentin walls infected with *Enterococcus faecalis*. *J Am Dent Assoc* 138:992, 2007.
143. Gouw-Soares S, Staboltz A, Lage-Marques JL, Zezell DM, Groth EB, Edwardo CP: Comparative study of dentine permeability after apicoectomy and surface treatment with 9.6 micron TEA CO₂ and Er:YAG laser irradiation. *J Clin Laser Med Surg* 22:129, 2004.
144. Goya C, Yamazaki R, Tomita Y, Kimura Y, Matsumoto K: Effects of pulsed Nd:YAG irradiation on smear layer at the apical stop and apical leakage after obturation. *Int Endod J* 33:266, 2000.
145. Grassi MD, Plazek DJ, Michanowicz AE, Chay IC: Changes in the physical properties of the ultrafil low temperature (70 degrees C) thermoplasticized gutta-percha system. *J Endod* 15:517, 1989.
146. Grawehr M, Sener B, Waltimo T, Zehnder M: Interactions of ethylenediamine tetraacetic acid with sodium hypochlorite in aqueous solutions. *Int Endod J* 36:411, 2003.
147. Greenstein G, Berman C, Jaffin R: Chlorhexidine. An adjunct to periodontal therapy. *J Periodontol* 57:370, 1986.
148. Grossman LI: Solubility of root canal cements. *J Dent Res* 57:927, 1978.
149. Grossman LI: Clinical diagnostic methods. In Grossman LI, editor: *Endodontic Practice*, 10th ed, Philadelphia, PA, 1981, Lea & Febiger, pp 17–22.
150. Grossman LI, Meiman BW: Solution of pulp tissue by chemical agent. *J Am Dent Assoc* 28:223, 1941.
151. Gulabivala K, personal communication, 2009.
152. Gulabivala K, Stock CJ, Lewsey JD, Ghori S, Ng YL, Spratt DA: Effectiveness of electrochemically activated water as an irrigant in an infected tooth model. *Int Endod J* 37:624, 2004.
153. Gundappa M, Ng SY, Whaites EJ: Comparison of ultrasound, digital and conventional radiography in the differentiation of periapical lesions. *Dentomaxillofac Radiol* 35:326, 2006.
154. Gurbuz T, Ozdemir Y, Kara N, Zehir C, Kurudirek M: Evaluation of root canal dentin after Nd:YAG laser irradiation and treatment with five different irrigation solutions: a preliminary study. *J Endod* 30:318, 2008.
155. Haapasalo HK, Siren EK, Waltimo TM, Orstavik D, Haapasalo MP: Inactivation of local root canal medicaments by dentine: An in vitro study. *Int Endod J* 33:126, 2000.
156. Habets JM, Geursen-Reitsma AM, Stolz E, Van Joost T: Sensitization to sodium hypochlorite causing hand dermatitis. *Contact Dermatitis* 15:140, 1986.
157. Haenni S, Schmidlin PR, Mueller B, Sener B, Zehnder M: Chemical and antimicrobial properties of calcium hydroxide mixed with irrigating solutions. *Int Endod J* 36:100, 2003.
158. Haikel Y, Gasser P, Allemann C: Dynamic fracture of hybrid endodontic hand instruments compared with traditional files. *J Endod* 17:217, 1991.
159. Hamblin MR, Hasan T: Photodynamic therapy: A new antimicrobial approach to infectious disease. *Photochem Photobiol Sciences* 3:436, 2004.
160. Hammad M, Qualtrough A, Silikas N: Effect of new obturating materials on vertical root fracture resistance of endodontically treated teeth. *J Endod* 33(6):732–736, 2007 Jun (Epub 2007 Apr 16).
161. Hasselgren G, Olsson B, Cvek M: Effects of calcium hydroxide and sodium hypochlorite on the dissolution of necrotic porcine muscle tissue. *J Endod* 14:125, 1988.
162. Hata G, Hayami S, Weine FS, Toda T: Effectiveness of oxidative potential water as a root canal irrigant. *Int Endod J* 34:308, 2001.
163. Haznedaroglu F, Ersev H: Tetracycline HCl solution as a root canal irrigant. *J Endod* 27:738, 2001.
164. Hems RS, Gulabivala K, Ng YL, Ready D, Spratt DA: An in vitro evaluation of the ability of ozone to kill a strain of *Enterococcus faecalis*. *Int Endod J* 38:22, 2005.
165. Hennessey TS: Some antibacterial properties of chlorhexidine. *J Periodontol Res* 12(Suppl):61, 1973.
166. Hermann BW: *Calciumhydroxyd als mittel zum behandel und füllen von zahnwurzelkanälen*, Dissertation, Germany, 1920, University of Würzburg, *Med Diss V*.
167. Hermann BW: Dentin obliteration der wurzelkanäle nach behandlung mit calcium. *Zahnärztl Rundschau* 39:888, 1930.
168. Hidalgo E, Dominguez C: Mechanisms underlying chlorhexidine-induced cytotoxicity. *Toxicol In Vitro* 15:271, 2001.
169. Hjeljord LG, Rolla G, Bonesvoll P: Chlorhexidine-protein interactions. *J Periodontol Res* 12(Suppl):11, 1973.
170. Holland G, Walton R: Diagnosis and treatment planning. In Torabinejad M, Walton R: *Endodontics: Principles and Practice*, ed 4, St. Louis, 2009, Saunders.
171. Holloway GA: Laser doppler measurement of cutaneous blood flow. In Rolfe P, editor: *Non-invasive Physiological Measurements*. London, 1983, Academic Press Inc., pp 11.
172. Horiba N, Hiratsuka K, Onoe T, et al: Bactericidal effect of electrolysed neutral water on bacteria isolated from infected root canals. *Oral Surg Oral Med Oral Pathol Oral Radiol Endod* 87:83, 1999.
173. Howell RM, Duell RC, Mullaney TP: The determination of pulp vitality by thermographic means using cholesteric liquid crystals. *Oral Surg Oral Med Oral Pathol* 29:763, 1970.
174. Hsieh YD, Gau CH, Kung Wu SF, Shen EC, Hsu PW, Fu E: Dynamic recording of irrigating fluid distribution in root canals using thermal image analysis. *Int Endod J* 40:11, 2007.
175. Huang FM, Chang YC: Prevention of the epoxy resin-based root canal sealer-infused cyclooxygenase-2 expression and cytotoxicity of human osteoblast cells by various antioxidants. *Biomaterials* 26:1849, 2005.
176. Huang FM, Tai KW, Chou MY, Chang YC: Cytotoxicity of resin-, zinc oxide-eugenol-, and calcium hydroxide- based root canal sealers on human periodontal ligament cells and permanent V79 cells. *Int Endod J* 35:153, 2002.
177. Hugh CL, Walton RE, Facer SR: Evaluation of intracanal sealer distribution with 5 different obturation techniques. *Quintessence Int* 36:712, 2005.
178. Hugo WB, Longworth AR: The effect of chlorhexidine on the electrophoretic mobility, cytoplasmic constituents, dehydrogenase activity and cell walls of *Escherichia coli* and *Staphylococcus aureus*. *J Pharm Pharmacol* 18:569, 1966.
179. Hugo WB, Longworth ARL: Some aspects of the mode of action of chlorhexidine. *J Pharm Pharmacol* 16:655, 1964.
180. Hülsmann M, Pieper K: Use of an electronic apex locator in the treatment of teeth with incomplete root formation. *Endod Dent Traumatol* 5:238, 1989.
181. Hülsmann M, Rödiger T, Nordmeyer S: Complications during root canal irrigation. *Endod Topics* 16:27, 2007.
182. Ishaq H, Sandeep M, Kulkarni S, Yakub SS: Evaluation of fracture resistance in simulated immature teeth using Resilon and Ribbond as root reinforcements—An in vitro study. *Dent Traumatol* 25:433–438, 2009.
183. Ichikawa K, Nakamura HK, Ogawa N, Sakimura T, Kuroda M: R&D of long-term life-support system by using electrochemically activated biofilm reactor of aquatic animals for space examinations. *Biological Science in Space* 13:348, 1999.
184. Jeansonne MJ, White RR: A comparison of 2.0% chlorhexidine gluconate and 5.25% sodium hypochlorite as antimicrobial endodontic irrigants. *J Endod* 20:276, 1994.
185. Jha D, Guerrero A, Ngo T, Helfer A, Hasselgren G: Inability of laser and rotary instrumentation to eliminate root canal infection. *J Am Dent Assoc* 137:67, 2006.
186. Johnson E, Lloyd A, Kuttler S, Namerow K: Comparison between a novel nickel-titanium alloy and 508 Nitinol on the cyclic fatigue life of ProFile 25/.04 rotary instruments. *J Endod*, 34:1406, 2008.
187. Kaplan AE, Ormaechea MF, Picca M, Canzobre MC, Ubios AM: Rheological properties and Biocompatibility of endodontic sealers. *Int Endod J* 36:527, 2003.
188. Karlovic Z, Pezelj-Ribaric S, Miletic I, Jukic S, Grgurevic J, Anic I: Erbium:YAG laser versus ultrasonic in preparation of root-end cavities. *J Endod* 31:821, 2005.
189. Katz A, Tagger M, Tamse A: Rejuvenation of brittle gutta-percha cones—a universal technique? *J Endod* 13:65, 1987.
190. Keate KC, Wong M: A comparison of endodontic file tip quality. *J Endod* 16:486, 1990.
191. Kim S, Dorscher-Kim J, Liu MT, Trowbridge H: Biphasic pulp blood flow response to substance P in the dog as measured with radiolabeled, microsphere injection method. *Arch Oral Biol* 33:305, 1988.
192. Kim S, Schuessler G, Chien S: Measurement of blood flow in the dental pulp of dogs with Xe-133 washout method. *Arch Oral Biol* 28:501, 1983.
193. Kimura Y, Onaga K, Yokoyama K, Kinoshita J, Ogata Y, Matsumoto K: Root surface temperature increase during Er:YAG laser irradiation on root canals. *J Endod* 28:76, 2002.
194. Kimura Y, Wilder-Smaith P, Matsumoto K: Lasers in endodontics: a review. *Int Endod J* 33:173, 2000.
195. Klotz MD, Gerstein HS, Bahn HN: Bacteraemia after topical use of prednisolone in infected pulps. *J Am Dent Assoc* 71:871, 1965.
196. Koba K, Kimura Y, Matsumoto K, et al: Post-operative symptoms and healing after endodontic treatment of infected teeth using pulsed Nd:YAG laser. *Endod Dent Traumatol* 15:68, 1999.
197. Kobayashi C, Suda H: New electronic canal measuring device based on the ratio method. *J Endod* 20:111, 1994.
198. Kolokuris I, Avaniyannis I, Robinson C, Blanshard JM: Effect of moisture and aging on gutta-percha. *J Endod* 18:583, 1992.
199. Komorowski R, Grad H, Yu-Wu X, Friedman S: Antimicrobial substantivity of chlorhexidine-treated bovine root dentin. *J Endod* 26:315, 2000.
200. Kontakiotis EG, Tzanetakis GN, Loizides AL: A 12 month longitudinal in vitro leakage study on a new silicon-based root canal filling material (Gutta-Flow). *Oral Surg Oral Med Oral Pathol Oral Radiol Endod* 103:854, 2007.
201. Krause TA, Liewehr FR, Hahn CL: The antimicrobial effect of MTAD, sodium hypochlorite, doxycycline, and citric acid on *Enterococcus faecalis*. *J Endod* 33:28, 2007.
202. Krauthaim AB, Jermann TH, Bircher AJ: Chlorhexidine anaphylaxis: Case report and review of the literature. *Contact Dermatitis* 50:113, 2004.
203. Krell KV: The effects of CO₂ ice on PFM restorations. *J Endod* 11:51, 1985.

204. Krell KV, Johnson RJ, Madison S: Irrigation patterns during ultrasonic canal instrumentation. Part I: K-type files. *J Endod* 14:65, 1988.
205. Krupp JD, Brantley WA, Gerstein H: An investigation of the torsional and bending properties of seven brands of endodontic files. *J Endod* 10:372, 1984.
206. Kulid J: Diagnostic testing. In Ingle JI, Bakland L, Baumgartner C, editors: *Endodontics*, 6th ed. Hamilton, 2008, BC Decker Inc., pp 542–543.
207. Kullendorff B, Petersson K, Rohlin M: Direct digital radiography for the detection of periapical bone lesions: A clinical study. *Endod Dent Traumatol* 13:183, 1997.
208. Kuruvilla JR, Kamath MP: Antimicrobial activity of 2.5% sodium hypochlorite and 0.2% chlorhexidine gluconate separately and combined, as endodontic irrigants. *J Endod* 24:472, 1998.
209. Lai YY, Pai L, Chen cp: Marginal leakage of different temporary restorations in standardized complex endodontic access preparations. *J Endod* 33:875, 2007.
210. Lambrianidis T, Kosti E, Boutsoukis C, Mazinis M: Removal efficacy of various calcium hydroxide/chlorhexidine medicaments from the root canal. *Int Endod J* 39:55–61, 2006.
211. Lambrianidis T, Margelos J, Beltes P: Removal efficiency of calcium hydroxide dressing from the root canal. *J Endod* 25:85, 1999.
212. Larsen CM, Watanabe I, Glickman GN, He J: Cyclic fatigue analysis of a new generation of nickel titanium rotary instruments. *J Endod* 35:401, 2009.
213. Lautenschlager EP, Jacobs JJ, Marshall GW, Heuer MA: Brittle and ductile torsional failures of endodontic instruments. *J Endod* 3:175, 1977.
214. Lee DH, Kim NR, Lim BS, Lee YK, Hwang KK, Yang HC: Effects of root canal sealers on lipopolysaccharide expression of cyclooxygenase-2 in murine macrophage cells. *J Endod* 33:1329, 2007.
215. Lee DH, Lim BS, Lee YK, Kim NR, Yang HC: Inhibitory effects of root canal sealers on the expression of inducible nitric oxide synthase in lipopolysaccharide-stimulated murine macrophage cells. *J Biomed Mater Res B* 83:91, 2007.
216. Lee DH, Park B, Saxena A, Serene TP: Enhanced surface hardness by boron implantation in nitinol alloy. *J Endod* 22:543, 1996.
217. Lenet BJ, Komorowski R, Wu XY, et al: Antimicrobial substantivity of bovine root dentin exposed to different chlorhexidine delivery vehicles. *J Endod* 26:652, 2000.
218. Leonardo MR, Bezerra da Silva LA, Filho MT, Santana da Silva R: Release of formaldehyde by 4 endodontic sealers. *Oral Surg Oral Med Oral Pathol Oral Radiol Endod* 88:221–225, 1999.
219. Leonardo MR, Guillen-Carlas MG, Pecora JD, Ito IY, Silva LA: Er:YAG laser antimicrobial effects in the root canals of dogs' teeth with pulp necrosis and chronic periapical lesions. *Photomed Laser Surg* 38:295, 2005.
220. Leonardo MR, Tanomaru Filho M, Silva LA, Nelson Filho P, Bonifacio KC, Ito IY: In vivo antimicrobial activity of 2% chlorhexidine used as a root canal irrigating solution. *J Endod* 25:167, 1999.
221. Lewis BB, Chester SB: Formaldehyde in dentistry: A review of mutagenic and carcinogenic potential. *J Am Dent Assoc* 103:429, 1981.
222. Leyhausen G, Heil J, Reifferscheid G, Waldmann P, Geurtsen W: Genotoxicity of the epoxy resin-based root canal sealer AH Plus. *J Endod* 25:109, 1999.
223. Lima KC, Fava LR, Siqueira JF, Jr: Susceptibilities of *Enterococcus faecalis* biofilms to some antimicrobial medications. *J Endod* 27:616, 2001.
224. Limkangwalmongkol S, Burtscher P, Abbot PV, Sandler AB, Bishop BM: A comparative study of the apical leakage of four root canal sealers and laterally condensed gutta-percha. *J Endod* 17:495, 1991.
225. Lin J, Chandler NP, Purton D, Monteith B: Appropriate electrode placement site for electric pulp testing first molar teeth. *J Endod* 33:1296, 2007.
226. Lin S, Zuckerman O, Weiss EI, Fuss Z: Antibacterial efficacy of a new chlorhexidine slow-releasing device to disinfect dental tubules. *J Endod* 29:416, 2003.
227. Lindberg LG, Tamura T, Öberg PÅ: Photoplethysmography. Part 1: Comparison with laser doppler flowmetry. *Med Biol Eng Comput* 29:40, 1991.
228. Lindskog S, Pierce AM, Blomlof L: Chlorhexidine as a root canal medicament for treating inflammatory lesions in the periodontal space. *Endod Dent Traumatol* 14:186, 1998.
229. Lipski M: In vitro infrared thermographic assessment of root surface temperatures generated by high-temperature thermo-plasticized injectible gutta-percha obturation technique. *J Endod* 32:438, 2006.
230. Lipski M: Root surface temperature rises in vitro during root canal obturation with thermoplasticized gutta-percha on a carrier or by injection. *J Endod* 30:441, 2004.
231. Løe H: Does chlorhexidine have a place in the prophylaxis of dental diseases? *J Periodontol Res* 12(Suppl):93, 1973.
232. Løe H, Schiott CR: The effect of mouthrinses and topical application of chlorhexidine on the development of dental plaque and gingivitis in man. *J Periodontol Res* 5(Suppl):79, 1970.
233. Lohbauer U, Dahl U, Dasch W, Petschelt A: Calcium release and pH of gutta-percha points containing calcium hydroxide. *J Dent Res* 80:272, 2001.
234. Loshon CA, Melly E, Setlow B, Setlow P: Analysis of the killing of spores of *Bacillus subtilis* by a new disinfectant, Sterilox®. *J Appl Microbiol* 91:1051, 2001.
235. Lumley PJ, Walmsley AD: Effect of precurving on the performing of endosonic K files. *J Endod* 18:232, 1992.
236. Maden M, Gorgul G, Tinaz AC: Evaluation of apical leakage of root canals obturated with Nd:YAG laser-softened gutta-percha, System B, and lateral condensation techniques. *J Contemp Dent Pract* 3:16, 2002.
237. Magnusson B, Heyden G: Autoradiographic studies of 14C-chlorhexidine given orally in mice. *J Periodontol Res Suppl* 12(Suppl):49, 1973.
238. Malkhassian G, Manzur AJ, Legner M, et al: Antibacterial efficacy of MTAD final rinse and two percent chlorhexidine gel medication in teeth with apical periodontitis: A randomized double-blinded clinical trial. *J Endod* 35:1483–1490, 2009.
239. Manzur A, Gonzalez AM, Pozos A, Silva-Herzog D, Friedman S: Bacterial quantification in teeth with apical periodontitis related to instrumentation and different intracanal medications: A randomized clinical trial. *J Endod* 33:114, 2007.
240. Marais JT, Brozel VS: Electro-chemically activated water in dental unit water lines. *Br Dent J* 187:154, 1999.
241. Marais JT, Williams WP: Antimicrobial effectiveness of electro-chemically activated water as an endodontic irrigation solution. *Int Endod J* 34:237, 2001.
242. Marciano J, Michalesco PM: Dental gutta-percha: chemical composition, x-ray identification, enthalpic studies, and clinical implications. *J Endod* 15:149, 1989.
243. Margelos J, Eliades G, Verdelsis C, Palaghias G: Interaction of calcium hydroxide with zinc oxide-eugenol type sealers: A potential clinical problem. *J Endod* 23:43, 1997.
244. Margelos J, Verdelsis K, Eliades G: Chloroform uptake by gutta-percha and assessment of its concentration in air during the chloroform-dip technique. *J Endod* 22:547, 1996.
245. Margolis HC, Moreno EC, Murphy BJ: Importance of high pKa acids in cariogenic potential of plaque. *J Dent Res* 64:786–792, 1985.
246. Marmay Y, Koter T, Heling I: The effect of periapical rarefying osteitis on cortical and cancellous bone. A study comparing conventional radiographs with computed tomography. *Dentomaxillofac Radiol* 28:267, 1999.
247. Martin H, Ferris C, Mazzella W: An evaluation of media used in electric pulp testing. *Oral Surg Oral Med Oral Pathol* 27:374, 1969.
248. Matsumoto K: Lasers in endodontics. *Dent Clin North Am* 44:889, 2000.
249. Matsuya Y, Matsuya S: Effect of abietic acid and poly-methyl methacrylate on the dissolution process of zinc oxide-eugenol cement. *Biomaterials* 15:307, 1994.
250. Mayeda DL, Simon JH, Aymar DF, Finley K: In vivo measurement accuracy in vital and necrotic canals with the Endex apex locator. *J Endod* 19:545, 1993.
251. Melker KB, Vertucci FJ, Rojas MF, Progulske-Fox A, Belanger M: Antimicrobial efficacy of medicated root canal filling materials. *J Endod* 32:148, 2006.
252. Merino EM, editor: Magnifying the surgical field with an OM. In: *Endodontic Microsurgery*, London, 2009, Quintessence Pub Co, pp 5–9.
253. Mesaros SV, Trope M: Revascularization of traumatized teeth assessed by laser doppler flowmetry: Case report. *Endod Dent Traumatol* 13:24, 1997.
254. Messer HH, Feigal RJ: A Comparison of the antibacterial and cytotoxic effects of parachlorophenol. *J Dent Res* 64:818, 1985.
255. Metzger Z, Better H, Abramovitz I: Immediate root canal disinfection with ultraviolet light: an ex vivo feasibility study. *Oral Surg Oral Med Oral Pathol Oral Radiol Endod* 104:425, 2007.
256. Metzger Z, Teperovich E, Cohen R, Zary R, Paué F, Hülsmann M: Removal of apical smear layer by the Self Adjusting File (SAF): A scanning electron microscope study. *J Endod* Submitted for publication, 2009.
257. Metzger Z, Dotan M, Better H, Abramovitz I: Sensitivity of oral bacteria to 254 nm ultraviolet light. *Int Endod J* 40:120, 2007b.
258. Metzger Z, Huber R, Slavescu D, Dragomirescu D, Tobis I, Better H: Healing kinetics of periapical lesions enhanced by the Apexum procedure: a clinical trial. *J Endod* 35:153, 2009.
259. Metzger Z, Huber R, Tobis I, Better H: Enhancement of healing kinetics of periapical lesions in dogs by the Apexum procedure. *J Endod* 35:40, 2009.
260. Metzger Z, Teperovich E, Zary R, Cohen R, Hof R: Respecting the root canal: a new concept of a Self Adjusting File (SAF). *J Endod* Submitted for publication, 2009.
261. Michaelson RE, Seidberg BH, Guttuso J: An in vivo evaluation of interface media used with the electric pulp tester. *J Am Dent Assoc* 91:118, 1975.
262. Mickel AK, Lindquist KAD, Chogle S, Jones JJ, Curd F: Electric pulp tester conductance through various interface media. *J Endod* 32:1178, 2006.
263. Mickel AK, Nguyen TH, Chogle S: Antimicrobial activity of endodontic sealers on *Enterococcus faecalis*. *J Endod* 29:257, 2003.
264. Mickel AK, Wright ER: Growth inhibition of *Streptococcus anginosus* (Milleri) by three calcium hydroxide sealer and one zinc oxide-eugenol sealer. *J Endod* 25:34, 1999.
265. Mikrogeorgis G, Lyroudia K, Moyvdas I, Nikolaidis N, Pitas I: Digital radiograph registration and subtraction: A useful tool for the evaluation of the progress of chronic apical periodontitis. *J Endod* 30:513, 2004.
266. Miserendino LJ, Moser JB, Heuer MA, Osetek EM: Cutting efficiency of endodontic instruments. I. A quantitative comparison of the tip and fluted region. *J Endod* 11:435, 1985.
267. Miserendino LJ, Moser JB, Heuer MA, Osetek EM: Cutting efficiency of endodontic instruments. II. An analysis of the design of the tip. *J Endod* 12:8, 1986.
268. Miwa Z, Ikawa M, Iijima H, Saito M, Takagi Y: Pulpal blood flow in vital and nonvital young permanent teeth measured by transmitted-light photoplethysmography: A pilot study. *Pediatr Dent* 24:594, 2002.
269. Miyagaki DC, de Carvalho EM, Robazza CR, Chavasco JK, Levorato GL: In vitro evaluation of the antimicrobial activity of endodontic sealers. *Braz Oral Res* 20:303, 2006.
270. Mjör IA, Moorhead JE, Dahl JE: Reasons for replacement of restorations in permanent teeth in general dental practice. *Int Dent J* 50:361, 2000.
271. Mohammadi Z, Khademi AA, Davari AR: Evaluation of the antibacterial substantivity of three concentrations of

- chlorhexidine in bovine root dentine. *Iranian Endod J* 2:113, 2008.
272. Möller ÅJR: Microbiological examination of root canals and periapical tissues of human teeth. *Odontol Tidskr* 74:1, 1966 (special issue).
 273. Monticelli F, Sadek FT, Schuster CG, et al: Efficacy of two contemporary single-cone filling techniques in preventing bacterial leakage. *J Endod* 33:310, 2007.
 274. Monticelli F, Sword J, Martin RL, et al: Sealing properties of two contemporary single-cone obturation systems. *Int Endod J* 40:374, 2007.
 275. Mora MA, Mol A, Tyndall DA, Rivera EM: In vitro assessment of local computed tomography for the detection of longitudinal tooth fractures. *Oral Surg Oral Med Oral Pathol Oral Radiol Endod* 103:825, 2007.
 276. Moser JB, Heuer MA: Forces and efficacy in endodontic irrigation systems. *Oral Surg Oral Med Oral Pathol* 53:425, 1982.
 277. Moshonov J, Slutzky-Goldberg I: Apex locators: An update and prospects for the future. *Int J Comput Dent* 7:359, 2004.
 278. Moshonov J, Slutzky-Goldberg I: Apex locators: update and prospects for the future. *Int J Comp Dent* 7(4):359, 2004.
 279. Muller P, Guggenheim B, Schmidlin PR: Efficacy of gasiform ozone and photodynamic therapy on a multispecies oral biofilm in vitro. *Eur J Oral Sci* 115:77, 2007.
 280. Mumford JM: Evaluation of gutta percha and ethyl chloride in pulp-testing. *Br Dent J* 116:338, 1964.
 281. Narhi MVO, Virtanen A, Kuhta J, Huopaniemi T: Electrical stimulation of teeth with a pulp tester in the cat. *Scand J Dent Res* 87:32, 1979.
 282. Nagayoshi M, Kitamura C, Fukuizumi T, Nishihara T, Terashita M: Antimicrobial effect of ozonated water on bacteria invading dentinal tubules. *J Endod* 30:778, 2004.
 283. Nielsen BA, Craig BJ: Comparison of the Endovac System to needle irrigation of root canals. *J Endod* 33:611, 2007.
 284. Nissan R, Trope M, Zheng C-D, Chance B: Dual wavelength spectrophotometry as a diagnostic test of the pulp chamber contents. *Oral Surg Oral Med Oral Pathol* 74:508, 1992.
 285. Noiri Y, Katsumoto T, Azakami H, Ebisu S: Effects of Er:YAG laser radiation on biofilm-forming bacteria associated with endodontic pathogens in vitro. *J Endod* 34:826, 2008.
 286. Okano M, Nomura M, Hata S, et al: Anaphylactic symptoms due to chlorhexidine gluconate. *Arch Dermatol* 125:50, 1989.
 287. Oliveira RG, Gouw-Soares S, Baldochi SL, Edwards CP: Scanning electron microscopy: effect of Er:YAG and Nd:YAG lasers on apical seals after apicoectomy and retrofill. *Photomed Laser Surg* 23:533, 2004.
 288. Onay EO, Unger M, Ozdemir BH: In vivo evaluation of the biocompatibility of a new resin-based obturation material. *Oral Surg Oral Med Oral Pathol* 104:e60, 2007.
 289. Oncag O, Hosgor M, Hilmioglu S, Zekioglu O, Eronat C, Burhanoglu D: Comparison of antibacterial and toxic effects of various root canal irrigants. *Int Endod J* 36:423, 2003.
 290. Ørstavik D, Haapasalo M: Disinfection by endodontic irrigants and dressings of experimentally infected dentinal tubules. *Endod Dent Traumatol* 6:142, 1990.
 291. Oztan MD, Kiyam M, Gerceker D: Antimicrobial effect, in vitro, of gutta-percha points containing root canal medications against yeasts and *Enterococcus faecalis*. *Oral Surg Oral Med Oral Pathol Oral Radiol Endod* 102:410, 2006.
 292. Pantera EA, Anderson RW, Pantera CT: Reliability of electric pulp testing after pulpal testing with dichlorodi-fluoromethane. *J Endod* 19:312, 1993.
 293. Paquette L, Legner M, Fillery ED, Friedman S: Antibacterial efficacy of chlorhexidine gluconate intracanal medication in vivo. *J Endod* 33:788, 2007.
 294. Park DS, Lee HJ, Yoo HM, Oh TS: Effect of Nd:YAG laser irradiation of the apical leakage of obturated root canals: an electrochemical study. *Int Endod J* 34:318, 2001.
 295. Pascon E, Spångberg LS: In vitro cytotoxicity of root canal filling materials. Part I. Gutta-percha. *J Endod* 16:429, 1990.
 296. Paurazas SB, Geist JR, Pink FE, Hoen MM, Steiman HR: Comparison of diagnostic accuracy of digital imaging by using CCD and CMOS-APS sensors with E-speed film in the detection of periapical bony lesions. *Oral Surg Oral Med Oral Pathol Oral Radiol Endod* 89:356, 2000.
 297. Pawinska M, Skrzydlewska E: Release of hydroxyl ions from calcium hydroxide preparations used in endodontic treatment. *Rocz Akad Med Bialymst* 48:145, 2003.
 298. Perez SB, Tejerina DP, Perez Tito RI, Bozza FL, Kaplan AE, Molgatini SL: Endodontic microorganisms susceptibility by direct contact test. *Acta Odontol Latinoam* 21:169, 2008.
 299. Perin FM, Franca SC, Silva-Sousa YT, et al: Evaluation of the Microbial effect of Er:YAG laser irradiation versus 1% sodium hypochlorite irrigation for root canal disinfection. *Aust Endod J* 30:20, 2004.
 300. Peters DD: Evaluation of the effects of carbon dioxide used as a pulp test. Part III: In vivo effect on human enamel. *J Endod* 12:13, 1986.
 301. Peters LB, Van Winkelhoff AJ, Buijs JF, Wesselink PR: Effects of instrumentation, irrigation and dressing with calcium hydroxide on infection in pulpless teeth with periapical bone lesions. *Int Endod J* 35:13, 2002.
 302. Peters OA: Current challenges and concepts in the preparation of root canal systems: A review. *J Endod* 30:559, 2004.
 303. Pham NH, Weiner JM, Reiser GS, Baldo BA: Anaphylaxis to chlorhexidine. Case report. Implication of immunoglobulin E antibodies and identification of an allergenic determinant. *Clin Exp Allergy* 30:1001, 2000.
 304. Pizzo G, Giannanco GM, Cumbo E, Nicolosi G, Gallina G: In vitro antibacterial activity of endodontic sealers. *J Dent* 34:35, 2006.
 305. Podbielski A, Spahr A, Haller B: Additive antimicrobial activity of calcium hydroxide and chlorhexidine on common endodontic bacterial pathogens. *J Endod* 29:340, 2003.
 306. Popescu IG, Popescu M, Man D: Drug allergy: Incidence in terms of age and some drug allergens. *Med Intern* 22:195, 1984.
 307. Portenier I, Waltimo T, Ørstavik D, Haapasalo M: Killing of *Enterococcus faecalis* by MTAD and chlorhexidine digluconate with or without cetrimide in the presence or absence of dentine powder or BSA. *J Endod* 32:138, 2006.
 308. Powell SE, Simon JHS, Maze B: A comparison of the effect of modified and nonmodified instrument tips on apical canal configuration, Part 1. *J Endod* 12:293, 1986.
 309. Powell SE, Wong PD, Simon JHS: A comparison of the effect of modified and nonmodified instrument tips on apical canal configuration. Part 2. *J Endod* 14:224, 1988.
 310. Rapisarda E, Bonaccorso A, Tripi TR, Condorelli GG, Torrisi L: Wear of nickel-titanium endodontic instruments evaluated by scanning electron microscopy: effect of ion implantation. *J Endod* 27:588, 2001.
 311. Rasimick BJ, Nekich M, Hladek MM, Musikant BL, Deutsch AS: Interaction between chlorhexidine digluconate and EDTA. *J Endod* 34:1521, 2008.
 312. Richman MJ: The use of ultrasonics in root canal therapy and root resection. *J Med* 12:12, 1957.
 313. Rickard GD, Richardson R, Johnson T, Mccoll D, Hooper L: Ozone therapy for the treatment of dental caries. *Cochrane Database Syst Rev*, CD004153, 2004.
 314. Rickoff B, Trowbridge H, Baker J, Fuss Z, Bender IB: Effects of thermal vitality tests on human dental pulp. *J Endod* 14:482, 1988.
 315. Ringel AM, Patterson SS, Newton CW, Miller CH, Mulhern JM: In vivo evaluation of chlorhexidine gluconate solution and sodium hypochlorite solution as root canal irrigants. *J Endod* 8:200, 1982.
 316. Roane JB, Sabala CL, Duncanson MG: The "balanced force" concept for instrumentation of curved canals. *J Endod* 11:203, 1985.
 317. Rölla G, Löe H, Schiøtt CR: The affinity of chlorhexidine for hydroxyapatite and salivary mucins. *J Periodont Res* 5(Suppl):90, 1970.
 318. Roy RA, Ahmad M, Crum LA: Physical mechanisms governing the hydrodynamic response of an oscillating ultrasonic file. *Int Endod J* 27:197, 1994.
 319. Rowe AHR, Pitt Ford TR: The assessment of pulpal vitality. *Int Endod J* 23:77, 1990.
 320. Ruddle CJ: The ProTaper endodontic system: geometries, features and guidelines for use. *Dent Today* 20:60, 2001.
 321. Sabala CL, Roane JB, Southard LZ: Instrumentation of curved canals using a modified tipped instrument: a comparison study. *J Endod* 14:59, 1988.
 322. Safavi KE, Nichols FC: Alteration of biological properties of bacterial lipopolysaccharide by calcium hydroxide treatment. *J Endod* 20:127, 1994.
 323. Safavi KE, Nichols FC: Effect of calcium hydroxide on bacterial lipopolysaccharide. *J Endod* 19:76, 1993.
 324. Safavi KE, Spångberg L, Langeland K: Root canal dentinal tubule disinfection. *J Endod* 16:207, 1990.
 325. Saleh IM, Ruyter IE, Haapasalo M, Ørstavik D: The effects of dentin pretreatment on the adhesion of root canal sealers. *Int Endod J* 35:859, 2002.
 326. Santos C, Sousa-Neto MD, Alfredo E, Guerisoli DM, Percora JD, Comelli Lea RF: Morphologic evaluation of the radicular dentin irradiated with Nd:YAG laser under different parameters and angles of incidence. *Photomed Laser Surg* 23:590, 2005.
 327. Sathorn C, Parashos P, Messer HH: Effectiveness of single-versus multiple-visit endodontic treatment of teeth with apical periodontitis: A systematic review and meta-analysis. *Int Endod J* 38:347, 2005.
 328. Sato I, Ando-Kurihara N, Kota K, Iwaku M, Hoshino E: Sterilization of infected root-canal dentine by topical application of a mixture of ciprofloxacin, metronidazole and minocycline in situ. *Int Endod J* 29:118, 1996.
 329. Saunders EM: In vivo findings associated with heat generation during thermomechanical compaction of gutta-percha. 1. Temperature levels at the external surface of the root. *Int Endod J* 23:263, 1990.
 330. Schäfer E: Irrigation of the root canal. *ENDO* 1:11-28, 2007.
 331. Schäfer E, Zandbiglari T: Solubility of root canal sealers in water and artificial saliva. *Int Endod J* 36:660, 2003.
 332. Schilder H, Goodman A, Aldrich W: The thermomechanical properties of gutta-percha I. The compressibility of gutta-percha. *Oral Surg Oral Med Oral Pathol* 37:946, 1974.
 333. Schilder H, Goodman A, Aldrich W: The thermomechanical properties of gutta-percha, III. Determination of phase transition temperatures for gutta-percha. *Oral Surg Oral Med Oral Pathol* 38:109, 1974.
 334. Schilder H, Goodman A, Aldrich W: The thermomechanical properties of gutta-percha, V. Volume changes in bulk gutta-percha as a function of temperature and its relationship to molecular phase transformation. *Oral Surg Oral Med Oral Pathol* 59:285, 1985.
 335. Schnettler JM, Wallace JA: Pulse oximetry as a diagnostic tool of pulpal vitality. *J Endod* 17:488, 1991.
 336. Schoop U, Goharkhay K, Klimscha J, et al: The use of erbium, chromium:yttrium-scandium-gallium-garnet laser in endodontic treatment: The results of an in vitro study. *J Am Dent Assoc* 138:949, 2007.
 337. Schoop U, Moritz A, Kluger W, et al: The Er:YAG laser in endodontics: results of an in vitro study. *Lasers Surg Med* 30:360, 2002.
 338. Schuur AH, Moorer WR, Wesselink PR: Solvents for the removal of gutta-percha from root canals. 2. Side effects of Chloroform, halothane and xylene. *Ned Tijdschr Tandheelkd* 111:303, 2004.
 339. Schroeder A, Ledermix 1962-Ledermix today. Evaluation after 13 years of experience. *Zahnartzl Prax*, May 2:26(9):195-196, 1975.
 340. Scully C, Ng YL, Gulabivala K: Systemic complications due to endodontic manipulations. *Endod Topics* 4:60, 2003.
 341. Seltzer S, Bender IB, Ziontz M: The dynamics of pulpal inflammation: Correlation between diagnostic data and actual histological findings in the pulp. *Oral Surg Oral Med Oral Pathol* 16:973, 1963.
 342. Senia ES, Marraro RV, Mitchell JL, Lewis AG, Thomas L: Rapid sterilization of gutta-percha cones with 5.25% sodium hypochlorite. *J Endod* 1:136, 1975.
 343. Senia ES, Marshal FJ, Rosen S: The solvent action of sodium hypochlorite on pulp tissue of extracted teeth. *Oral Surg Oral Med Oral Pathol* 31:96, 1971.

344. Serper A, Calt S, Dogan AL, Gue D, Ozcelik B, Kuraner T: Comparison of the cytotoxic effects and smear layer removing capacity of oxidative potential water, NaOCl, EDTA. *J Oral Sci* 43:233, 2001.
345. Seto BG, Nicholls JI, Harrington GW: Torsional properties of twisted and machined endodontic files. *J Endod* 16:355, 1990.
346. Shabahang S, Pouresmail M, Torabinejad M: In vitro antimicrobial efficacy of MTAD and sodium hypochlorite. *J Endod* 29:450, 2003.
347. Shabahang S, Torabinejad M: Effect of MTAD on *Enterococcus faecalis*-contaminated root canals of extracted human teeth. *J Endod* 29:576, 2003.
348. Shipper G, Ørstavik D, Teixeira F, Trope M: An evaluation of microbial leakage in roots filled with a thermoplastic synthetic polymer-based root canal filling material (Resilon). *J Endod* 30:342, 2004.
349. Short RD, Dorn SO, Kutter S: The crystallization of sodium hypochlorite on gutta-percha cones after the rapid-sterilization technique: an SEM study. *J Endod* 29:670, 2003.
350. Shuping GB, Ørstavik D, Sigurdsson A, Trope M: Reduction of intracanal bacteria using nickel-titanium rotary instrumentation and various medications. *J Endod* 26:751, 2000.
351. Shur AI, Sedgley CM, Fenno JC: The antimicrobial efficacy of 'MPG' gutta-percha in vitro. *Int Endod J* 36:616, 2003.
352. Sigurdsson A: Pulpal diagnosis. *Endod Topics* 5:12, 2003.
353. Sipert CR, Hussne RP, Nishiyama CK, Torres SA: In vitro antimicrobial activity of Fill Canal, Sealarex, Mineral Trioxide Aggregate, Portland Cement and EndoRez. *Int Endod J* 38:539, 2005.
354. Siqueira JF, Jr, De Uzeda M: Intracanal medicaments: Evaluation of the antibacterial effects of chlorhexidine, metronidazole, and calcium hydroxide associated with three vehicles. *J Endod* 23:167, 1997.
355. Siqueira JF, Jr, Favieri A, Gahyva SM, Moraes SR, Lima KC, Lopes HP: Antimicrobial activity and flow rate of newer and established root canal sealers. *J Endod* 26:274, 2000.
356. Siqueira JF, Jr, Paiva SS, Rocas IN: Reduction in the cultivable bacterial populations in infected root canals by a chlorhexidine-based antimicrobial protocol. *J Endod* 33:541, 2007.
357. Siqueira JF, Jr, Rocas IN, Paiva SS, Guimaraes-Pinto T, Magalhaes KM, Lima KC: Bacteriologic investigation of the effects of sodium hypochlorite and chlorhexidine during the endodontic treatment of teeth with apical periodontitis. *Oral Surg Oral Med Oral Pathol Oral Radiol Endod* 104:122, 2007.
358. Siren EK, Lavonious E, Kontakiotis E: Effects of Ca(OH)₂ gutta-percha points on bacteria in root canals. *J Dent Res* 79:543, 2000.
359. Sirtes G, Waltimo T, Schaetzle M, Zehnder M: The effects of temperature on sodium hypochlorite short-term stability, pulp dissolution capacity, and antimicrobial efficacy. *J Endod* 31:669–671, 2005.
360. Sjögren U, Figdor D, Spångberg LSW, Sundqvist G: The antimicrobial effect of calcium hydroxide as a short-term intracanal dressing. *Int Endod J* 24:119, 1991.
361. Sjögren U, Sundqvist G: Bacteriologic evaluation of ultrasonic root canal instrumentation. *Oral Surg Oral Med Oral Pathol* 63:366, 1987.
362. Sjögren U, Sundqvist G, Nair PNR: Tissue reaction to gutta-percha particles of various sizes when implanted subcutaneously in guinea pigs. *Eur J Oral Sci* 103:313, 1995.
363. Snellman E, Rantanen T: Severe anaphylaxis after a chlorhexidine bath. *J Am Acad Dermatol* 40:771, 1999.
364. Soares JA, Leonardo MR, Da Silva LA, Tanomaru Filho M, Ito IY: Effect of rotary instrumentation and of the association of calcium hydroxide and chlorhexidine on the antiseptics of the root canal system in dogs. *Braz Oral Res* 20:120, 2006.
365. Solovyeva AM, Dummer PMH: Cleaning effectiveness of root canal irrigation with electrochemically activated anolyte and catholyte solutions: A pilot study. *Int Endod J* 33:494, 2000.
366. Soukos NS, Chen PS, Morris JT, et al: Photodynamic therapy for endodontic disinfection. *J Endod* 32:979, 2006.
367. Sousa-Neto MD, Marchesan MA, Pecora JD, Junior AB, Silva-Souse YT, Saquy PC: Effect of Er:YAG laser on adhesion of root canal sealers. *J Endod* 28:185, 2002.
368. Sousa-Neto MD, Silva Coelho FI, Marchesan MA, Alfredo E, Silva-Sousa YT: Ex vivo study of the adhesion of an epoxy based sealer to human dentin submitted to irradiation with Er:YAG and Nd:YAG lasers. *Int Endod J* 38:866, 2005.
369. Southard SR, Drisko CL, Killoy WJ, Cobb CM, Tira DE: The effect of 2% chlorhexidine digluconate irrigation on clinical parameters and the level of *Bacteroides gingivalis* in periodontal pockets. *J Periodontol* 60:302, 1989.
370. Spångberg L, Engström B, Langeland K: Biologic effects of dental materials. 3. Toxicity and antimicrobial effect of endodontic antiseptics in vitro. *Oral Surg Oral Med Oral Pathol* 36:856, 1973.
371. Spångberg L, Torberg M, Ryding E: Biological effects of endodontic antimicrobial agents. *J Endod* 5:166, 1979.
372. Spångberg LSW, Barbosa SV, Lavigne GD: AH26 releases formaldehyde. *J Endod* 19:596, 1993.
373. Spratt DA, Pratten J, Wilson M, Gulabivala K: An in vitro evaluation of the antimicrobial efficacy of irrigants on biofilms of root canal isolates. *Int Endod J* 34:300, 2001.
374. Stabholz A, Sahar-Helft S, Moshonov J: Laser in endodontics. *Dent Clin North Am* 48:809, 2004.
375. Stabholz A, Moshonov J, Sahar-Helft S, Rocca JP: Lasers in endodontics. In Ingle JJ, Bakland LK, Baumgartner JC, editors: *Ingle's Endodontics*, 6th edn. Hamilton, ON, Canada, 2008, BC Decker Inc.
376. Stabholz A, Khayat A, Ravanshad SH, McCarthy DWD, Neev J, Torabinejad M: Effects of Nd:YAG laser on apical seal of teeth after apicoectomy and retrofill. *J Endod* 18:371, 1992.
377. Stabholz A, Khayat ••, Weeks DA, Neev J, Torabinejad M: A scanning electron microscopic study of the apical dentine surfaces lased with Nd:YAG laser following apicoectomy and retrofill. *Int Endod J* 25:288, 1992.
378. Staehle HJ, Spiess V, Heinecke A, Muller HP: Effect of root canal filling materials containing calcium hydroxide and the alkalinity of root dentin. *Endod Dent Traumatol* 11:163, 1995.
379. Stenman E, Spångberg LSW: Machining efficiency of Flex-R, K-Flex, Trio-Cut, and S-Files. *J Endod* 16:575, 1990.
380. Stock CJR: Current status of the use of ultrasound in endodontics. *Int Dent J* 41:175, 1991.
381. Sunada I: New method for measuring the length of the root canal. *J Dent Res* 41:375, 1962.
382. Sweatman TL, Baumgartner JC, Sakaguchi RL: Radicular temperatures associated with thermoplasticized gutta-percha. *J Endod* 27:512, 2001.
383. Szepe S, Grumann L, Ronge K, Schriever A, Schultz M, Heidemann D: In vitro cytotoxicity of medicated and non-medicated gutta-percha points in cultures of gingival fibroblasts. *J Endod* 29:36, 2003.
384. Takeda FH, Harashima T, Kimura Y, Matsumoto K: A comparative study of the removal of smear layer by three endodontic irrigants and two types of lasers. *Int Endod J* 32:32, 1999.
385. Tani-Ishii N, Teranara T: Clinical and radiographic evaluation of root canal obturation with Obtura II. *J Endod* 29:739, 2003.
386. Tanomaru Filho M, Leonardo MR, Da Silva LA: Effect of irrigating solution and calcium hydroxide root canal dressing on the repair of apical and periapical tissues of teeth with periapical lesion. *J Endod* 28:295, 2002.
387. Tanomaru-Filho M, Tanomaru JM, Barros DB, Wantanabe E, Ito IY: In vitro antimicrobial activity of endodontic sealers, MTA-based cements and Portland cement. *J Oral Sci* 49:41, 2007.
388. Tasman F, Cehreli ZC, Ogan C, Etikan I: Surface tension of root canal irrigants. *J Endod* 26:586, 2000.
389. Tay FR, Hosoya Y, Loushine RJ, Pashley DH, Weller RN, Low DC: Ultrastructure of intraradicular dentin after irrigation with biopure MTAD. II. The consequence of obturation with an epoxy resin-based sealer. *J Endod* 32:473, 2006.
390. Tay FR, Pashley DH, Loushine RJ, et al: Ultrastructure of smear layer-covered intraradicular dentin after irrigation with biopure MTAD. *J Endod* 32:218, 2006.
391. Thibodeau B, Teixeira F, Yamauchi M, Caplan DJ, Trope M: Pulp revascularization of immature dog teeth with apical periodontitis. *J Endod* 33:680, 2007.
392. Torabinejad M, Johnson WB (Inventors, Assignee) Irrigation Solution and Methods for Use, US Patent and Trademark Office, December 25, 2003.
393. Torabinejad M, Shabahang S, Aprecio RM, Kettering JD: The antimicrobial effect of MTAD: An in vitro investigation. *J Endod* 29:400, 2003.
394. Torabinejad M, Shabahang S, Bahjri K: Effect of MTAD on postoperative discomfort: A randomized clinical trial. *J Endod* 31:171, 2005.
395. Treudler R, Richter G, Geier J, Schnuch A, Orfanos CE, Tebbe B: Increase in sensitization to oil of turpentine: recent data from a Multicenter Study on 45,005 patients from the German-Austrian Information Network of Departments of Dermatology (IVDK). *Contact Dermatitis* 42:68, 2001.
396. Trope M, Jaggi J, Barnett F, Tronstad L: Vitality testing of teeth with a radiation probe using 133 xenon radioisotope. *Endod Dent Traumatol* 2:215, 1986.
397. Trope M, Sigurdsson A: Clinical manifestations and diagnosis. In Ørstavik D, Pitt Ford TR, editors: *Essential Endodontology: Prevention and Treatment of Apical Periodontitis*. Oxford, 1998, Blackwell Science.
398. Turesky S, Warner V, Lin PS, Soloway B: Prolongation of antibacterial activity of chlorhexidine adsorbed to teeth. Effect of sulfates. *J Periodontol* 48:646, 1977.
399. Tyndall DA, Kapa SF, Bagnell CP: Digital subtraction radiography for detecting cortical and cancellous bone changes in the periapical region. *J Endod* 16:173, 1990.
400. Usacheva MN, Teichert MC, Biel MA: Comparison of the methylene blue and toluidine blue photobactericidal efficacy against gram-positive and gram-negative microorganisms. *Lasers Surg Med* 29:165, 2001.
401. Vahdaty TR, Ford Pitt, Wilson RF: Efficacy of chlorhexidine in disinfecting dentinal tubules in vitro. *Endod Dent Traumatol* 9:243–248, 1993.
402. van der Sluis LWM, Wu MK, Wesselink PR: A comparison between a smooth wire and a K-file in the removal of artificially placed dentine debris in plastic blocks. *Int Endod J* 38:593, 2005.
403. van der Sluis LWM, Wu MK, Wesselink PR: The efficacy of ultrasonic irrigation to remove artificially placed dentine debris from human root canals prepared using instruments of varying taper. *Int Endod J* 38:764, 2005.
404. Vezzani MS, Pietro R, Silva-Sousa YT, Brugnera-Junior A, Sousa-Neto MD: Disinfection of root canals using Er:YAG laser at different frequencies. *Photomed Laser Surg* 24:499, 2006.
405. Vianna ME, Horz HP, Gomes BP, Conrads G: In vivo evaluation of microbial reduction after chemo-mechanical preparation of human root canals containing necrotic pulp tissue. *Int Endod J* 39:484, 2006.
406. Villalobos RL, Moser JB, Heuer MA: A method to determine the cutting efficiency of root canal instruments in rotary motion. *J Endod* 6:667, 1980.
407. Virducic D, Jukietc S, Karlovic Z, Miletic L, Anic I: Removal of gutta-percha from root canals using Nd:YAG laser. *Int Endod J* 36:670, 2003.
408. Vivacqua-Gomes N, Ferraz CC, Gomes BP, Zaia AA, Teixeira FB, Souza-Filho FJ: Influence of irrigants on the coronal microleakage of laterally condensed gutta-percha root fillings. *Int Endod J* 35:791–795, 2002.
409. Wainwright M: Photodynamic antimicrobial chemotherapy (PACT). *J Antimicrob Chemother* 42:13, 1998.
410. Wainwright M, Crossley KB: Photosensitizing agents—circumventing resistance and breaking down biofilms: A review. *Int Biodeterioration Biodegradation* 53:119, 2004.
411. Wainwright M, Phoenix DA, Laycock SL, Wareing DR, Wright PA: Photobactericidal activity of phenothiazinium

- dyes against methicillin-resistant strains of *Staphylococcus aureus*. *FEMS Microbiol Lett* 160:177, 1998.
412. Wallia H, Brantley WA, Gerstein H: An initial investigation of the bending and torsional properties of nitinol root canal files. *J Endod* 14:246, 1988.
413. Walmsley AD: Ultrasound and root canal treatment: The need for scientific evaluation. *Int Endod J* 20:105, 1987.
414. Walmsley AD, Williams AR: Effects of constraint on the oscillatory pattern of endosonic files. *J Endod* 15:189, 1989.
415. Waltimo T, Trope M, Haapasalo M, Ørstavik D: Clinical efficacy of treatment procedures in endodontic infection control and one year follow-up of periapical healing. *J Endod* 31:863, 2005.
416. Waltimo TM, Ørstavik D, Siren EK, Haapasalo MP: In vitro susceptibility of *Candida albicans* to four disinfectants and their combinations. *Int Endod J* 32:421, 1999.
417. Wang QQ, Zhang CF, Yim XZ: Evaluation of the bacteriocidal effect of Er,Cr:YSGG and Nd:YAG lasers in experimentally infected root canals. *J Endod* 33:630, 2007.
418. Wang X, Sun Y, Kimura Y, Kinoshita J, Ishizaki NT, Matsumo T: Effects of diode laser irradiation on smear layer removal from root canal walls and apical leakage after obturation. *Photomed Laser Surg* 23:575, 2005.
419. Webber RT, del Rio CE, Brady JM, Segall RO: Sealing quality of a temporary filling material. *Oral Surg Oral Med Oral Pathol* 46:123, 1978.
420. Weller RN, Brady JM, Bernier WE: Efficacy of ultrasonic cleaning. *J Endod* 6:740, 1980.
421. Wilder-Smith PE: A new method for the non invasive recording of blood flow in human dental pulp. *Int Endod J* 21:307, 1988.
422. Willershausen B, Hagedorn B, Tekyatan H, Briseno Marroquin B: Effect of calcium hydroxide and chlorhexidine based gutta-percha points on gingival fibroblasts and epithelial tumor cells. *Eur J Med Res* 9:345, 2004.
423. Wilkinson K, Beeson T, Kirkpatrick T: Fracture resistance of simulated immature teeth filled with Resilon, gutta-percha, or composite. *J Endod* 33:480–483, 2007.
424. Wilson BL, Baumgartner JC: Comparison of spreader penetration during lateral compaction of .04 and .02 tapered gutta-percha. *J Endod* 29:828, 2003.
425. Windley W 3rd, Teixeira F, Levin L, Sigurdsson A, Trope M: Disinfection of immature teeth with a triple antibiotic paste. *J Endod* 31:439, 2005.
426. Winik R, Araki AT, Negrao JA, Bello-Silva MS, Lage-Marques JL: Sealer penetration and marginal permeability after apicoectomy varying retrocavity preparation and re-filling material. *Braz Dent J* 17:323, 2006.
427. Winrow MJ: Metabolic studies with radiolabelled chlorhexidine in animals and man. *J Periodontol Res* 12(Suppl):45, 1973.
428. Wolcott JF, Himel VT, Hicks ML: Thermafil retreatment using a new "System B" technique or a solvent. *J Endod* 25:761, 1999.
429. Wu MK, Van Der Sluis LWM, Wesseling PR: The capability of two hand instrumentation techniques to remove the inner layer of dentine in oval canals. *Int Endod J* 36:218, 2003.
430. Wuerch RM, Apicella MJ, Mines P, Yanchic PJ, Pashley DH: Effect of 2% chlorhexidine gel as an intracanal medication on the apical seal of the root-canal system. *J Endod* 30:788, 2004.
431. Yamashita JC, Tanomaru Filho M, Leonardo MR, Rossi MA, Silva LA: Scanning electron microscopic study of the cleaning ability of chlorhexidine as a root-canal irrigant. *Int Endod J* 36:391, 2003.
432. Yesilsoy C, Whitaker E, Cleveland D, Phillips E, Trope M: Antimicrobial and toxic effects of established and potential root canal irrigants. *J Endod* 21:513, 1995.
433. Yoshioka T, Kobayashi C, Suda H, Sasaki T: An observation of the healing process of periapical lesions by digital subtraction radiography. *J Endod* 28:589, 2002.
434. Yu DG, Kimura Y, Tomita Y, Nakamura Y, Watanabe H, Matsumoto K: Study on removal effects of filling materials and broken files from root canals using pulsed Nd:YAG laser. *J Clin Laser Med Surg* 18:23, 2000.
435. Zaia AA, Nakagawa R, Quadros I, et al: An in vitro evaluation of four materials as barriers to coronal microleakage in root-filled teeth. *Int Endod J* 35:729, 2002.
436. Zakariasen KL, Brayton SM, Collison DM: Efficient root canal placement without chloroform. *J Can Dent Assoc* 56:509, 1990.
437. Zamany A, Safavi K, Spångberg LSW: The effect of chlorhexidine as an endodontic disinfectant. *Oral Surg Oral Med Oral Pathol Oral Radiol Endod* 96:578, 2003.
438. Zehnder M, Grawehr M, Hasselgren G, Waltimo T: Tissue-dissolution capacity and dentin-disinfecting potential of calcium hydroxide mixed with irrigating solutions. *Oral Surg Oral Med Oral Pathol Oral Radiol Endod* 96:608, 2003.
439. Zehnder M: Root canal irrigants. *J Endod* 32:389, 2006.
440. Zehnder M, Söderling E, Salonen J, Waltimo T: Preliminary evaluation of bioactive glass S53p4 as an endodontic medication in vitro. *J Endod* 30:220, 2004.
441. Zerella JA, Fouad AF, Spångberg LS: Effectiveness of a calcium hydroxide and chlorhexidine digluconate mixture as disinfectant during retreatment of failed endodontic cases. *Oral Surg Oral Med Oral Pathol Oral Radiol Endod* 100:756, 2005.
442. Zmener O, Banegas G, Pameijer CH: Coronal micro-leakage of three temporary restorative materials: an in vitro study. *J Endod* 30:582, 2004.
443. Zmener O, Dominquez FV: Tissue response to a glass ionomer used as an endodontic cement. *Oral Surg Oral Med Oral Pathol* 56:198, 1983.
444. Zmener O, Pameijer CH: Clinical and radiographic evaluation of a resin-based root canal sealer. *Am J Dent* 17:19, 2004.
445. Zmener O, Pameijer CH, Serrano SA, Videira M, Macchi RL: Significance of moist root canal dentin with the use of methacrylate-based endodontic sealers: an in vitro coronal dye leakage study. *J Endod* 34:76, 2008.

SUGGESTED READINGS

- Addy M: Hibitane in the treatment of aphthous ulceration. *J Clin Periodontol* 4:108–116, 1977.
- Attin R, Thon C, Schlagenhauf U, et al: Recolonization of *mutans* streptococci on teeth with orthodontic appliances after antimicrobial therapy. *Eur J Orthod*, 27:489, 2005.
- Bergmans L, Moisiadis P, Tenghels W, VanMeerbeek B, Quirynen M, Lambrechts P: Bacteriocidal effect of Nd:YAG laser irradiation on some endodontic pathogens ex vivo. *Int Endod J* 39:547, 2006.
- Cameron B: The synergistic relationship between ultrasound and sodium hypochlorite: A SEM evaluation. *J Endod* 13:41, 1987.
- Cohen S, Berman LH: Obturation with heat and vibration: The DownPak device. *Gen Dent* 56:194, 2008.
- Cooke C, Rowbotham TC: The closure of open apices in non-vital immature incisor teeth. *Br Dent J* 165:420, 1988.
- Coolidge E: The diagnosis and treatment of conditions resulting from diseased dental pulps. *J Natl Dent Assoc* 6:337, 1919.
- Dakin HD: On the use of certain antiseptic substances in the treatment of infected wounds. *Br Med J* 2:318, 1915.
- Dezan E: Reaction of dogs' teeth to root canal filling with mineral trioxide or a glass-ionomer sealer. *J Endod* 25:728, 1999.
- Emilson CG, Fornell J: Effect of toothbrushing with chlorhexidine gel on salivary microflora, oral hygiene, and caries. *Scand J Dent Res* 84:308, 1976.
- Estrela C, Bueno MR, Leles CR, Azevedo B, Azevedo JR: Accuracy of cone beam computed tomography and panoramic and periapical radiography for detection of apical periodontitis. *J Endod* 34:273, 2008.
- Fouad AF, Rivera EM, Krell KV: Accuracy of the Endex with variations in canal irrigants and foramen size. *J Endod* 19:63, 1993.
- Hauser V, Braun A, Frentzen M: Penetration depth of a dye marker into dentine using a novel hydrodynamic system (Rinsendo). *Int Endod J* 40:644, 2007.
- Hoshino E, Kurihara-Ando N, Sato I, et al: In-vitro antibacterial susceptibility of bacteria taken from infected root dentine to a mixture of ciprofloxacin, metronidazole and minocycline. *Int Endod J* 29:125, 1996.
- Kazemi RB, Stenman E, Spångberg LSW: A comparison of stainless steel and nickel-titanium H-type instruments of identical design: torsional and bending tests. *Oral Surg Oral Med Oral Pathol* 90:500, 2000.
- Lauper R, Lutz F, Barbakow F: An in vivo comparison of gradient and absolute impedance electronic apex locators. *J Endod* 22:260, 1996.
- Lin YH, Mickel AK, Chogle S: Effectiveness of selected materials against *Enterococcus faecalis*. Part 3. The antibacterial effect of calcium hydroxide and chlorhexidine on *Enterococcus faecalis*. *J Endod* 29:565, 2003b.
- Martell B, Chandler NP: Electrical and dye leakage comparison of three root-end restorative materials. *Quintessence Int* 33:30, 2002.
- Moorer WR, Wesseling PR: Factors promoting the tissue dissolving capability of sodium hypochlorite. *Int Endod J* 15:187, 1982.
- O'Driscoll, Dowker S, Anderson P, Wilson R, Gulabivala K: Effects of sodium hypochlorite solution on root dentine composition. *J Mater Sci Mater Med* 13:219, 2002.
- Picoli F, Brugnara-Junior A, Saquy PC, Guerisoli DM, Pecora JD: Effect of Er:YAG laser and EDTAC on the adhesiveness to dentin of different sealers containing calcium hydroxide. *Int Endod J* 36:472, 2003.
- Pogrel MA, Yen CK, Taylor R: Studies in tooth crown temperature gradients with the use of infrared thermography. *Oral Surg Oral Med Oral Pathol* 67:583, 1989.
- Pommel L, About I, Pashley D, Camps J: Apical leakage of four endodontic sealers. *J Endod* 29:208, 2003.
- Saunders EM: In vitro finding associated with heat generation during thermomechanical compaction of gutta-percha. 2. Histological response to temperature elevation on the external root surface of the root. *Endod Dent Traumatol* 11:181, 1995.
- Schoop U, Barylyak A, Goharkhay K, Beer F, et al: The impact of an erbium, chromium-scandium-gallium-garnet laser with radial-firing tips on endodontic treatment. *Laser Surg Med* 24:59, 2009.
- Soares I, Goldberg F, Massone EJ, Soares IM: Periapical tissue response to two calcium hydroxide-containing endodontic sealers. *J Endod* 16:166, 1990.
- Torabinejad M, Handysides R, Khademi AA, Bakland LK: Clinical implications of the smear layer in endodontics: A review. *Oral Surg Oral Med Oral Pathol Oral Radiol Endod* 94:658, 2002.
- Trope M, Pettigrew J, Petras J, Barnett F, Tronstad L: Differentiation of radicular cyst and granulomas using computerized tomography. *Endod Dent Traumatol* 5:69, 1989.
- White RR, Hays GL, Janer LR: Residual antimicrobial activity after canal irrigation with chlorhexidine. *J Endod* 23:229, 1997.
- Wilson M: Susceptibility of oral bacterial biofilms to antimicrobial agents. *J Med Microbiol* 44:79, 1996.

AUTHOR QUERY FORM

Dear Author

During the preparation of your manuscript for publication, the questions listed below have arisen. Please attend to these matters and return this form with your proof.

Many thanks for your assistance.

Query References	Query	Remarks
1.	AU: Pls spell out author's last name.	
2.	AU: Pls spell out author's last name.	