

The Quality of Root Canal Preparation and Root Canal Obturation in Canals Treated with Rotary *versus* Self-adjusting Files: A Three-dimensional Micro-computed Tomographic Study

Zvi Metzger, DMD,^{*†} Raviv Zary, DMD,[†] Raphaela Cohen, DMD,[†] Ehud Teperovich, DMD,[†] and Frank Paqué, DMD[‡]

Abstract

Aim: The study was designed to quantitatively evaluate the quality of root canal preparation and root canal obturation in canals treated with either rotary or self adjusting files, using three-dimensional micro-computed tomographic (CT) analysis. **Methodology:** Pair-matched root canals were instrumented with either rotary nickel-titanium files or self-adjusting files following the manufacturers' instructions. The area of the canal wall unaffected by the preparation procedure was analyzed using before and after micro-CT images. Root canal obturation was done using lateral compaction with gutta-percha and AH26 (Dentsply-DeTrey, Konstanz, Germany). Teeth were scanned a third time, and the adaptation of the filling material to the canal walls was evaluated three-dimensionally by micro-CT analysis and the area of canal wall untouched by the filling was determined. The correlation between these two parameters within each of the groups was studied using the Pearson correlation test. **Results:** A high percentage of unaffected root canal walls (60% \pm 14%) and areas untouched by the root canal filling (45% \pm 15%) were found in canals treated with rotary files. Both parameters were significantly smaller in canals treated with self-adjusting files (17% \pm 9% and 17% \pm 11%, respectively) ($p < 0.01$). No correlation was found between these parameters within each of the groups. **Conclusion:** Within the limitations of the present study, the self-adjusting files allowed better cleaning and shaping and better adaptation of the root canal filling than those allowed by rotary files. (*J Endod* 2010;36:1569–1573)

Key Words

MicroCT, obturation, root canal filling, SAF, self adjusting file

Root canal obturation is an essential stage of root canal treatment aimed to seal the root canal in order to prevent future bacterial contamination/recontamination of the canal space (1). Many obturation methods have been introduced over the years, each attempting to provide a better seal of the root canal (2). All have in common the assumption that the root canal is properly cleaned and shaped before the obturation stage. It is assumed by all that if the root canal is not adequately prepared and if tissue remnants and debris are present along the walls, proper sealing may be jeopardized, even with the best root canal filling method (3, 4).

When simple, narrow, straight root canals with round cross-sections are considered, most current rotary nickel-titanium file systems will adequately clean and shape the canal with favorable results. The case is different in oval, flat, or curved root canals.

In flat root canals, rotary file systems often fail to adequately clean and shape the canal, leaving "fins" that may have not been prepared (2–4). In such a case, even warm gutta-percha obturation methods will fail to adequately seal the root canal (4). Clinical buccolingual radiographs will fail to detect such discrepancy.

Micro-computed tomographic (CT) studies by Peters et al (6) have further extended the understanding of the limitations of rotary file systems. They clearly showed that inadequate preparation also often occurs in curved root canals, even if they do not have a flat cross-section. In upper molars treated with the ProTaper system (Dentsply-Maillefer, Ballaigues, Switzerland), 49% (\pm 29%) of the canal wall was left untouched, even in the larger palatal canals (6). Again, two-dimensional, clinical periapical radiographs cannot disclose the discrepancies.

This led to the recent introduction of a new self-adjusting file (SAF), which not only adapts itself longitudinally to a curved canal, as most rotary nickel-titanium files do, but also adapts itself to the cross-section of the canal (5). Rather than machining each canal into one with a circular cross-section, it removes an even dentin layer from all around the root canal, thus respecting the shape of a given root canal rather than imposing a circular cross-section on every canal no matter what its shape (5). Recent micro-CT analysis of root canals prepared with this new file indicated that this new technology allows for a higher percent of the root canal surface to be affected by the procedure (5). The resulting apical size is usually at least equivalent to a #40 file.

From the *Department of Endodontology, The Goldschleger School of Dental Medicine, Tel Aviv University, Tel Aviv; †Redent-Nova Inc, Raanana, Israel; and ‡Department of Preventive Dentistry, Periodontology and Cariology, University of Zurich, Zurich, Switzerland.

Dr Ehud Teperovich, Dr Raphaela Cohen, and Dr Raviv Zary are employed by ReDent-Nova, manufacturer of the SAF file. Dr Zvi Metzger serves as a scientific consultant to the same company.

Address requests for reprints to Dr Zvi Metzger, School of Dental Medicine, Tel Aviv University, Ramat Aviv, Tel Aviv 69978, Israel. E-mail address: metzger@post.tau.ac.il.

0099-2399/\$0 - see front matter

Copyright © 2010 American Association of Endodontists.
doi:10.1016/j.joen.2010.06.003

Following the concept of the previously mentioned micro-CT analysis methods, a new method for quantitative three-dimensional analysis of the adaptation of root canal filling material to the canal walls was designed. This new method was applied in the present study to quantitatively evaluate and compare the results of instrumentation with an SAF to those obtained with nickel-titanium rotary files.

Materials and Methods

Experimental Design

The study was designed to compare two instrumentation methods using two three-dimensional parameters: (1) the quality of root canal cleaning and shaping, as expressed by the root canal wall area affected/unaffected by the procedure, and (2) the quality of obturation, as expressed by the percent of the root canal wall area (after preparation) touched/untouched by the root canal filling material.

Teeth

Teeth were selected from a large random collection of extracted human teeth that were recently extracted for reasons unrelated to the present study and kept in 10% buffered formalin. Both three-dimensional images and two-dimensional cross-sections obtained using micro-CT scanning were available for each tooth in this collection.

Ten pairs of roots were selected based on matching root canal morphology. These 20 roots included two mesial roots of lower molars, two distal roots of lower molars, six premolars, eight incisors, and two canines. Pair selection was based on visual similarity in shape, size, flatness, and curvature of the root canals, as seen in a set of three-dimensional micro-CT images of each of the roots. The two roots of each pair were randomly assigned to one of the two treatment groups (rotary files or SAFs).

Root Canal Cleaning and Shaping

Two file systems were used: rotary nickel-titanium files (ProTaper, Dentsply-Maillefer, Ballaigues, Switzerland) and SAFs (ReDent-Nova Ltd, Ra'anana, Israel). Each instrument was applied following its manufacturer's instructions.

Rotary Files

The rotary files (ProTaper) were operated with a handpiece attached to a speed- and torque-controlled motor (X-Smart, Dentsply-Maillefer) at 250 rpm. The sequence used was ProTaper S₁, S₂, F₁, F₂, and F₃ with RC-Prep (Premier, Plymouth Meeting, PA) used as a chelator/lubricant with each file. The canal was irrigated with 5 mL 3% NaOCl between the instruments. A final flush with 5 mL 17% EDTA was applied, followed by an additional flush with 5 mL 3% NaOCl to remove the EDTA, and the canal was dried using paper points.

SAF

The SAF (ReDent) was operated for 4 minutes using a GentlePower Lux 20LP KaVo handpiece, (KaVo, Biberach, Germany) adapted with a RDT3 head (ReDent-Nova, Raanana, Israel) (5). The micromotor rotation speed was set at 5,000 rpm, which resulted in an in-and-out operation of 5,000 vibrations per minute with an amplitude of 0.4 mm. The file was used with a manual in-and-out motion to the working length. Continuous irrigation was applied throughout the procedure (5) at 5 mL/min using a special irrigation apparatus (VATEA irrigation device, part of the SAF-System, ReDent); 3% NaOCl was used for irrigation during the first 3 minutes of the operation, followed by 1 minute of

irrigation with 17% EDTA. A final flush with 5 mL 3% NaOCl was used to remove the EDTA, and the canal was dried using paper points.

Micro-CT Evaluation of the Root Canal Preparation

Before preparation and scanning, each experimental tooth was mounted on scanning electron microscopy carriers (014001-T; Bal-Tec AG, Balzers, Liechtenstein) to allow exact repositioning in the scanning system. Specimens were scanned before and after preparation by using a commercially available micro-CT system (μ CT 40; Scanco Medical, Brüttisellen, Switzerland). Teeth were scanned at 70 kV and 114 μ A with an isotropic resolution of 18 μ m. Although the mounting device ensured almost exact repositioning of the specimens, superimposition was further calculated with newly developed software (IPL Register 1.01, Scanco Medical), as previously reported by Paqué et al. (7). The final exact superimposition of the teeth before and after preparation was with a precision better than one voxel.

Individual root canal models were reconstructed up to the level of the cemento-enamel junction using specially developed software (IPL V5.06B, Scanco Medical). Superimposition of the root canals before and after preparation enabled visualization and quantitatively three-dimensional evaluation of the amount of un-instrumented areas (Fig. 1). This parameter was expressed as a percentage of the number of static surface voxels of the total number of surface voxels.

Root Canal Obturation

Root canal obturation was performed using the lateral compaction technique with gutta-percha and AH26 sealer (Dentsply-DeTrey, Konstanz, Germany). A gutta-percha master cone (DiaDent, Almere, The Netherlands) was fitted with tug-back in each root canal. Sealer was placed into the canal using a lentulo spiral followed by insertion of the master cone to the predetermined working length. Nickel-titanium finger spreaders (Dentsply-Maillefer) were used to conduct the lateral compaction using XXF/ XF accessory cones (Sure-Endo, Paris, France). When no additional cones could be inserted, the gutta-percha mass was cut off 1 mm apical to the canal orifice using a heated plugger (Dentsply-Maillefer). The freshly cut surface was vertically condensed using a cold plugger (Dentsply-Maillefer). The sealer was then allowed to set for 4 days at 37°C and 100% humidity.

Evaluation of Obturation Quality by Three-Dimensional Micro-CT Analysis

Each tooth was subjected to a third micro-CT scan as detailed earlier. Differences in the radiopacity between the root canal filling and the root dentin allowed differentiation between the two. For each root, the filling material was three-dimensionally reconstructed and superimposed with the image of the root canal after cleaning and shaping. Superimposition of root fillings and the prepared root canals (third and second scanning) allowed a three-dimensional analysis of the areas of the root canal surface, which were touched/untouched by the root canal filling.

Statistical Methods

The area unaffected by instrumentation and the area untouched by the root canal filling of the two instrumentation groups were compared with each other using the Student *t* test. The one-tailed Pearson correlation test was used to study the correlation within each group between the unaffected surface in a given root canal and the area untouched by the root canal filling in the same canal.

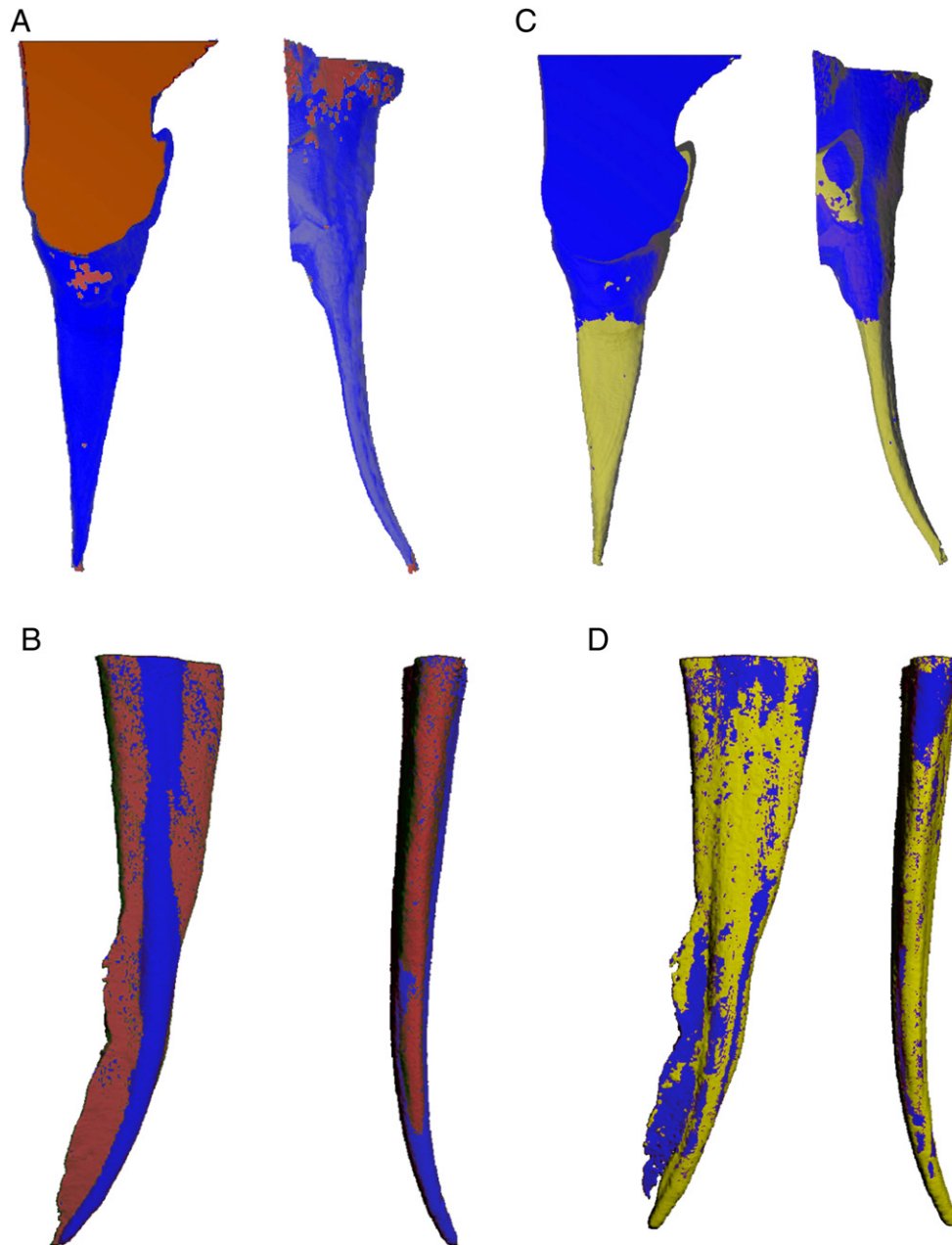


Figure 1. Three-dimensionally reconstructed micro-CT images of root canal preparation and obturation. (A) A flat root canal prepared with the SAF file. (B) A flat root canal prepared with a rotary file. (C) A good root canal filling adaptation with 98.1% of the canal wall in contact with the root canal filling material. (D) A poor root canal filling adaptation with only 68.9% of the root canal wall in contact with the root canal filling material. Note the uninstrumented lingual “fin” in B that was most probably full of debris, which prevented the sealer from flowing into it in D. Red: root canal surface before treatment. Blue: root canal surface post-treatment. Yellow: area touched by the root canal filling. Right, in each panel: buccal view, left: distal view. (resolution = 18 μm). (This figure is available in color online at www.aae.org/joe/.)

Results

Percent Root Canal Surface Unaffected by Root Canal Preparation

The root canal surface unaffected by root canal preparation was calculated as a percent of the root canal surface area before preparation (Table 1 and Fig. 1A and B). A wide range of this three-dimensional parameter was recorded, between 5.3% and 76.6%. The mean unaffected area was 16.7% ($\pm 8.9\%$) and 60.2% ($\pm 13.6\%$) in the self SAF and rotary file groups, respectively (Fig. 2).

Percent Root Canal Surface After Preparation Untouched by the Root Canal Filling Material

The root canal surface untouched by the root canal filling material was calculated as a percent of the root canal surface area after root canal preparation (Table 1 and Fig. 1C and D). A wide range of this parameter was recorded, between 1.9% and 75.1%. The mean area untouched by the root canal filling was 17.0% ($\pm 11.0\%$) and 44.6% ($\pm 14.5\%$) in the SAF and rotary file groups, respectively (Fig. 2).

TABLE 1. A Three-Dimensional Micro-CT Analysis of the Quality of Cleaning and Shaping and Root Canal Filling Adaptation to the Canal Walls

Pair #	Type of canal	Method	Area unaffected by root canal preparation (%)	Area untouched by root canal filling (%)
1	R-S	RF	66.7	28.9
		SAF	14.9	1.9
2	R-S	RF	64.4	64.3
		SAF	7.1	15.8
3	R-S	RF	49.4	42.4
		SAF	20.8	8.5
4	R-C	RF	28.0	38.8
		SAF	33.8	23.5
5	R-C	RF	76.6	37.6
		SAF	5.3	5.8
6	F-S	RF	63.0	44.1
		SAF	21.6	30.5
7	F-S	RF	73.0	75.1
		SAF	5.8	15.1
8	F-S	RF	60.9	47.0
		SAF	20.2	8.0
9	F-S	RF	59.3	37.1
		SAF	21.1	29.4
10	F-C	RF	61.1	31.1
		SAF	15.9	31.2

R-S, round cross-section, straight; R-C, round cross-section, curved; F-S, flat cross-section, straight; F-C, flat cross-section, curved; RF, Rotary files.

Correlation Between the Area Unchanged by the Root Canal Preparation and the Area Untouched by the Root Canal Filling

No correlation was found within each of the groups between the percent of the area unaffected by the root canal preparation and the area untouched by the root canal filling.

Discussion

Many obturation methods are used today, ranging from traditional lateral compaction to a variety of heat-softened gutta-percha techniques. All are aimed at providing a good adaptation of the root canal filling material to the canal walls, thus ensuring an adequate seal that

will prevent bacterial contamination/re-contamination of the root canal system.

When applied in adequately prepared canals with no tissue remnants and with a clean, prepared dentin surface, this goal may be rather easily achieved. The case may be different in root canals that were inadequately cleaned and shaped. Tissue and debris remaining in parts of the canal that were unaffected by the procedure may present a barrier that does not allow for the root canal filling to intimately touch the root canal wall, thus forming the weakest link in the chain of steps aimed to properly seal the canal.

This may happen in curved canals in which the files failed to touch some of the walls (6) but constitutes an even greater problem in the case of flat or ribbon-shaped canals. In these canals, a rotary nickel-titanium file alone may be unable to adequately prepare the canal (Fig. 1B and D). Its action may result in a canal prepared to accommodate a certain thickness of master cone or root canal filling but may allow for buccal and/or lingual “fins” full of tissue remnants and debris to remain untouched (3, 4). These buccal and/or lingual defects may go unobserved in regular periapical radiographs; the root canal filling that is present in the central part of the canal will most likely mask them. Bacterial retention in or penetration into and through these defects may result in endodontic failure in an apparently radiographically acceptable case.

Even though the relation between the quality of cleaning and shaping and the potential of the root canal filling to intimately touch the walls of the prepared root canal is readily understood, it has never, to the best of our knowledge, been established quantitatively for the whole canal. A study aimed to investigate the correlation between these parameters calls for a high variety of root canal cleaning and shaping scores that could later be analyzed against root canal filling adaptation to the walls of the same canals.

The roots selected for the present study intentionally included a random variety of root canal morphologic shapes. This was done so that a wide spectrum of cleaning and shaping results would be available for analysis. These roots ranged from simple straight root canals with a round cross-section, which were likely to score high in effective cleaning and shaping using any file system, to curved roots or those with flat root canals that were likely to result in a higher

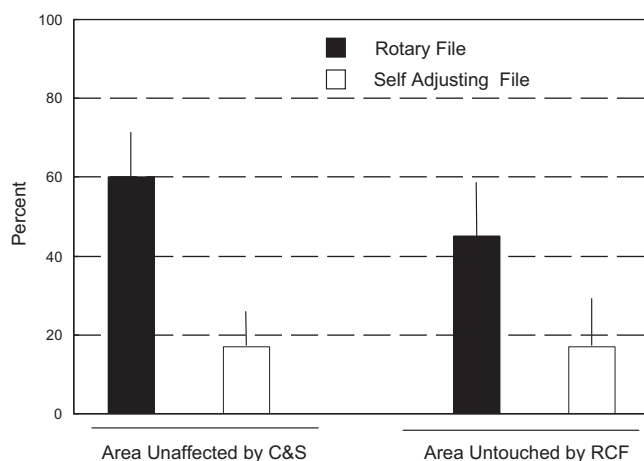


Figure 2. Comparison between the quality of the root canal preparation and adaptation of the root canal filling in root canals treated with rotary files or SAFs. The quality of root canal preparation is expressed as a percent of the root canal surface that was unaffected by the file. Adaptation of the root canal filling is expressed as a percent of the root canal surface after preparation that was untouched by the root canal filling. RCF, root canal filling; C&S, cleaning and shaping.

percent of root canal wall unaffected by rotary nickel-titanium files (5, 6).

The present study clearly showed that the two instrumentations groups differed from each other. This difference was found in both the quality of cleaning and shaping, as expressed by the percent of the root canal surface affected/unaffected by the procedure, and in the quality of root canal obturation, as expressed by the percent of the canal wall that is/is not in intimate contact with the root canal filling material. Treatment with the SAF allowed for better results with both parameters (Fig. 2).

No correlation could be found between the two parameters within each group. This could result from the relatively small number of specimens in each of the groups. Further studies with larger groups may be needed to establish such correlation.

Lateral compaction was used in the present study because it is the most commonly used obturation method. It may be of interest to test the same concept with heat-softened gutta-percha obturation methods, which are commonly expected to provide a better adaptation to the canal walls; nevertheless, this was beyond the scope of the present study.

Micro-CT scanning has been used previously to evaluate the quality of root canal fillings. Jung et al (7) have shown that the root canal filling may be differentiated from the canal wall in a micro-CT scan using digital root slices. Former studies of root canal obturation quality commonly used two-dimensional analysis of either root slices (7–10) or digital cross-sections generated from micro-CT scans (7). These could at best serve as a semiquantitative representation of what happens in the canal at large.

A three-dimensional analysis of micro-CT images, similar to the one used in the present study, was first applied by Zakizadeh et al (11) to evaluate intraorifice barriers. It was also recently applied by Hammad et al (12) for the analysis of the volume of voids and gaps present in root canal fillings.

The present study was, to the best of our knowledge, the first to use a three-dimensional micro-CT analysis to quantitatively measure the adaptation of the root canal filling material to the walls in the whole canal. As such, it provides far more comprehensive information about the adaptation of the whole root canal filling, which is unaffected by the choice of the plane in which a given section or digital cross-section happens to be.

Conclusions

A micro-CT-based quantitative three-dimensional method for analysis of root canal filling adaptation to the canal walls was presented. It may serve as a useful tool to study and compare the quality of root canal fillings. Within the limitations of the present study, the SAFs allowed better cleaning and shaping and better adaptation of the root canal filling than those allowed by rotary files.

Acknowledgment

The contribution of Mr Ofer Shalev to this study is recognized and highly appreciated.

References

1. Ricucci D, Lin LM, Spångberg ISW. Wound healing of apical tissues after root canal therapy: a long-term clinical, radiographic, and histopathologic observation study. *Oral Surg Oral Med Oral Pathol Oral Radiol Endod* 2009;108:609–21.
2. Whitworth J. Methods of filling root canals: principles and practice. *Endod Topics* 2005;12:2–24.
3. Wu M-K, Wesselink PR. A primary observation on the preparation and obturation in oval canals. *Int Endod J* 2001;34:137–41.
4. De-Deus G, Gurgel-Filho ED, Magalhães KM, et al. A laboratory analysis of gutta-percha-filled area obtained using Thermafil, System B and lateral condensation. *Int Endod J* 2006;39:378–83.
5. Metzger Z, Teperovich E, Zary R, et al. Respecting the root canal: a new concept of a Self Adjusting File (SAF). *J Endod* 2010;36:679–90.
6. Peters OA, Peters CI, Schönenberger K, et al. ProTaper rotary root canal preparation: effects of root canal anatomy on final shape analyzed by micro CT. *Int Endod J* 2003;36:86–92.
7. Jung M, Lommel D, Klimek J. The imaging of root canal obturation using micro-CT. *Int Endod J* 2005;38:617–26.
8. Paqué F, Laib A, Gautschi H, et al. Hard-tissue debris accumulation analysis by high-resolution computed tomography scans. *J Endod* 2009;35:1044–7.
9. Ardila CN, Wu M-K, Wesselink PR. Percentage of filled canal area in mandibular molars after conventional root canal instrumentation and after noninstrumentation technique (NIT). *Int Endod J* 2003;36:591–8.
10. Wu M-K, van der Sluis LWM, Wesselink PR. A preliminary study of the percentage of the gutta-percha-filled area in the apical canal filled with vertically compacted warm gutta-percha. *Int Endod J* 2002;35:527–35.
11. Zakizadeh P, Marshal SJ, Hoover CI, et al. A novel approach in assessment coronal leakage of intraorifice barriers: a saliva leakage and micro-computed tomography evaluation. *J Endod* 2008;34:871–5.
12. Hammad M, Qualtrough A, Silikas N. Evaluation of root canal obturation: a three-dimensional in vitro study. *J Endod* 2009;35:541–4.