

Enhancement of Healing Kinetics of Periapical Lesions in Dogs by the Apexum Procedure

Zvi Metzger, DMD,^{*†} Ronen Huber, DMD,[‡] Idan Tobis, BSc (Eng),[‡] and Hadar Better, MD, DMD[‡]

Abstract

In nonsurgical endodontic procedures, the healing of apical periodontitis is achieved by treatment provided within the root canal system. The new Apexum procedure is based on advancing the debridement one step further by minimally invasive removal of the inflamed periapical tissues through root canal access, thereby enhancing the healing kinetics of periapical lesions. The Apexum procedure uses 2 sequential rotary devices designed to extend beyond the apex and to mince periapical tissues on rotation in a low-speed handpiece, followed by washing out the minced tissue. This initial animal study was conducted to evaluate the efficacy and potential adverse effects of this procedure. Periapical lesions were induced in the lower premolars in dogs by placement of autologous dental plaque and subsequent radiographic verification. Fifty roots with periapical lesions were then subjected to cleaning, shaping and disinfection of their root canals, using a conventional root canal treatment protocol. Teeth in group 1 were subjected to the new Apexum procedure just before obturation, whereas roots in group 2 were subjected to no additional intervention before obturation. Clinical and radiographic follow-ups were carried out for 6 months. Radiographic healing of the periapical lesions in dogs at 3 and 6 months showed significantly enhanced kinetics in the Apexum-treated group compared with the conventional treatment group, at both time points ($p < 0.01$). No noticeable adverse events occurred in either of the groups. This new procedure might significantly enhance healing kinetics of apical periodontitis compared with conventional nonsurgical endodontic treatment. (*J Endod* 2009;35:40–45)

Key Words

Apexum, healing, minimally invasive, periapical lesions

From the *Department of Endodontology and †Department of Oral Biology, Goldschleger School of Dental Medicine, Tel Aviv University, Tel Aviv; and ‡Apexum Ltd, Or Yehuda, Israel.

Address requests for reprints to Zvi Metzger, Department of Endodontology, School of Dental Medicine, Tel Aviv University, Ramat Aviv, Tel Aviv 94778, Israel. E-mail address: metzger@post.tau.ac.il.

0099-2399/\$0 - see front matter

Copyright © 2008 American Association of Endodontists. doi:10.1016/j.joen.2008.10.002

The ultimate goal of endodontic treatment, when applied to teeth with periapical lesions, is to induce complete bony healing of the lesion and restoration of the periodontal ligament. Achieving this goal often requires up to 24 months, and even then, it is achieved in only 72%–87% of the cases (1, 2). A reliable, evidence-based estimation as to which case will heal and which will not cannot be made until after 12 months have passed (2). In an extensive retrospective study, Ørstavik (2) concluded that (1) at 6 months, only 50% of the cases that will eventually heal show clear signs of healing (advanced healing + complete healing), and (2) at 12 months, 88% of the lesions that will eventually heal will show clear signs of healing.

This might imply that a case should ideally be followed for 6–12 months before the tooth might be considered as a safe abutment. Such a time schedule for monitoring and defining healing versus nonhealing outcomes is difficult to follow in everyday clinical practice. Both the dentist and the patient are eager to finish the case with a permanent restoration as soon as possible. In everyday practice, this evidence-based concept is commonly ignored, which is considered unavoidable.

On the other hand, healing is much faster when the periapical inflammatory tissue is removed during apical surgery (3). This difference in healing kinetics might be due to long-lasting activation of macrophages in the periapical lesion that persists long after access of the etiologic agents has been eliminated by root canal treatment (4, 5). Surgical removal of the periapical, chronically inflamed tissue allows a fresh blood clot to form, thereby converting a chronic inflammatory lesion into a new granulation tissue where healing might proceed much faster (4, 5). If apical surgery was applied to every case of apical periodontitis, healing would undoubtedly show enhanced kinetics. Nevertheless, surgery for every case of apical periodontitis is not recommended and is unjustified (6, 7).

The basic concept of treatment of apical periodontitis is one of debridement, disinfection, and entombment. This process is commonly carried out as far as the working length, ie, 0.5–1.0 mm short of the apical foramen, to maintain the apical constriction (8, 9). The Apexum protocol was designed to carry the debridement concept one step further into the apical foramen proper and beyond it into the periapical lesion itself (5). This is accomplished through a root canal access by using a procedure that is minimally invasive compared with open flap surgery. This new procedure has been designed to be applied during, and as a supplementary stage to, conventional root canal treatment. It is aimed to add to such treatment the faster healing kinetics that typically occurs with apical surgery, but without the use of scalpels, periosteal elevators, or sutures.

This new approach represents a shift from the current endodontic paradigm because it does not limit the endodontic intervention to the removal of the cause (bacteria), but instead it enters the periapical lesion beyond the apical foramen to convert a chronic lesion into new granulation tissue and promotes tissue repair. Because extension of instruments into apical tissues might result in a flare-up or increased postoperative symptoms (10, 11), a preliminary animal study was essential before conducting a clinical trial. The present study was aimed to initially assess the safety and efficacy of the new Apexum procedure in the treatment of induced periapical lesions in dogs.

Materials and Methods

Animals

The study was performed on eight 1-year-old beagle dogs. The protocol was approved by the animal care committee at Szent Istvan University, Budapest. All exper-

iments were conducted under the supervision of a veterinarian who also followed the dogs' behavior and well-being in the days after the procedures. For each procedure, dogs were anesthetized with intravenous 1.0 mg/kg diazepam and 10 mg/kg ketamine followed by 3% halothane via inhalation. Anesthesia was maintained with 1% halothane afterward. Analgesia during the procedure was achieved with intravenous 0.1 mg/kg butorphanol.

Induction of Apical Periodontitis

Periapical lesions were induced in the 3 mandibular premolars on both sides. The pulp chambers and root canals were opened, and the pulp tissue was removed. It is well-recognized that the dog has root canal systems that do not have a single major apical foramen but end apically with a delta-type ramification. Because the present study required a root canal that simulates apical anatomy of the human tooth, an artificial canal was formed in the apical part of each canal as previously reported by Holland et al. (12).

A #15 K file was mechanically altered to have a sharp, active tip. This instrument was forced into the apical delta with a watch-winding movement and apical pressure until it reached the apical periodontium, as determined by using an electronic apex locator. The apical canal was then gradually enlarged by using K files until a #30 file reached the apical periodontium, thus establishing an artificial main apical part for the root canal. The new opening was referred to as the new apical foramen.

Autologous dental plaque was then collected and placed in the canal, and the coronal opening of each canal was sealed separately with glass ionomer cement (GIC) for 11–14 weeks. The development of periapical lesions was verified radiographically. Fifty such infected root canals with periapical lesions were then subjected to endodontic treatment. All radiographs were taken by using a digital sensor (Schick Technologies, Long Island City, NY). Because of technical difficulties such as thickness of the sensor and lack of sufficient depth at the floor of the dog's mouth, no bite blocks were used.

The Apexum Devices

The Apexum procedure uses 2 devices, the Apexum NiTi Ablator (Fig. 1) and Apexum PGA Ablator (Fig. 2), designed to be used sequentially. Both instruments are for single use. The devices are manufactured by Apexum Ltd, Or Yehuda, Israel. They are not yet commercially available but are being evaluated in clinical trials.

The Apexum NiTi Ablator consists of a specially preshaped nitinol wire with a 0.18-mm diameter. One end is bent and is designed to enter the periapical tissues through the root canal and apical foramen, whereas its other end has a latch-type connector to allow for operation by a low-speed contra-angle handpiece. The bent part is initially concealed in a straight, superelastic nitinol tube with a 0.45-mm diameter (Fig. 1A) that serves as a sheath, allowing its introduction along the root canal up to the working length, where the sheath reaches its apical stop. When pushed, the wire emerges from its sheath (Fig. 1B) and through the apical foramen and resumes its preshaped form (Fig. 1C). The special retrograde design of the bent part (Fig. 1D) allows it to rotate in the periapical soft tissues and coarsely grind them while being deflected from the surrounding bone. The nitinol sheath is designed to allow the introduction of the pre-bent nitinol wire to the apical foramen and then to allow unobstructed rotation of the wire in the root canal without twisting on itself.

The second device is the Apexum PGA Ablator, built from a nitinol shaft with a 0.45-mm diameter and equipped on one end with a latch-type connector to allow for operation by a low-speed contra-angle handpiece (Fig. 2). At the other end, a bioabsorbable filament of polyglycolic acid (a 6-0 absorbable surgical suture) is attached, which is




Figure 1. The Apexum NiTi Ablator. (A) The Apexum NiTi Ablator contained in its sheath. (B) The Apexum NiTi Ablator partially extruded from its sheath. (C) The Apexum NiTi Ablator fully extruded from its sheath. (D) Enlargement of the active part of the Apexum NiTi Ablator.

designed to enter the periapical bony crypt and rotate there, turning the tissue that was initially minced with the NiTi Ablator into a thin suspension that might be washed out through the root canal.

Experimental Design

A total of 50 roots with periapical lesions and reasonably preserved tooth structure were randomly assigned to either the conventional treatment or the Apexum-treated groups. The unit of randomization was a single root with a periapical lesion. Therefore, the same dog had roots belonging to the 2 different groups, and 2 roots of the same tooth often belonged to different groups.

Conventional Treatment Group

Each root was radiographed by using nonstandardized methods before treatment. Conventional endodontic treatment was performed. This included cleaning and shaping of the root canals by using nickel-titanium (NiTi) rotary endodontic files and endodontic hand files. NaOCl (3%) was used as an endodontic working solution and irrigant. Each root was prepared up to a #45–50 K file to a working length 1 mm short of the new apical foramen, which was determined by using an apex locator. This resulted in an artificial apical constriction, referred to thereafter also as an apical stop. The canal was dried with sterile paper




Figure 2. The Apexum PGA Ablator.

points, and root canal filling was performed by using lateral condensation with gutta-percha and AH-26 sealer. An external filling of GIC was placed to seal the coronal access cavity. Each root was radiographed again postoperatively.

Apexum-treated Group

Each root was radiographed before treatment; thereafter it was subjected to conventional endodontic procedure as described above, up to the stage that the root canal was ready for obturation. The apical foramen was then gradually enlarged up to a #35 K file to allow access into the periapical lesion. The NiTi Ablator, in its sheath, was inserted into the root canal up to the pre-prepared apical stop (1 mm short of the new apical foramen). A periapical radiograph was taken to ensure that the NiTi Ablator was in the correct position.

Holding the latch-type connector with 2 fingers, the NiTi Ablator was gradually pushed out of its sheath and into the periapical lesion. It was manually rotated to verify that it met no solid obstruction. The NiTi Ablator sheath was then secured to the tooth crown and stabilized by using composite resin or GIC. Next, the NiTi Ablator was connected to a contra-angle, low-speed handpiece and rotated in the periapical lesion for 30 seconds at 200–250 rpm. The Apexum Ablator sheath was then disconnected from the tooth, either by applying light force with forceps

or by gently touching with a high-speed drill around the cement margins. The NiTi Ablator was removed from the root canal system while still being connected to the contra-angle handpiece, and the blade was inspected if deformed or broken. The root canal was thoroughly rinsed with saline to remove debris. Each device was used once.

The PGA Ablator was then manually introduced through the root canal and into the lesion and then connected to the contra-angle handpiece and rotated for 30 seconds at 5000–7000 rpm. It was thereafter removed from the root and inspected for deformity or tear. Each device was used once.

The periapical bony crypt was thoroughly washed with saline that was gently administered by using a syringe with a 30-gauge needle that passed through the apical foramen. This was done while continuously visually monitoring the backflow to prevent excessive pressure from building up in the periapical crypt. The root canal was dried with sterile paper points, and root canal filling was performed by using lateral condensation with gutta-percha and AH-26 sealer. External filling of GIC was placed to seal the coronal access cavity. Finally, the root was radiographed again postoperatively.

Each dog was closely followed by a veterinarian for any signs indicating pain, distress, or swelling. These were judged by daily observation of the dog’s appearance, behavior, and feeding habits by an experienced veterinarian.

Radiographic Follow-up

Follow-up radiographs were taken under general anesthesia at 3 and 6 months. Radiographs were examined as a sequence of immediate postoperative and follow-up radiographs and evaluated independently by 3 observers whose evaluations were calibrated before the examination. All observers were blinded to the group to which a given root belonged. Four categories were used: (1) No Healing: no reduction in the size of the lesion or enlargement of the lesion; (2) Minor Healing: a clear but minor decrease in the size of the lesion; (4) Advanced Healing: a substantial decrease in the size of the lesion but not a complete healing; and (4) Complete Healing: the lesion disappeared completely. Some remaining widening of the periapical periodontal ligament was also considered as complete healing. This ordinal scoring system was developed and used because these categories were easily distinguished from each other and yet provided detailed information on healing events in the periapical lesions.

When all 3 observers independently agreed, the result was registered. When disagreement occurred, the case was discussed, and a common decision was taken, with all observers still blinded to the group to which the discussed root belonged. The scores were later dichotomized (13–15) so that No Healing and Minor Healing were considered together as Nonhealing, whereas Advanced Healing and Complete Healing were considered together as Healing.

Statistical Analysis

Safety was evaluated by monitoring for treatment-related adverse events. Efficacy was evaluated by monitoring the healing of the lesions at 3 and 6 months, determined by using the 4-score scale described above, dichotomized for each tooth into Healing or Nonhealing. Chi-square and Fisher exact test were applied for testing the statistical significance of healing at 3 and 6 months, comparing between the Apexum-treated

TABLE 1. Periapical Healing Scores at 3 Months

	No Healing	Minor Healing	Advanced Healing	Complete Healing
Experimental	0/24 (0%)	7/24 (29%)	11/24 (46%)	6/24 (25%)
Control	13/22 (59%)	2/22 (9%)	2/22 (9%)	5/22 (23%)

TABLE 2. Periapical Healing Scores at 6 Months

	No Healing	Minor Healing	Advanced Healing	Complete Healing
Experimental	1/21 (5%)	0/21 (0%)	7/21 (33%)	13/21 (62%)
Control	7/22 (32%)	2/22 (9%)	4/22 (18%)	9/22 (41%)

group and the conventional treatment group. All tests applied were 2-tailed, and a *P* value of 5% or less was considered to be statistically significant. The data were analyzed by using the SAS software version 9.1 (SAS Institute, Cary, NC).

Results

A total of 8 beagle dogs were recruited. Eighty roots were initially subject to the periapical lesion induction procedure. Periapical inflammatory lesions developed in 80% of the roots. Some teeth were lost as a result of fracture or loss of the filling. Of the 80 roots subjected to this procedure, 50 met the inclusion criteria for entry into the study by the radiographic presence of periapical lesions and clinical presence of structural integrity and retained temporary filling. By 3 months, 24 of the initial 25 roots in the Apexum-treated group were present for evaluation, whereas in the conventional treatment group 22 of the initial 25 were available. By 6 months, 21 and 22 roots were available for evaluation in the Apexum-treated and conventional treatment groups, respectively. The missing roots were lost as a result of fractures.

Adverse Events

No adverse events were recorded in either the Apexum-treated or conventional treatment groups. More specifically, none of the dogs in either group developed swelling or showed signs in its behavior and feeding habits that could indicate that it was in pain or distress.

Mechanical Failure

None of the NiTi Ablators or the PGA Ablators was broken during the treatment procedure in the Apexum-treated group.

Radiographic Follow-up

Healing scores at 3 and 6 months are presented in Tables 1 and 2. The dichotomized Healing data are presented in Fig. 3.

At 3 months, 71% of the roots in the Apexum-treated group were in the Healing category (Advanced Healing + Complete Healing) (Fig. 3). At this time point, only 32% of the lesions in the conventional treatment

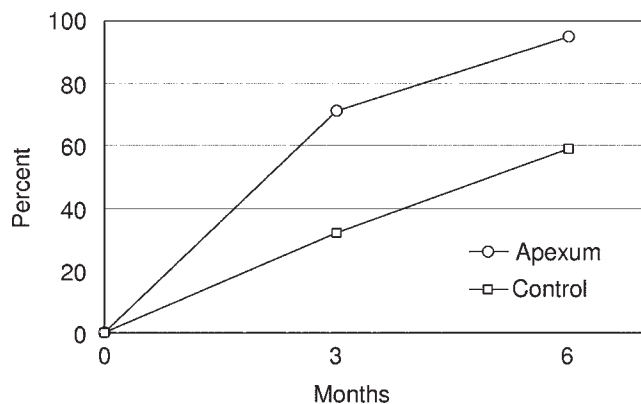


Figure 3. Kinetics of periapical healing: Apexum-treated lesions vs conventional treatment. Percent of lesions presenting with Healing (Advanced Healing + Complete Healing) at 3 and 6 months. Circles, Apexum-treated group; squares, conventional treatment group.

group presented with Healing. This difference was statistically significant ($P < .01$).

At 6 months, 95% of the roots in the Apexum-treated group were in the Healing category, whereas only 59% of the lesions in the conventional treatment group presented with Healing ($P < .01$).

Typical follow-up radiographs of periapical healing after the Apexum procedure are presented in Fig. 4. A case of nonhealing periapical lesion is presented in Fig. 5.

Discussion

A new approach for the treatment of periapical lesions was tested for its safety and efficacy by using periapical lesions in dogs as a model. Mature dogs' root canals do not naturally have a single major apical canal and apical foramen, but they commonly end apically in a delta-type ramification. Because the experimental procedure required a major apical foramen, such a foramen was artificially created in all roots at the stage of induction of apical periodontitis lesions (12). It is important to note that use of this procedure was conducted in both groups before inoculation with dental plaque; thus, both groups differed only in the assignment to the standard treatment versus standard plus Apexum treatments.

The Apexum procedure was performed on 25 roots without any mechanical failure. This was in accordance with previous durability bench tests in which the devices were extensively used in models of periapical crypts with no mechanical failure. Furthermore, the Apexum NiTi Ablator could be operated even at speeds up to 5000 rpm, which is 20 times higher than the speed used in the present study, without breaking (data not shown).

No clinical adverse events occurred in either the conventional treatment or the Apexum-treated groups. None of the dogs experienced swelling or gave indication of suffering from pain. Thus, it might be concluded that the Apexum protocol seems to be safe both mechanically and clinically.

It should be noted that the Apexum procedure is substantially different from simple overinstrumentation during root canal treatment. The latter traumatizes the tissue and might also introduce bacterial antigens into a tissue primed to respond to them (5). When this occurs, an acute inflammatory response with resulting edema is likely to occur in the periapical tissue; thus, symptoms or flare-up might be expected (10, 11). The Apexum procedure, on the other hand, did not end with just such a trauma, allowing the above events to occur. On the contrary, it might have removed the tissue in which such response could occur and allowed the crypt to be filled with a fresh blood clot in which the above mechanisms are not present. This might explain the quiet and uneventful postoperative behavior observed in the present study. The extent of tissue removal and the exact nature of the processes that follow will require further verification by histologic studies.

Healing kinetics is an important determinant in the treatment of periapical lesions. The current evidence-based clinical data indicate that it is not before 12 months that cases that are going to eventually heal can be distinguished from those that are not (2). Such a time schedule is difficult to follow in clinical practice.

Healing of similar lesions after apical surgery is much faster. Kvist and Reit (3) have demonstrated that lesions of apical periodontitis that

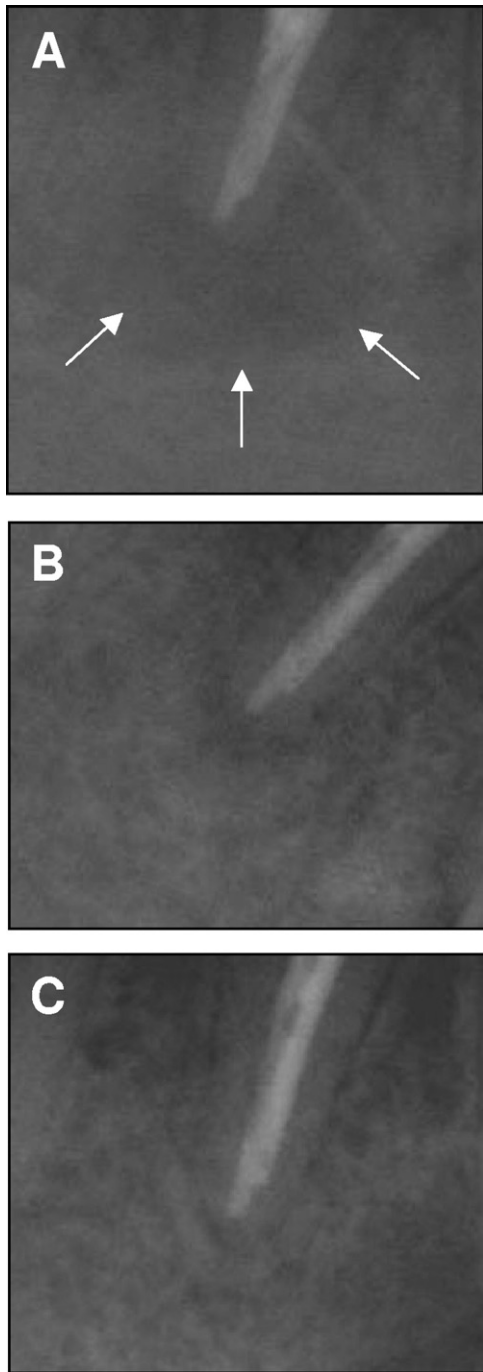


Figure 4. Healing of a periapical lesion after the Apexum procedure. A distal root of the dog's lower third premolar. (A) Postoperative radiograph; arrows indicate the size of the lesion. (B) Three-month follow-up: Advanced Healing (C). Six-month follow-up: Complete Healing.

were treated surgically healed with kinetics significantly faster than those treated with nonsurgical retreatment, even if both groups eventually showed similar healing rates after 48 months. Nevertheless, surgery is an invasive procedure associated with certain adverse effects (7). Therefore, it is not routinely used just to enhance the healing kinetics of periapical lesions.

In the current study, the healing of periapical lesions in the Apexum-treated group was significantly faster than in the conventional treatment group. This implies that adding the new procedure as a sup-

plementary stage in the process of conventional root canal treatment might alter the outcome, at least as far as the healing kinetics is concerned. Termination of the present study at 6 months does not permit any conclusion as to long-term healing rates. Such a conclusion would

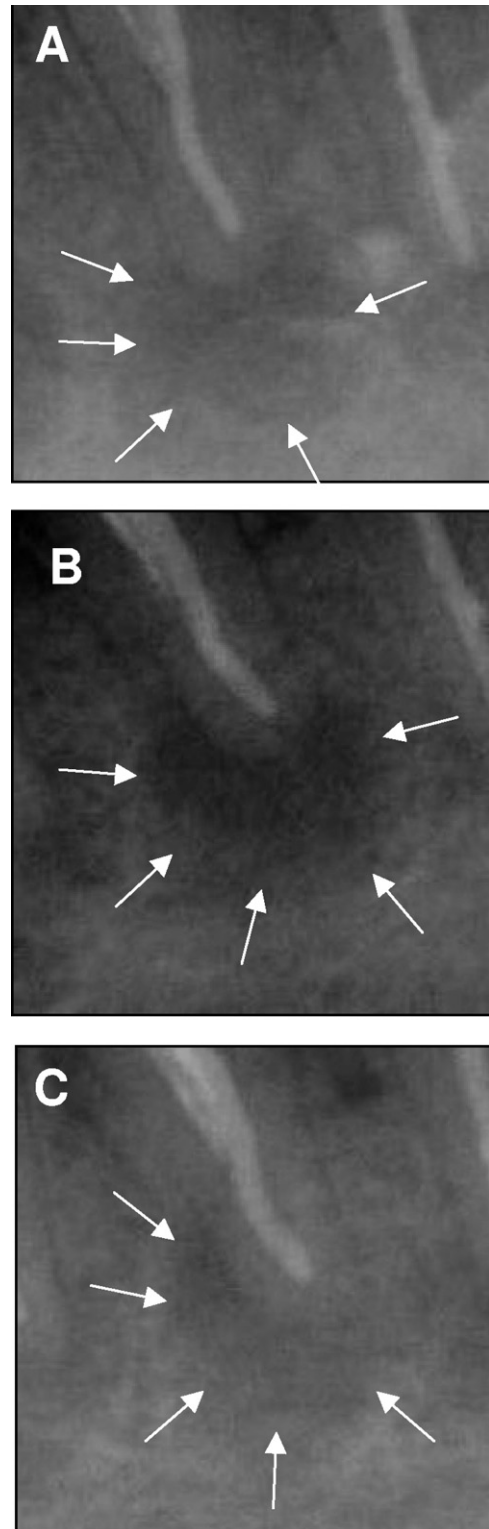


Figure 5. Nonhealing of a periapical lesion treated with conventional root canal treatment. A distal root of the dog's lower second left premolar. (A) Postoperative radiograph. (B) Three-month follow-up: No Healing. (C) Six-month follow-up: Minimal or No Healing. Arrows indicate the size of the lesion.

require longer follow-up periods that were beyond the scope of the present experiment.

The present study implies that the new Apexum protocol might allow significantly enhanced healing kinetics as compared with conventional root canal treatment ($P < .01$). This might be achieved with a favorable safety profile. Further clinical studies, which are currently in progress, might allow verification of these results in humans.

Acknowledgments

Drs Metzger and Better serve as scientific consultants to and Dr Huber and Mr Tobis are employed by Apexum Ltd. Apexum Ltd is the manufacturer of the instruments tested in this study and provided financial support for this study.

References

1. Figdor D. Apical periodontitis: a very prevalent problem. *Oral Surg Oral Med Oral Pathol Oral Radiol Endod* 2002;94:651–2.
2. Ørstavik D. Time course and risk analysis of the development and healing of chronic apical periodontitis in man. *Int Endod J* 1996;29:150–5.
3. Kvist T, Reit C. Results of endodontic retreatment: a randomized clinical study comparing surgical and nonsurgical procedures. *J Endod* 1999;25:814–7.
4. Metzger Z. Macrophages in periapical lesions. *Endod Dent Traumatol* 2000;16:1–8.
5. Metzger Z, Abramovitz I. Periapical lesions of endodontic origin. In: Ingle JI, Bakland LK, Baumgartner JC, eds. *Ingle's endodontics*. 6th ed. Hamilton, ON, Canada: B C Decker, 2008:494–519.
6. American Association of Endodontists. Appropriateness of care and quality assurance guidelines. 3rd ed. Chicago, IL: American Association of Endodontists; 1998.
7. Kvist T, Reit C. Postoperative discomfort associated with surgical and nonsurgical endodontic retreatment. *Endod Dental Traumatol* 2000;16:71–4.
8. Wein FS. *Endodontic therapy*. 6th ed. St Louis, MO: Mosby; 2004.
9. Wu M-K, Wesselink PR, Walton RE. Apical terminus location of root canal treatment procedures. *Oral Surg Oral Med Oral Pathol Oral Radiol Endod* 2000;89:99–103.
10. Siqueira J. Reaction of periradicular tissues to root canal treatment: benefits and drawbacks. *Endod Topics* 2005;10:123–47.
11. Baumgartner JC, Rosenberg PA, Hoen MM, Lin LM. Treatment of endodontic infections, cysts, and flare-ups. In: Ingle JI, Bakland LK, Baumgartner JC, eds. *Ingle's endodontics*. 6th ed. Hamilton, ON, Canada: B C Decker, 2008:690–712.
12. Holland R, Otoboni Filho JA, de Sousa V, Nery MJ, Bernabe PFE, Dezan E Jr. Calcium hydroxide and corticosteroid-antibiotic association as dressing in cases of bio-pulpotomy: a comparative study in dog's teeth. *Braz Dent J* 1998;9:67–76.
13. Trope M, Delano O, Ørstavik D. Endodontic treatment of teeth with apical periodontitis: single vs multivisit treatment. *J Endod* 1999;25:345–50.
14. Boucher Y, Matossian L, Rilliard F, Machtou P. Radiographic evaluation of the prevalence and technical quality of root canal treatment in a French subpopulation. *Int Endod J* 2002;35:229–38.
15. Friedman S. Prognosis of initial endodontic treatment. *Endod Topics* 2002;2:59–88.