

Case Selection for Apical Surgery: A Retrospective Evaluation of Associated Factors and Rational

Itzhak Abramovitz, DMD, Hadar Better, DMD, MD, MSc, Amit Shacham, DMD, Benjamin Shlomi, DMD, and Zvi Metzger DMD

Endodontic failures associated with poor quality of endodontics respond favorably to retreatment. Nevertheless, under certain clinical conditions, apicoectomy should be the preferred procedure. A retrospective survey of 200 roots that were referred for apical surgery revealed that 83% of the roots were inadequately obturated, including 8.5% with no root canal filling at all. In 49 of the roots in this group (24.5% of the referred cases) nonsurgical retreatment was judged by an endodontist as either impossible or improbable because it might jeopardize the root integrity. Retreatment should have been the preferred treatment modality for the rest of the group, provided that coronal restorations could be safely bypassed or removed. Posts were found in 63 of these teeth, however 35 of them were either short or loosely fitting and could safely be removed. The rest of the posts were longer than 5 mm, which might have presented a problem if their removal was attempted. In 45% of the 200 cases in the present study, surgical intervention was justified. The rest of the cases (55%) should have either been subjected to a follow-up (10.5%) or retreated nonsurgically by a skilled endodontist (44.5%). These results indicate that referring dentists may not appreciate the retreatment possibilities offered by modern endodontics, and they emphasize the need for a shift of concept: endodontists should be involved in the decision making before referring a patient to surgery.

Several surveys indicate that endodontically treated teeth are commonly associated with a high rate of periapical lesions and poor endodontic quality (1–3). The canals are frequently either under-prepared, under-filled, or both (1, 2). This type of failure usually responds most favorably to proper retreatment (4).

Therefore, according to the Appropriateness of Care and Quality Assurance Guidelines of the American Association of Endodontists (AAE), when such failures occur retreatment of the root canal

is the treatment of choice. Furthermore, according to these guidelines, surgical endodontics should be undertaken only when teeth cannot be treated appropriately by nonsurgical means (5).

el-Swiah and Walker classified reasons for apical surgery as biological, technical, or a combination of the two (6). The former include teeth with periapical involvement that did not respond favorably to proper endodontic treatment or the need to remove blocked, calcified, or transported segments of an infected root canal. The need to obtain a biopsy may also be included here.

Technical considerations include the presence of a crown or a post as well as the presence of broken instruments or silver points that may prevent access to the infected canal. Extremely curved canals and perforations that cannot be repaired from within the canal may also be included in this group.

Among these technical obstructions, a crown on an abutment tooth presents a unique problem, especially when a post is also present. Traditionally attempts to perform endodontic therapy through such a restoration were considered risky and were thought to potentially lead to disaster and were therefore not recommended (7). When removal of the restoration was not practical, apicoectomy became the only alternative.

The introduction of dental operating microscopes that provide magnification, co-axial illumination, and ultrasonic micro-instrumentation had a dramatic impact on the endodontist's ability to gain access through crowns and posts. They allow more conservative access cavities in crowns, better orientation during core removal, and safe removal of posts by drilling and ultrasonic manipulation (8, 9). This armamentarium also facilitates the removal of broken instruments and silver cones (9). Consequently, these developments have had a major impact on the definition of an obstruction that dictates surgery, and they have significantly improved the endodontist's ability to nonsurgically retreat failed endodontic cases (8).

Identification and negotiation of hidden canals, especially in mesiobuccal roots of upper molars and distal roots of lower ones, also became more predictable (8). With the aid of the new equipment, perforations can often be inspected and conservatively repaired from within the canal (10).

The introduction of nickel titanium instruments also changes definitions; they allow a better ability to axially prepare curved canals that were otherwise candidates for root-end resection because of the inability to properly instrument them. Consequently, the success rate dramatically improved, and incidence of ledges and perforations dropped (11, 12).

Many clinicians seem to be unaware of these major advantages provided by modern endodontics and may still advocate surgical treatment on grounds of old concepts.

The aim of the present study was to analyze and evaluate the factors associated with choosing a surgical rather than an ortho-grade approach to failed endodontic cases. A survey of patients referred to a central Oral Surgery Unit in a major Tel Aviv hospital was conducted with an attempt to determine the justification for these referrals in view of the possibilities offered by modern retreatment techniques.

MATERIALS AND METHODS

Two hundred roots of 189 patients referred to the Oral and Maxillo-Facial Surgery Unit at The Sorasky Medical Center for endodontic surgery during the yrs 1995–2000 were included in the present retrospective study. Patient records included the referral letter and radiograph, as well as the results of a clinical examination upon arrival, general medical status, chief complaint, history of the referred tooth, summary of the treatment provided before referral, and radiographic records.

Radiographs were examined by an endodontist (IA) and an oral surgeon (HB), and the following parameters were recorded: (a) type and quality of coronal restoration, if present; (b) type, quality, and length of post, if present; (c) quality of the root canal filling; (d) evaluation of the apical part of the root canal for apical perforations or blockage; and (e) existence and size of a periapical radiolucency. The clinical status of the referred tooth and of its periapical tissues were also recorded as evaluated by the oral surgeon before the surgical procedure.

Each of the above parameters (a–c) was classified as either adequate or inadequate using the following criteria: (a) crowns and coronal restorations were considered adequate if their margins were continuous with the tooth with no radiographically visible gaps or decay; (b) posts were considered adequate if they were placed along the axis of the root canal without radiographic gaps in the filling material between the post and the canal walls; and (c) root canal fillings were considered adequate when the root canals did not seem to be underprepared, either in length or in width, and when no voids were observed between the root canal filling and the canal walls.

The evaluation was done per root referred for surgery. In multi-rooted teeth, in which more than one root was referred to endodontic surgery, each root was recorded separately.

The endodontist when evaluating each of the cases with inadequate root canal fillings assessed the difficulty to provide a nonsurgical retreatment and assigned it to one of the following categories: (a) roots in which retreatment may be impossible or risky (because of blocked or transported canals, broken instruments, anatomy, etc.); and (b) roots in which retreatment would be feasible if the coronal obstruction (the restoration) could be passed. Roots with posts were divided into those longer than 5 mm (as measured on a radiograph beyond the cervical crown margins) and those shorter than 5 mm. The former were defined for the purpose of the present study as potentially presenting a risk if an attempt was made to remove or drill them.

Roots with adequate root canal fillings were defined as having either persisting clinical symptoms (such as sinus tract, pain, and sensitivity) or as having a recently performed, adequate, root canal filling and a reasonable chance for success if followed up.

For the sake of clarity and uniformity, all percentage data are expressed as a percent of the total 200 roots.

RESULTS

Among the 200 roots referred for apical surgery, 114 were diagnosed as chronic apical periodontitis, 62 had chronic abscesses, 17 had acute apical periodontitis, and seven had no radiographic periapical involvement and were asymptomatic. One hundred and forty of the teeth (70%) had crowns, and 80 of those had posts. Fifty-three teeth had fillings; nine with posts, and seven were open with no coronal restoration. Thirty-two crowns exhibited open margins on radiographs, whereas 22 posts justified replacement on grounds of an ill fit. All fillings were considered replaceable if needed.

One hundred and forty nine roots (74.5%) had inadequate root canal fillings, whereas 17 (8.5%) had no root canal filling at all. Thus, a total of 166 roots in these two groups (83%) had either inadequate root canal fillings (RCF) or no RCF at all (Fig. 1). The remaining 34 roots (17%) had adequate RCF. Thirteen of them (6.5%) had persisting clinical symptoms, whereas the other 21 (10.5%) had recently-done adequate RCF with no symptoms and should have been radiographically followed up rather than subjected to surgery.

In 49 of the roots with inadequate or no RCF (24.5%), conservative retreatment was judged as impossible or too risky. In the remaining 117 cases retreatment was considered possible, providing that the obstruction of the present restoration could be removed or bypassed. Among these roots, 63 (31.5%) had posts (with or without crowns), which could have been considered (by old criteria) an apparent obstruction that could have prevented retreatment. The remaining 56 roots (27.0%) had no apparent obstruction in the root canal; they had fillings only, crowns with no posts, or no restoration at all.

Among the 63 roots with posts, 28 (14%) had posts longer than 5 mm, whereas the rest had posts shorter than 5 mm or loosely-fitted posts that were considered a removable obstruction (in the hands of a qualified, adequately equipped endodontist).

When all the above considerations were taken together, endodontic evaluation of the 200 cases revealed that apical surgery was justified in 90 of the cases (45%). This group included (a) roots with recent, adequate, root canal fillings with persisting symptoms; (b) roots in which retreatment was judged impossible due to either broken instrument, calcification, transported canal, or perforation; and (c) roots with inadequate root canal fillings and posts longer than 5 mm (Fig. 1).

Referral for apical surgery was evaluated as unjustified in the remaining 110 cases (55%). These included roots for which only a follow-up was indicated at the time of referral, as well as roots that should have been referred to endodontic treatment: (a) roots with no root canal fillings; and (b) roots with inadequate root canal fillings and no indication that retreatment was not possible. Crowns and/or posts shorter than 5 mm were not considered as a significant obstruction.

DISCUSSION

Endodontic failures are mainly associated with the poor quality of either endodontic or restorative treatment (1–3, 13). Most (78%) failures respond favorably to adequate standard endodontic retreat-

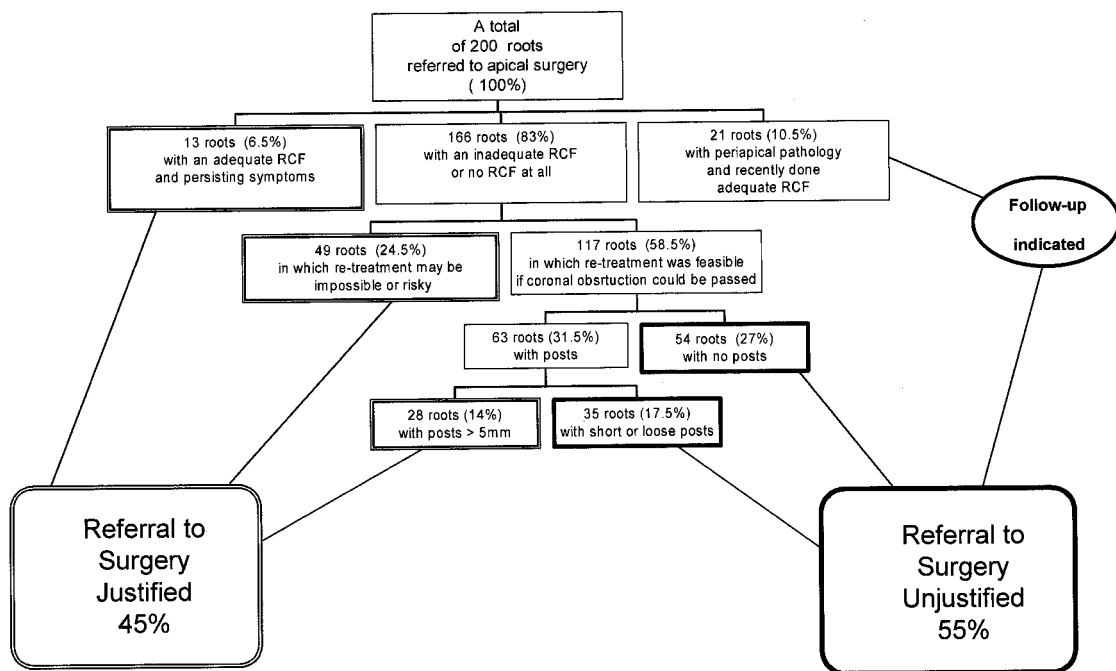


Fig 1. A flowchart analysis of factors associated with referral of 200 roots to apical surgery. Justification of the referral was judged from a point of view that takes into consideration modern retreatment methodology.

ment (14). The refractory cases that are a true indication for surgery may include treatment-resistant infection in the root canal or rare cases of cysts, extra-radicular infection, and possibly foreign body reaction (15).

Therefore, it has been recommended that retreatment should be preferred over endodontic surgery unless nonsurgical retreatment is not possible or the risk in retreatment is considered too high (16–18). Accordingly, the AAE recommends nonsurgical retreatment in cases where a deficiency in the quality of root canal obturation resulted in failure (5).

The AAE accepts endodontic surgery with retrofilling as the appropriate treatment modality in cases of (a) persistent symptoms or sinus tract resulting from inadequate seal that cannot be sealed by a nonsurgical approach; and (b) peri-radicular symptoms or pathosis and a blocked root canal system that cannot be obturated nonsurgically (5). These recommendations define neither what inability to seal by a nonsurgical approach is nor what type of blockage in the root canal system is a legitimate cause for this inability. They leave a wide range for clinical considerations and the judgment of the operator that may result in a large gray zone between justified and unjustified surgical interventions. Consequently, apical surgery may be performed too often, and may include cases that can now be safely handled by retreatment (18).

Poor quality of root canal obturation was previously reported in 53% to 58% of the general population (2, 3), although in patients referred to apicoectomy the percentage may reach 73% (6). In most of the cases in the present study (90%) endodontic failure could be attributed to poor quality of treatment such as under-prepared and under-filled root canals or teeth with no root canal fillings at all. This finding is in accordance with the results of Griev and McAndrew who found no root canal filling in 10% of teeth with post-retained crowns, whereas in 53% of teeth with post-retained crowns “the quality of endodontics was considered disappointing by any standards” (2). It could be expected that nonsurgical re-

treatment, if provided, would have successfully solved the problem in most of them (14).

Modern endodontic techniques improve the ability to successfully retreat such cases (8). Nickel titanium instruments can preserve the root axis significantly better than the traditional stainless steel files and improve the success rate (11). Underprepared or underfilled canals are common in teeth with endodontic failures (1–3). When this is the case, the canal walls and patency of the apical part may often be relatively preserved and may allow negotiation and preparation with modern nickel titanium instruments. This observation should be kept in mind and taken into consideration when weighing the prognosis of retreatment versus alternatives.

From a technical standpoint, crowns and posts were traditionally regarded as an indication for apical surgery. This may be expected because the literature in oral surgery often refers to posts and crowns in/on a tooth with endodontic failure as an indication for apical surgery (19). However, the dental operating microscope improved our ability to drill through crowns with minimal sacrifice of restoration material. Furthermore, predictable removal of posts, broken instruments, and silver points, with minimal or no alteration of the dentin walls, is a common reality (9, 10). Consequently, many of the cases that would have previously been defined as impossible or risky and that have been previously referred to endodontic surgery became candidates for a predictable nonsurgical retreatment.

A potential damage to ceramic restorations may also concern the referring dentist. Nevertheless, damage is unlikely to occur if proper diamond burs and water spray are used. Accordingly, it has been listed among false indications for preferring apical surgery to retreatment. Furthermore, any risk of this kind should be weighed against the risks of surgery (e.g. paresthesia in mandibular region), the risks for compromised esthetics due to gingival damage, and the risk of surgical failure.

The advancements in endodontic technologies stretch and widen the envelope of what can be defined as safely possible in a nonsurgical retreatment of failed endodontic cases. The definition of coronal obstruction (such as a crown and/or a post) should be reconsidered and redefined as relative, depending on the operator's training and skills and on the availability of proper instrumentation. What was conceived by the referring dentists in the present study as a coronal obstruction directed them, most probably, to choose apical surgery as the preferred treatment modality.

We suggest that crowns with no posts or with posts shorter than 5 mm should not be considered a technical obstacle that cannot be safely overcome. Seventy percent of the posts in the present survey were 5 mm or shorter. It is our opinion that most such posts may be safely removed by using ultrasonic devices, or by drilling under proper magnification with co-axial illumination.

The present results and suggestions are in agreement with those of Beckett who found a high incidence of unjustified apical surgery (18). He also concluded that when the post was such that it could be safely removed with a reasonable effort, surgery was unjustified.

The presence of a crown and/or post was defined by el-Swiah and Walker as a technical factor that indicated referral for apical surgery in almost half of the cases studied (6). Among them, 60% had posts and crowns, whereas 31% had crowns only. In the present study a technical factor was involved in the referral of 70% of the cases. Crowns with posts comprised 40% of the cases with technical factors, whereas crowns with no parts were found in 30% of these cases.

If the presence of a crown or post is considered an obstruction, almost 75% of the cases in our study were properly referred to surgery on grounds of technical reasons. Nevertheless, if a coronal filling with or without a post, a crown with no post, a crown with a post shorter than 5 mm, or a crown with an apparently loosely fitted post is not considered a real obstruction that justifies surgical intervention, only 14% of the cases should have been referred to surgery for technical reasons. These, in combination with the 31% of the cases that were properly referred to surgery for biological reasons, make up the 45% of the cases justifiably referred to surgery.

The study of el-Swiah and Walker analyzed cases referred to surgery in the yrs 1990–1992 (6). Over recent years major changes and improvements occurred in the methodology of retreatment as described above. Therefore it is of interest to indicate that in spite of these developments, in the 5 yrs that passed between their study and ours (1995–2000), no significant change occurred in patterns of referral to apical surgery.

It is frequently mentioned in the literature that the introduction of the surgical operating microscope has improved the results of endodontic surgery. Nevertheless, to the best of our knowledge, no study has yet established the long-term superiority of microscope-guided surgical treatment over modern nonsurgical retreatment in infected, poorly prepared root canals, in association with which most endodontic failures occur (2, 3). On the other hand, it has been demonstrated that canal debridement by nonsurgical retreatment before surgery resulted in a 91% success rate. This emphasizes the need to use all available tools in an effort to provide retreatment in endodontically failed cases prior to surgery.

The change in concept of what can safely be accomplished by a qualified, well equipped, modern endodontist is most likely yet

to occur and has therefore not filtered down to become common knowledge among dentists.

The importance of providing a high standard for endodontic and restorative treatment cannot be overemphasized. However in the case of endodontic failure before referral for surgery, consultation with an endodontist should be encouraged. Be it lectures, reports, or demonstrations, an increase and emphasis in communication throughout the dental community is necessary, to help reduce the extent of unneeded surgical interventions.

Dr. Abramovitz is affiliated with the Department of Endodontics, Hebrew University-Hadassa Faculty of Dental Medicine, Jerusalem and the Department of Oral Biology at the Goldschleger School of Dental Medicine at Tel Aviv University, Tel Aviv; Dr. Better is a senior surgeon and Dr. Schaham is a resident at the Oral and Maxillo-Facial Surgery Unit at the Sorasky Medical Center, Tel Aviv, Israel; Dr. Shlomi is affiliated with the Department of Maxillo-Facial Surgery at the Goldschleger School of Dental Medicine and is Deputy Director of the Oral and Maxillo-Facial Surgery Unit at the Sorasky Medical Center, Tel Aviv, Israel; Dr. Metzger is associate professor in the Departments of Oral Biology and Restorative Dentistry and is Director of Research Laboratories at the Goldschleger School of Dental Medicine at Tel Aviv University, Tel Aviv, Israel. Address requests for reprints to Dr. Itzhak Abramovitz, P.O. Box 11272, Jerusalem, Israel.

References

1. Saunders WP, Saunders EM, Sadiq J, Cruickshank E. Technical standards of root canal treatment in an adult Scottish sub-population. *Br Dent J* 1997;182:382–86.
2. Grieve AR, McAndrew R. A radiographic study of post-retained crowns in patients attending a dental hospital. *Br Dent J* 1993;174:197–201.
3. Buckley M, Spangberg LS. The prevalence and technical quality of endodontic treatment in an American subpopulation. *Oral Surg Oral Med Oral Pathol Oral Radiol Endodon* 1995;79:92–100.
4. Weine FS. Periapical surgery. In: Weine FS, ed. *Endodontic Therapy*. 5th ed. St. Louis: Mosby;1996:526.
5. Appropriateness of Care, and Quality Assurance Guidelines. (3rd). Am Association of Endodontists, 1998.
6. el-Swiah JM, Walker RT. Reasons for apicoectomies. A retrospective study. *Endodon Dent Traumatol* 1996;12:185–191.
7. Weine FS. Endodontics following complex restorative procedures. In: Weine FS, ed. *Endodontic Therapy*. 5th ed. St. Louis: Mosby;1996:816.
8. Carr GB. Retreatment. In: Cohen S, Burns RC, eds. *Pathways of the pulp*. 7th ed. St. Louis: Mosby;1998:791–834.
9. Nehme WB. Elimination of intracanal metallic obstruction by abrasion using an operating microscope and ultrasonics. *J Endodon* 2001;27:365–67.
10. Wong R, Cho F. Microscopic management of procedural errors. *Dent Clin North Am* 1997;41:455–79.
11. Sae-Lim V, Rajamanickam I, Lim BK, Lee HL. Effectiveness of Profile .04 taper rotary instruments in endodontic retreatment. *J Endodon* 2000;26:100–04.
12. Pettiette MT, Delano EO, Trope M. Evaluation of Success rate of endodontic treatment performed by students with stainless steel K-files and nickel-titanium hand files. *J Endodon* 2001;27:124–27.
13. Ray HA, Trope M. Periapical status of endodontically treated teeth in relation to technical quality of the root canal filling and the coronal restoration. *Int Endodon J* 1995;28:12–18.
14. Bergenholtz G, Lekholm U, Milthorpe R, Heden G, Odesjo B, Engstrom B. Retreatment of endodontic fillings. *Scand J Dent Res* 1979;87:217–24.
15. Pittford TR. Surgical treatment of apical periodontitis. In: Orstavik D, Pittford TR, eds. *Essential Endodontology. Prevention and treatment of apical periodontitis*. 1st ed. Oxford: Blackwell Science;1998:278–307.
16. Friedman S, Stabholz A. Endodontic retreatment—case selection and technique. Part 1: Criteria for case selection. *J Endodon* 1986;12:28–33.
17. Stabholz A, Friedman S. Endodontic retreatment - case selection and technique. Part 2: Treatment planning for retreatment. *J Endodon* 1988;14:607–14.
18. Beckett H. Impact of restorative dentistry service on prescription of apical surgery in a district general hospital. *Ann R Coll Surg Engl* 1996;78:369–71.
19. Molven O, Halse A, Grung B. Surgical management of endodontic failures: Indications and treatment results. *Int Dent J* 1991;41:33–42.
20. Zuolo ML, Ferreira MO, Gutman JL. Prognosis in periradicular surgery: A clinical prospective study. *Int Endodon J* 2000;33:91–8.