

Cracks and Fractures

ZVI METZGER | LOUIS H. BERMAN | AVIAD TAMSE

CHAPTER OUTLINE

Unobserved Trauma

Diagnostic Challenge

Fracture Mechanics

Cracked and Fractured Cusps

Definition

Diagnosis

Etiology

Treatment Planning

Cracked and Split Teeth

Definition

Diagnosis

Etiology

Treatment Planning

Vertical Root Fracture (VRF)

Definition

Diagnosis

Etiology

Treatment Planning

Summary

Root cracks and fractures can be two of the most frustrating aspects of endodontic and restorative dentistry. The diagnosis can be difficult; the symptoms can be either vague or specific, yet they are often insufficient for a definitive diagnosis; the radiographic evaluation can be evasive. Clinical management of the crack or fracture depends on its extent. Prevention of a potential crack or fracture is a fundamental principle, and early detection is imperative.

UNOBSERVED TRAUMA

Tooth fracture is commonly associated with impact trauma. A car accident, a fall from a bicycle, and an accidental blow to the face are among the common causes. These types of traumatic fractures mainly occur in the anterior segment of the mouth and are covered elsewhere in this book (see [Chapter 20](#)). In contrast, the cracks and fractures described in this chapter are often not associated with a traumatic event that the patient can remember. These cracks and fractures are frequently the result of an accumulating, unobserved trauma resulting from either normal or excessive occlusal forces that are repetitively applied^{22,34,45,47,70,71,90} without the patient's awareness.

DIAGNOSTIC CHALLENGE

Three categories of cracks and fractures are discussed in this chapter: cracked and fractured cusps, cracked and split teeth, and vertical root fractures. Each is often undiagnosed or misdiagnosed for a relatively long time.^{16,19,80} The astute clinician can usually diagnose a pulpitis, apical periodontitis, or an

abscess after appropriate diagnostic tests and clinical assessments are performed. However, because of the wide variety of clinical presentations from cracks and fractures, the diagnosis is less straightforward.^{16,18,78} To complicate the diagnosis, not one of the three entities necessarily exhibits a radiographic manifestation in the early stages, depriving the dentist of one of the most objective diagnostic tools.

Symptoms from one of these conditions may be present for *several months* before an accurate diagnosis is made,^{5,16,19} which may be frustrating for both the patient and the dentist, and often causes the patient to develop a subsequent loss of trust and confidence in the dentist.

The final diagnosis is typically reached at a relatively late stage of these conditions, often after complications have already occurred. Complications may include a catastrophic fracture of the tooth or cusp or significant periradicular bone loss associated with a vertical root fracture as seen by radiographic examination (see also [Chapter 2](#)). For this reason, this chapter emphasizes the *early diagnosis* of these conditions. The collection of signs and symptoms associated with each of the three categories of cracks and fractures may be confusing unless the clinician considers these indicators as representing a continuous process examined at a given time point.

FRACTURE MECHANICS

Fracture mechanics is the field of biomechanics concerned with the propagation of *cracks* in a given material until the formation of the final catastrophic *fracture*.^{7,52} Many terms have been loosely used in the dental literature to describe the clinical entities that are the subject of this chapter.^{5,9,18,35} Here, the term

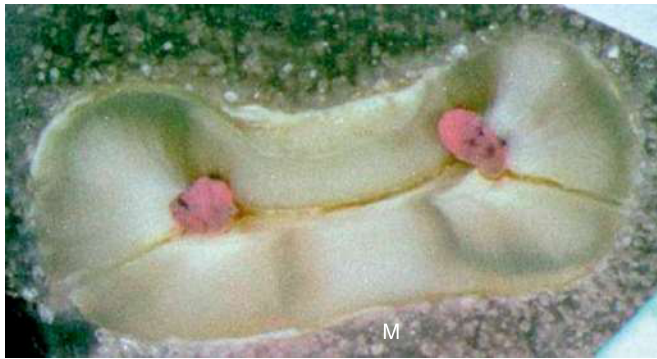

FIG. 21-1 Complete vertical root fracture. A cross section of a mesial root of a mandibular molar with a complete vertical root fracture. The fracture is in the buccolingual plane and extends from the buccal convexity of the root to its lingual convexity.

crack will be used in the biomechanical sense: a *partial discontinuity* in a material that may propagate and eventually lead to a complete discontinuity, also known as a *fracture*.^{7,52} In this context, a cusp may be described as *cracked*, a condition leading with time to a *fractured cusp*. A *cracked tooth* may be so called until a final fracture occurs that separates the tooth into two parts, a condition termed a *split tooth*. Similarly, microcracks may appear in the radicular dentin of an endodontically treated tooth, and these cracks may propagate with time until a *vertical root fracture* occurs, at which point the full thickness of the dentinal wall shows discontinuity: a through-and-through fracture. Such a fracture may be *incomplete*, involving one wall of the root, or *complete*, separating the root into two parts⁸⁰ (Fig. 21-1).

CRACKED AND FRACTURED CUSPS

Definition

A *cracked cusp* is characterized by a crack between a cusp and the rest of the tooth structure, to the extent of allowing microscopic flexure upon mastication. This crack typically does not involve the pulp. With time, the crack may propagate, eventually resulting in a *fractured cusp*.⁵

Diagnosis

Patient History

In the case of a cracked cusp, the patient history is the most important tool for making a diagnosis. The patient will likely complain about pain when chewing, to the extent of not being able to chew on the side on which the crack occurred.^{18,35,69} The patient will also often state that the condition existed for a relatively long time and that his or her dentist could not find the source or glean any information from radiography.^{3,16,47} When asked whether the pain is sharp or dull, patients will typically report a sharp pain that makes them immediately stop chewing on that side. The diagnostic challenge is attempting to determine which cusp of which tooth is involved, as patients often have difficulties determining the specific location of the discomfort.^{16,18,35,69} Because the pain has a pulpal origin, the patient's proprioception may not be accurate, as no periodontal ligament is involved. Occasionally, the pain upon chewing may radiate to nondental locations on the same side of the face,^{16,47,71} as also described in Chapters 4 and 17.

Clinical Manifestation

Early Manifestation

The typical characteristic of cracked cusps is a sharp pain upon chewing, although the affected tooth may not be sensitive, or only selectively sensitive, to percussion.⁷⁰ The tooth is vital, and its response to a cold stimulus may be normal; but with time, this response may resemble a pulpitis, which may be either localized or referred to other odontogenic or nonodontogenic locations.^{16,47,71}

Cracked cusps are often associated with extensive occlusal restorations,^{3,29,71,78} which may undermine and weaken the cusp and predispose it to initiating or perpetuating a crack from occlusal forces. Nevertheless, cracked cusps may also be present in intact teeth or teeth with smaller restorations.^{13,70}

Late Manifestation

With time, a crack may propagate and result in a fractured cusp. If the fracture line occurs coronally to the periodontal ligament the fractured portion will simply separate from the tooth. However, if the fracture line extends subgingivally, gingival fibers or the periodontal ligament will often retain the fractured cusp. Initially, it may be possible to move the cusp by wedging a sharp explorer into the fracture line, making the fractured cusp more visible. Often, from continued mastication, a localized and more acute type of pain may emerge secondary to the movement of the fractured fragment in the coronal PDL. The pulpal pain that is typical at an earlier stage (the cracked cusp) will typically resolve once a complete fracture occurs.

Diagnosis

A cracked cusp may be diagnosed, to a large extent, on the basis of the patient history. To locate the affected tooth, a *biting test* should be performed using a Tooth Slooth (Professional Results, Laguna Niguel, CA) or a similar device^{9,12} (Fig. 21-2). The device is composed of a small pyramid with a flattened top that is placed on a selective cusp, while the wider part of the device is applied to several opposing teeth while the patient occludes (see Fig. 21-2). The application of these forces to a cracked cusp will generate a sharp pain, which may occur upon pressure or released.^{3,34,43} The patient will typically state that this sensation has reproduced the sensation of the chief complaint.

Magnification with such devices as loupes or an operating microscope can be helpful when looking for a crack. If the tooth does not have an extensive intracoronal restoration, *transillumination* may also assist in revealing the crack line. If the tooth has a large restoration, the removal of the restoration may facilitate the effective use of this diagnostic tool (Fig. 21-3). The light source should be intense but with small dimensions (Fig. 21-4); it is applied to the tooth at the area of the suspected cusp fracture, with the lights of the dental unit, microscope, and room extinguished. The light penetrates the tooth structure up to the crack, leaving the part beyond the crack relatively dark (see Fig. 21-3). However, when large intracoronal restorations are present, this type of examination may be less effective.

Once the crack propagates, resulting in a fractured cusp, the diagnosis becomes more straightforward: the fractured cusp will either be missing or moved by wedging an explorer into the fracture line (Fig. 21-5).

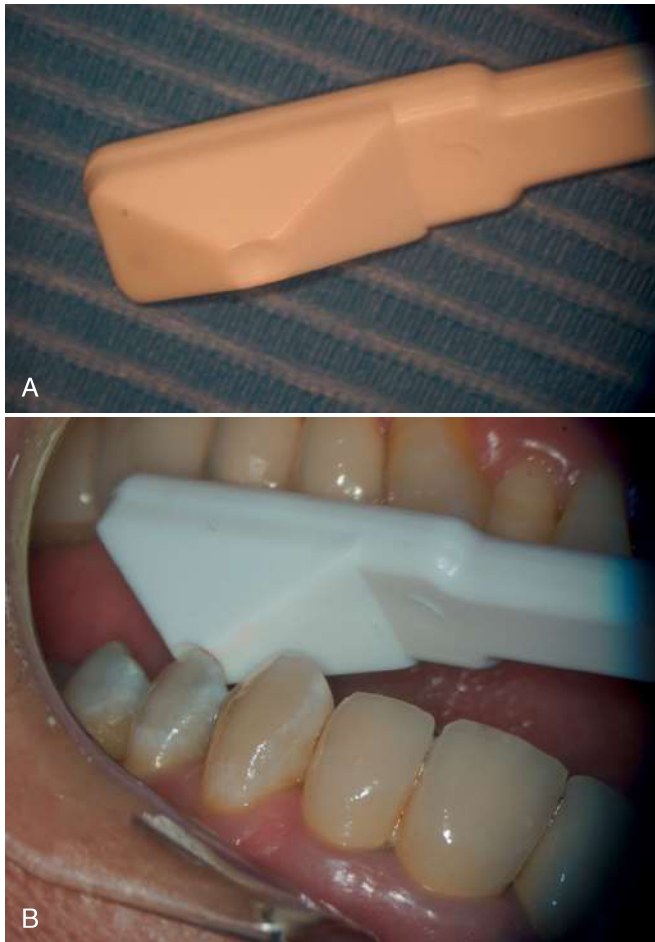


FIG. 21-2 A Tooth Slooth device. A, The Tooth Slooth device. B, Application for a bite test: the tip of the pyramid is touching the tested cusp while the wide base is supported by multiple contacts.

Etiology

Extensive intracoronal restorations may be a predisposing factor for cracked and fractured cusps.^{3,29,71,78} Otherwise, the etiology of these conditions is similar to that of cracked teeth (see *Cracked and Split Teeth, Etiology*).

Treatment Planning

Cracked Cusp

Treatment should consist of protecting the affected cusp from occlusal forces, both to prevent pain while chewing and to prevent the propagation of the crack into a full fracture. A full-coverage crown or onlay is recommended,^{5,16,39} although bonded composite restorations have also been proposed.^{28,64} One should keep in mind that if the cracked cusp is not protected, the tooth may eventually fracture. If the fracture plane extends apically into the root, the tooth will be potentially nonrestorable.^{5,9,12} Endodontic treatment is indicated only if signs and symptoms of pulpal pathosis are observed. In addition, if the removal of the cracked cusp and associated restoration will result in little or no remaining coronal tooth structure, then elective root canal treatment may be necessary for prosthetic reasons. When such a treatment plan is selected, one should also perform an occlusal reduction of the tooth as soon as possible to remove the tooth from active occlusion. The

patient should be instructed to be careful when chewing until the tooth is restored with a crown.

Fractured Cusp

The treatment of a fractured cusp depends on the amount of tooth structure remaining. If the missing part is limited in size, then the conservative restoration of a bonded composite resin may be indicated to cover the exposed dentin. In contrast, when a larger fragment has fractured and is either removed or missing, a full crown or an onlay may be necessary.

In certain cases, when cracked cusps are found in intact teeth or in teeth with no extensive restoration, it is difficult to predict the direction in which the crack is propagating. Therefore, in these cases, when considering endodontic and restorative treatment, the patient should be advised as to the potential decrease in prognosis, as described later.

CRACKED AND SPLIT TEETH

Definition

A *cracked tooth* exhibits a crack that incompletely separates the tooth crown into two parts. If the crack is allowed to propagate longitudinally, the tooth will eventually fracture into two fragments, resulting in a *split tooth*.

Diagnosis

Patient History

In cases of a cracked tooth, the patient history may be similar to that for a cracked cusp—namely, sharp pain upon mastication and prolonged failure of the dentist to diagnose the source of the pain.^{16,19} Similar to a cracked cusp, the diagnosis of a cracked tooth is often made on the basis of the patient history alone. Often it is challenging for the practitioner to determine the location of the offending tooth. With time, the patient may report that he or she *used to have* a sharp pain and now experiences great sensitivity to cold stimuli; the patient may even report, at a later stage, that the pain has subsided. These observations are consistent with pulpitis or pulp necrosis, which may develop in the affected tooth with time.¹³

Clinical Manifestation

Early Manifestation

Cracked teeth may have extensive restorations with a weakened crown, or they may have minimal or no restorations. A cracked tooth begins with a crack in the clinical crown, which may gradually propagate in an apical direction.^{3,5,28,47} Such cracks typically run in the mesiodistal direction, often splitting the crown into the buccal and lingual fragments. In the early stages, the tooth may be vital and painful to mastication. The pain may be sharp, to the extent that the patient is unable to chew on the affected side. This condition may persist for an extended period of time.^{16,18,19} The pain may be localized or referred to any tooth, maxillary or mandibular, on the same side of the mouth.^{16,47,71} No radiographic manifestations are present at these early stages, as the crack is microscopic and runs perpendicular to the x-ray beam. The affected tooth may or may not be sensitive to percussion at this point, and pulp testing may be normal or indicative of increased sensitivity to cold stimuli.

Late Manifestation

The late manifestation of a cracked tooth may include *pulp involvement* and eventually the *loss of pulp vitality*¹³ or apical

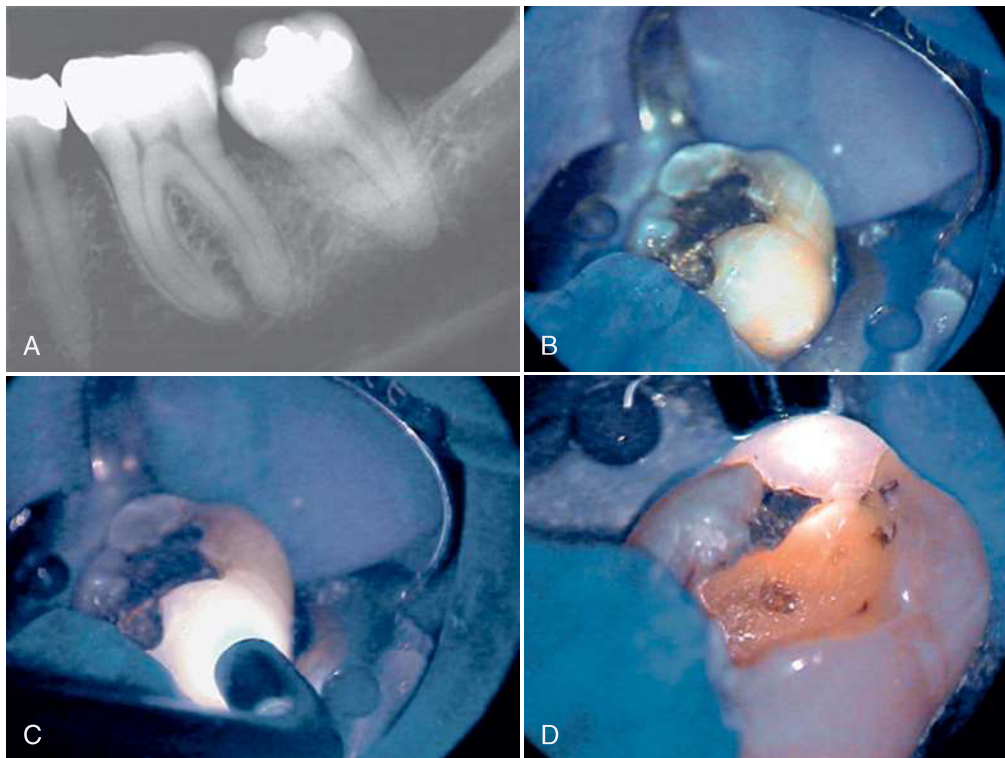


FIG. 21-3 Transillumination for the detection of a cracked cusp/tooth. An intense but small light source is applied to the suspect tooth, preferably in relative darkness. The light is transmitted through the tooth structure but is reflected from the crack plane, leaving the area behind the crack in darkness.

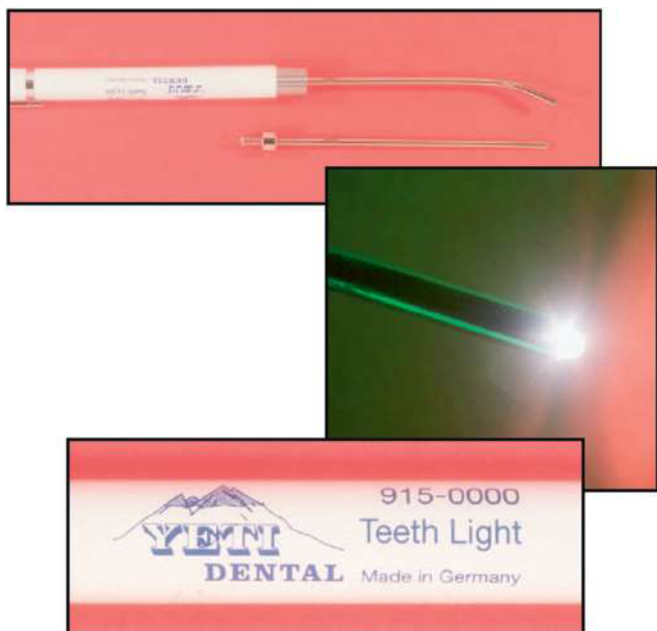

FIG. 21-4 Light source for transillumination. The light source should be intense yet with small dimensions, such as the simple battery-operated device manufactured by Yeti Dental (Engen, Germany).

propagation of the fracture, resulting in a *split tooth*. In one investigation,¹³ 27 nonvital molar and premolar teeth that had minimal or no restorations or caries were studied. Upon extraction, these teeth were examined under a surgical operating microscope or using micro-computed tomography (CT)

analysis. In each of these teeth, a longitudinal crack was observed, which extended to the pulp. Although the study had a limited sample size, the clinician should understand the potentially poor prognosis from cracked teeth, especially when the crack is suspected to be the cause of pulp necrosis.¹³

Pulp involvement occurs more often in cases of centrally located cracks (i.e., extending from marginal ridge to marginal ridge through the central fossa) than in cracks with a more buccal or lingual location.^{18,90} These centrally located cracks commonly affect the roof of the pulp chamber at a later stage. Consequently, pulp vitality may be compromised and later lost due to bacterial penetration through the crack. The pulp may first become reversibly or irreversibly inflamed and later necrotic and infected. The sharp pain upon mastication that is typical of the early stage may disappear once pulp vitality is lost. Moreover, apical periodontitis in an apparently intact molar may be a late manifestation of an untreated case of a cracked tooth.¹³ When pulp necrosis occurs, the radiographic manifestation may be an apical periodontitis, which is undistinguishable from that of apical periodontitis (Fig. 21-6).

A crack may propagate with time through the pulp chamber and into the root, resulting in a complete fracture that separates the tooth into two parts, a condition termed *split tooth*. When this split occurs, the resulting parts of the tooth may be movable by wedging a sharp explorer into the fissure.^{5,9} Later, more evident movement of the parts may be observed. The radiographic presentation at such a late stage may eventually develop into a diffuse radiolucency surrounding the root. At this late stage, narrow isolated deep periodontal pockets may be present.⁹ However, such pockets are typically located

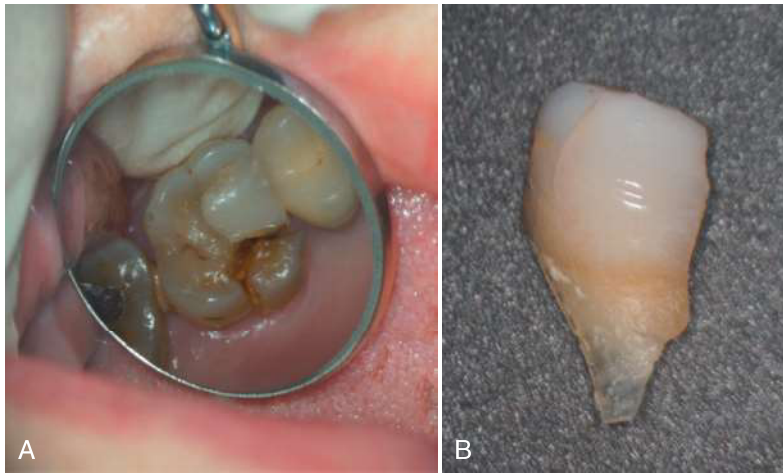


FIG. 21-5 A fractured cusp. A, The mesiopalatal cusp of a maxillary first right molar was fractured. The fractured cusp was movable and was retained by the periodontal ligament. B, The cusp was removed, and the tooth was considered restorable. It was treated with root canal treatment and a crown.

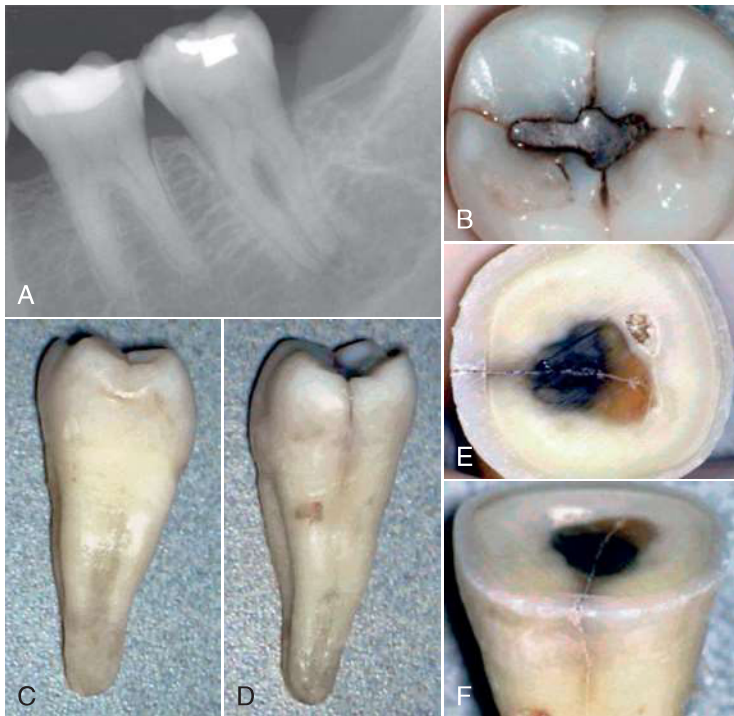


FIG. 21-6 A case of fracture-induced necrosis. A tooth with minimal or no restoration or caries is unlikely to become nonvital. A, This radiograph of a mandibular second molar shows a restoration that is distant from the pulp chamber, yet the tooth is nonvital and symptomatic. B, On occlusal examination, a slight crack is observed on the distal marginal ridge. C, After extraction, the mesial aspect of the crown and root shows no indication of a fracture. D, However, the distal aspect of the crown and coronal root shows the fracture. E, F, When the crown is sectioned, the crack can be observed to extend well into the pulp chamber.

mesially or distally and, if adjacent teeth are present, they will be difficult, if not impossible, to detect.

Cracked and split teeth may present with a large and variable collection of signs and symptoms that are potentially confusing.^{16,18,78} Only by being aware of the *process* leading from early to late manifestations can clinicians interpret these signs and symptoms and identify the specific point they are encountering on the potential timeline of this process.

A definitive combination of factors, signs, and symptoms that, when collectively observed, allows the clinician to conclude the existence of a specific disease state is termed a *syndrome*. However, given the multitude of signs and symptoms that cracked roots can present with, it is often difficult to achieve an objective definitive diagnosis. For this reason, the terminology of *cracked tooth syndrome*¹⁸ should be avoided.

Diagnosis

As in the case of a cracked cusp, early detection is imperative in order to resolve the patient's symptoms as well as increasing the prognosis. However, the use of the Tooth Slooth device (see Fig. 21-2) may or may not provide as clear a result for a symmetrically cracked tooth, as each of the parts of the tooth may be rather stable. Asking the patient to chew on a cotton roll⁹ or on the tip of a cotton-tip applicator placed at a particular site may reproduce the pain. Nevertheless this method may not indicate whether the source is a maxillary or mandibular tooth and need further measures to pinpoint the involved tooth. *Magnification* using either loupes or an operating microscope can be helpful for detecting a fracture line. In addition, dyes, such as methylene blue or tincture of iodine, which are applied either to the outer surface of the crown or to the dentin after the removal of an existing intracoronal restoration, can be

helpful for visualizing the crack (see Fig. 21-3). Transillumination can also be applied to the suspected tooth and, if the tooth has no restorations, this method may yield an impressively straightforward diagnosis (see Fig. 21-3). Anesthetizing the suspected tooth, followed by asking the patient to chew again on the cotton roll, may further confirm the diagnosis and finally differentiate the origin as a mandibular or maxillary tooth. At a later stage, when splitting of the tooth has occurred, wedging of a sharp explorer into the fracture line will provide a clear diagnosis of a split tooth.

Generally speaking, the diagnosis of a crack in a tooth can be difficult. When there are signs and symptoms of a pulpitis or necrosis, it is incumbent upon the clinician to determine the source that initiated the signs and symptoms. In the case of a problematic tooth with no apparent reason for the pulpitis or necrosis, like a tooth with minimal or no caries, restoration, or trauma, a crack or fracture must be considered.¹³ In some cases, an objective diagnosis may not be possible; however, with the possibility of a crack or fracture, the patient should be advised of a potential decrease in the endodontic or restorative prognosis.^{5,12}

Etiology

Masticatory forces are the cause of cracked teeth.^{22,34,45,47,70,71,90} Thus, the dietary habit of chewing on coarse food has been proposed as a contributing factor.^{22,90} Bruxism or clenching of the teeth as well as occlusal prematurities are also frequent causes of cracked teeth.^{18,22,34,45,47,70,71,90} For this reason, certain teeth may be more prone to developing cracks, such as mandibular second molars and maxillary premolars.¹⁸ Masticatory habits such as chewing ice may also predispose teeth to cracks. The term *fatigue root fracture*, proposed by Yeh,⁹⁰ encompasses all of these causes.

In certain cases, traumatic injuries, such as a severe upward blow to the mandible (e.g., during a car or sports accident) can also cause a tooth crack or fracture. Another potential cause is the unexpected chewing of a hard object (e.g., a cherry pit or an unpopped corn kernel in popcorn). The occlusal forces applied by the first molars are as high as 90 kg,⁴⁵ which, when fully applied unexpectedly, may damage the tooth structure. However, in most cases, a tooth crack can be attributed to no specific cause other than normal or excessive masticatory forces.^{22,34,45,47,70,71,90}

Treatment Planning

Cracked Tooth

When a cracked tooth is either suspected or determined, the patient should be informed that the prognosis is reduced and sometimes questionable.^{5,9,12} Protecting a tooth from the propagation of a crack and improving comfort while chewing are the principal goals in the treatment of cracked teeth. Both goals can often be immediately achieved by placing an orthodontic band around the tooth^{3,9,16} or by placing a provisional crown. These procedures allow the clinician to evaluate the extent of pulp involvement by checking whether the pulpal symptoms subside in response to the intervention.^{3,9,16}

Protecting the tooth from further splitting forces by the placement of a permanent crown is essential in these cases.^{3,5,9,16,39} Unfortunately, a crown alone is often not sufficient to resolve symptoms, and endodontic treatment may be considered prior to the placement of the permanent crown, depending on the pulpal symptoms.⁹

A root canal treatment followed by a permanent crown has the benefit of immediately eliminating the long-lasting, painful symptoms as well as early protection from occlusal forces that may cause propagation of a cracked tooth to become a split tooth. Nevertheless, when 127 cracked teeth with reversible pulpitis were treated with a crown alone, 20% of these teeth converted to irreversible pulpitis within 6 months and required root canal treatment.⁵¹ In contrast, none of the other teeth needed a root canal over a 6-year evaluation period.⁵¹ However, it should also be understood that varying percentages of crowned teeth, cracked or noncracked, may also require endodontic treatment, merely from the trauma of the crown preparation. By comparison, it has been shown that when suspected cracked teeth were restored with resin bonded restorations, only 7% required subsequent endodontic treatment or extraction.⁶⁴

After removal of an intracoronal restoration or when penetrating the dentin to prepare for endodontic access, one may observe discoloration along the crack in the dentin. Once the access cavity has been completed, the floor and the distal and mesial walls of the pulp chamber should be carefully inspected to check for the presence and extent of any cracks. Upon evaluating 245 restored teeth, cracks were observed preoperatively in 23.3% of the teeth; however, when the restorations were removed, 60% of these teeth were found to have cracks.¹ Methylene blue dye may be helpful in this type of examination. If a crack is found that reaches from the mesial wall, through the floor of the pulp chamber and into the distal wall, then the prognosis for the tooth is poor, and extraction should be considered (see Fig. 21-6).^{5,9,12} If the crack does not reach the pulp chamber or is limited to the coronal parts of the mesial or distal wall, the subsequent protection of the tooth with a crown may save the tooth. Nevertheless, as mentioned previously, the patient should be advised that the treatment success may be compromised and that long-term follow-up will be required.^{5,9,12}

Given that such cracks occasionally occur in teeth with minimal or no restorations and that all of the pain may cease once the pulp is removed, it may be tempting to limit the final restoration to an intracoronal amalgam or composite restoration. This temptation should be resisted by all means, as the forces that caused the crack are still present, and the apical propagation of the crack and loss of the tooth is still likely.

Split Tooth

When the tooth is split either through its whole length or diagonally (Fig. 21-7), extraction is typically the only treatment option.^{5,9} However, if the fracture line is such that the split results in large and small segments, and if the removal of the small fragment preserves enough tooth structure that is restorable, then retention and restoration of the tooth may be considered.⁵

VERTICAL ROOT FRACTURE (VRF)

Definition

A *vertical root fracture* (VRF) is a longitudinally oriented complete or incomplete fracture initiated in the root at any level and is usually directed buccolingually⁵ (Figs. 21-1 and 21-8 through 21-11). By definition, these types of fractures do not arise from the propagation of a fracture that originated in the crown. This definition separates a VRF from a split tooth,

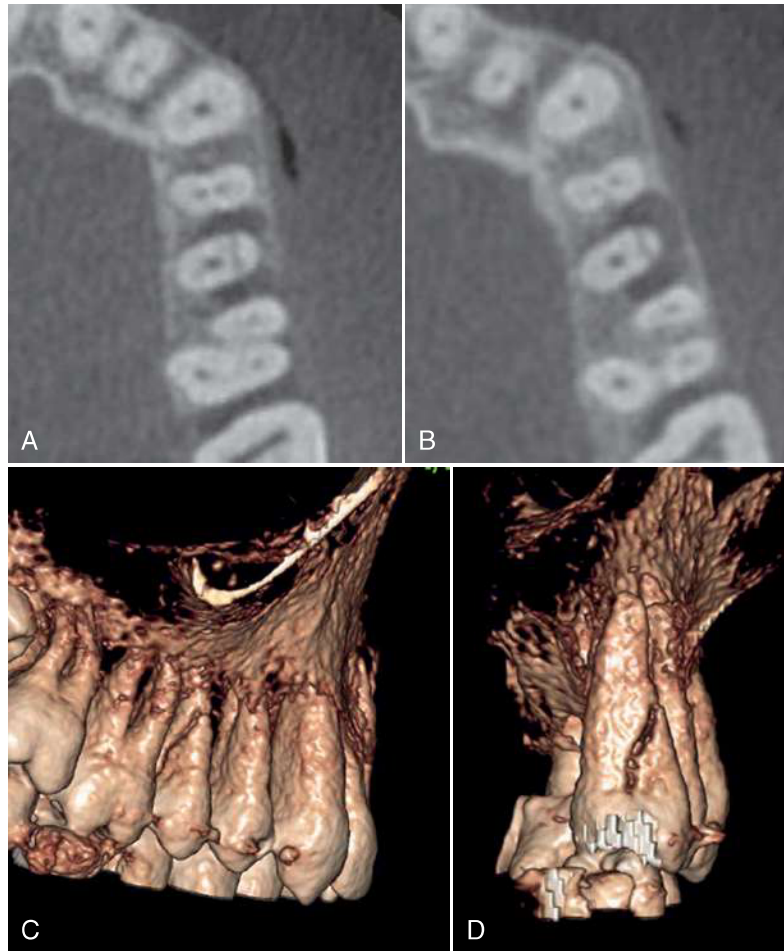


FIG. 21-7 Diagonally split tooth. A maxillary right second premolar presented with a mesiodistal coronal fracture. A, B, CBCT axial views revealing a mesiodistal fracture at two different levels, with associated mesial and distal bone loss. The more coronal view has mesial and buccal bone loss (A). A more apical view reveals mesial, distal, and buccal bone loss (B). C, D, the three-dimensional reconstruction clearly reveals the nature and direction of the fracture and defined the tooth as unrestorable. Both bone loss and the thick dimensions of the fracture line indicate a longstanding case in which bone resorption allowed opening of the fracture to dimensions that could be detected by CBCT. It is unlikely that such clear demonstration of the fracture line could appear at earlier stages of its formation. (Courtesy Dr. Anda Kfir, Tel Aviv, Israel.)

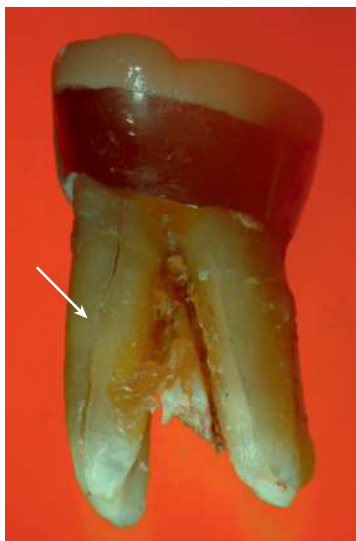


FIG. 21-8 Diagonal VRF in a molar. A lingual view of a right first mandibular molar revealing a diagonal VRF in the mesial root.

which begins with a crack of the crown that propagates apically into the root as a longitudinal fracture. Although both are catastrophic longitudinal fractures, a vertical root fracture should be clearly differentiated from a split tooth in that the causes, origins, and typical planes of fracture are substantially different.

Diagnosis

Patient History

In the case of a VRF, a patient may complain of pain or sensitivity related or adjacent to a given tooth. Sensitivity and discomfort while chewing are also common complaints.⁸⁰ Swelling may occasionally occur in the area. There is often a long history of failing to diagnose the cause of the pain and discomfort. A history of repeated clinical and radiographic examinations that revealed no cause for the pain is also common in VRF cases. After recent endodontic retreatment, if the symptoms remain and the dentist is unable to determine the cause of the symptoms, the patient may lose confidence in the dentist. Often retreatment or surgical retreatment may have

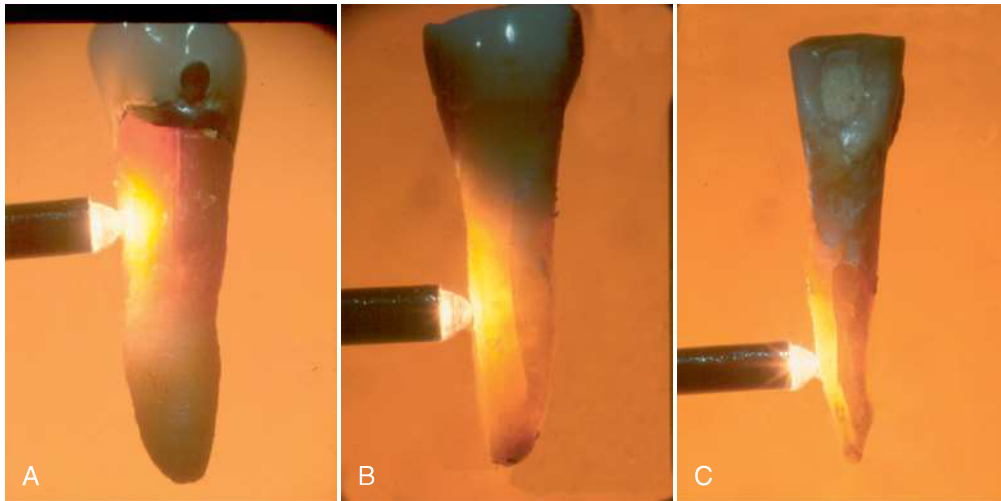


FIG. 21-9 Three types of VRFs. A, A coronally located VRF extending apically as far as one third of the root. B, A midroot VRF extending along the middle third of the root. C, An apically located VRF extending coronally as far as the apical two thirds of the root.

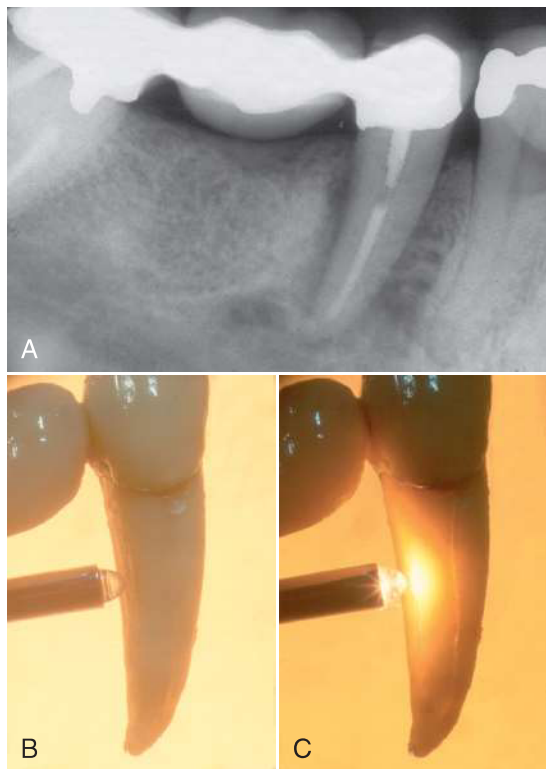


FIG. 21-10 Radiographic presentation of VRF-associated bone loss. A second right mandibular bicuspid was endodontically treated and restored using a short post. Two years later the patient started experiencing discomfort and sensitivity upon chewing. Initially no radiographic signs were present. This lasted for 9 months until a radiograph (A) revealed an extensive bone resorption and the tooth extracted. A, A large radiolucent lesion was present along the root on the distal side. B, The tooth was extracted, but the buccal VRF was not readily evident. C, Transillumination with an intense but small light source was used after extraction to clearly demonstrate the VRF. (Courtesy Dr. Ramy Levi, Israel.)

been attempted to reveal the accurate diagnosis.¹ Unfortunately, such ineffective treatment attempts may only worsen the dentist-patient relationship.

Clinical Manifestations

Susceptible Teeth and VRF Location

Vertical root fractures are commonly associated with endodontically treated teeth with or without a post.⁵ Nevertheless, VRFs can also occur in teeth with no previous root canal treatment.²² The most susceptible sites and tooth groups are the maxillary and mandibular premolars, the mesial roots of the mandibular molars, the mesiobuccal roots of the maxillary molars, and the mandibular incisors.⁸¹ However, VRFs may occasionally occur in other teeth and roots as well.

Vertical root fractures may progress in the buccolingual direction in these teeth and roots, which are typically narrow mesiodistally and wide buccolingually.⁴⁰ However, VRFs may also propagate diagonally, thus affecting the mesial or distal aspect of the root (see Fig. 21-8). VRFs may be initiated at any root level.⁵ They may be initiated at the apical part of the root and propagate coronally (see Fig. 21-9, C). Nevertheless, certain VRFs originate at the coronal, cervical part of the root and extend apically (see Fig. 21-9, A), and in other cases, a VRF may be initiated as a midroot fracture (see Figs. 21-9, B; 21-10, C; and 21-11, D).

It is commonly believed that VRFs begin as microcracks at the root canal surface of the radicular dentin and gradually propagate outward until the full thickness of the radicular dentin is fractured.^{5,10,21,56,87} Studies^{14,17,50,76,91} indicate that microcracks can also be initiated at the outer surface of the root and propagate inward. Therefore, the correlation between microcracks in the radicular dentin and the formation of VRFs should be further investigated.

Early Manifestation

In the early stages of a VRF, there may be pain or discomfort on the affected side of the tooth. In particular, the tooth may feel uncomfortable and sensitive upon chewing, although this pain is often of a dull nature, as opposed to the sharp pain typical of

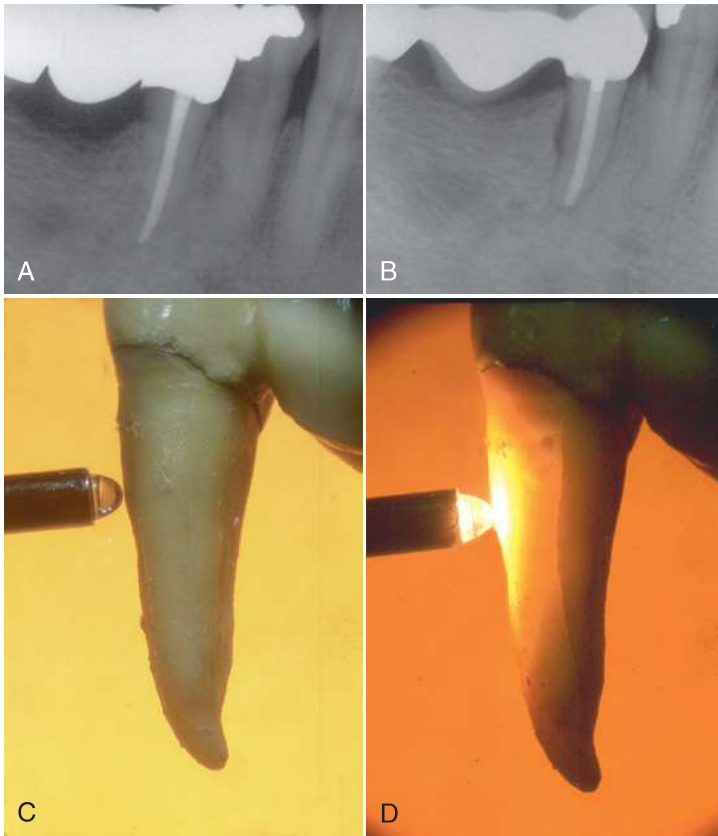


FIG. 21-11 Small isolated radiographic presentation of VRF-associated bone loss. A second right mandibular bicuspid was endodontically treated and restored with no dowel. A year later the patient started complaining about sensitivity on the lingual side. Three months later the radiograph (A) was taken and the tooth extracted. A small radiolucent lesion was present along the root on the distal side. The tooth was extracted, but the lingual VRF was not readily evident (B). Transillumination with an intense but small light source was used after extraction to clearly demonstrate the VRF (C, D). (Courtesy Dr. Ramy Levi, Israel.)

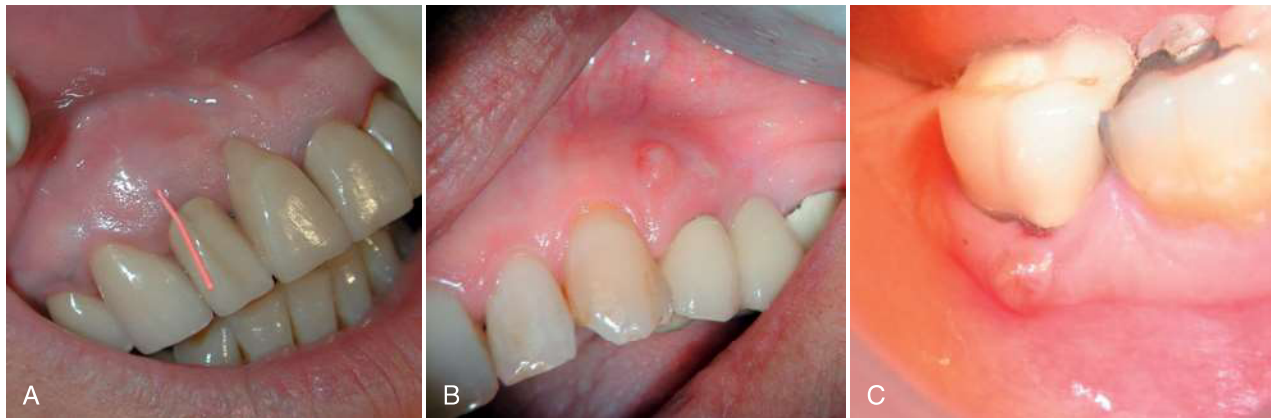


FIG. 21-12 Coronally located sinus tracts. A, A maxillary right lateral incisor with a sinus tract located at the attached gingiva, an uncommon location for sinus tract drainage from a chronic periapical abscess. Maxillary lateral incisors are *not* among the teeth with high prevalence of VRFs. B, A draining sinus tract at a coronal location originating from a buccal VRF in the first left maxillary premolar. C, A draining sinus tract at the gingival margin of a right first mandibular molar with a buccal VRF in the mesial root. (A and B, Courtesy Dr. Russ Paul, Zichron Yaakov, Israel.)

a cracked cusp or tooth with a vital pulp. As the fracture and subsequent infection progresses, swelling often occurs, and a sinus tract may be present at a location more coronal than a sinus tract associated with a case of chronic apical abscess^{79,81} (Fig. 21-12). These signs and symptoms are frequently similar to those encountered from nonhealing root canal treatment.^{57,86} In the early stages, radiographic findings are unlikely because (1) the root canal filling may obstruct the detection of the fracture (Fig. 21-13, A), and (2) the bone destruction (which still

has limited mesiodistal dimensions) may be obstructed by the superimposed root structure (Fig. 21-14).

A deep, narrow, and isolated periodontal pocket may be associated with the root, which often cannot be explained by, as it is inconsistent with, the surrounding periodontal examination.^{79,81,85} This specific type of periodontal defect occurs secondary to the bony dehiscence caused by the vertical root fracture. It is substantially different from the pockets caused by advanced periodontitis (discussed later).

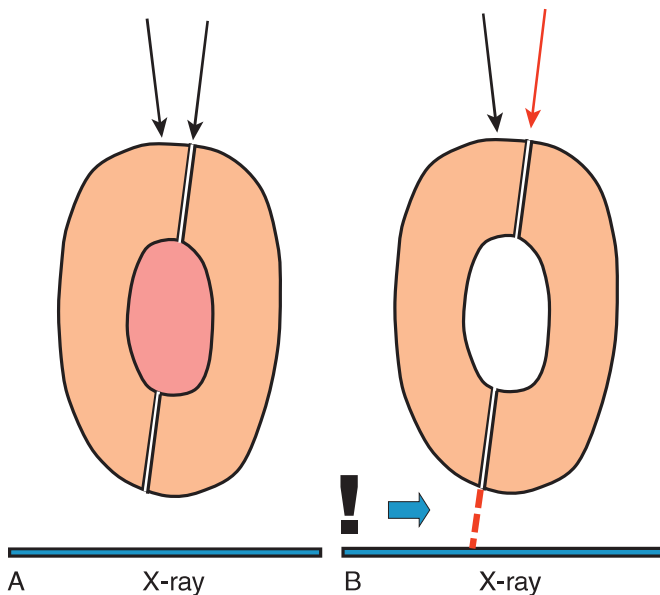


FIG. 21-13 Radiographic examination of filled versus empty canals. A, The buccolingual projection of a filled root will fail to detect a VRF at an early stage. B, The removal of the root filling and use of radiography at different mesiodistal angulations may reveal the VRF.

Late Manifestation

A longstanding vertical root fracture is easier to detect. The major destruction of the alveolar bone adjacent to the root has already occurred, allowing the VRF to be more likely revealed in a periapical radiograph (see Fig. 21-7). One of the most typical signs is the *J-shaped* or *halo radiolucency*, which is a combination of periapical and periradicular radiolucency (i.e., bone loss apically and along the side of the root, extending coronally)^{82,83} (Fig. 21-15). In addition, the pocket along the fracture, which was initially tight and narrow, may become wider and easier to detect. In longstanding cases in which the bone destruction is extensive, the segments of the root may also separate, resulting in a radiograph that clearly reveals an objective root fracture (Fig. 21-16).

Diagnosis

Importance of Early Diagnosis

Accurate and timely diagnosis is crucial in VRF cases, allowing the extraction of the tooth or root before extensive damage to the alveolar bone can occur. Early diagnosis is particularly important when implants are a potential part of the future restorative procedure; when an extraction is performed at an early stage, the uncomplicated placement of an implant is likely. When the tooth is extracted after extensive damage has already occurred (see Fig. 21-14), bone regeneration procedures may be required,⁴² adding cost and time to the restoration procedure.

The American Association of Endodontists stated in 2008⁵ that a sinus tract and a narrow, isolated periodontal probing defect associated with a tooth that has undergone a root canal treatment, with or without post placement, can be considered pathognomonic for the presence of a VRF.

However, the combination of the following two factors makes the early diagnosis difficult: (1) many of the clinical symptoms associated with VRFs mimic apical periodontitis or periodontal disease, and (2) the narrow and tight pocket associated with

early stages of VRF is difficult to detect using rigid probes (see the **VRF Pocket** section). Consequently, a delay in the accurate diagnosis or a misdiagnosis of a VRF may often occur.

Misdiagnosis of VRFs

Certain cases of longstanding VRFs are so discernible that no dentist can miss the diagnosis (see Fig. 21-16). Nevertheless, two retrospective case series, one by Fuss and colleagues³² and the other by Chan and associates,²² reported that general practitioners often misdiagnose VRFs. The teeth that were extracted in these studies had often been diagnosed as endodontic failures or refractive periodontal pockets, only to realize after extraction that in some of them the actual cause was a VRF.

VRF Pockets

The pockets that are typical of the early stages of VRFs differ substantially from the deep pockets associated with advanced periodontal disease. The deep pockets associated with periodontal disease develop as a result of the bacterial biofilm that initially accumulates at the cervical areas of the tooth and the destructive host response to these bacteria.³⁸ Therefore, deep periodontal pockets are typically wider coronally and relatively loose. This pocket structure allows the easy insertion of rigid periodontal probes (Fig. 21-17). These types of periodontal pockets typically present with the deeper part of a pocket at the mesial or distal aspects of the tooth. Periodontal disease often affects groups of teeth rather than an isolated location of a single tooth.

The pockets associated with VRFs develop due to bacterial penetration into the fracture, triggering a destructive host response that occurs in the periodontal ligament along the entire length of the fracture. These bacteria may leak from an infected root canal⁸⁷; however, when the VRF extends to the cervically exposed root, the microbes in the fracture may also originate from the oral cavity. In the early stages, the periodontal ligament is affected and destroyed along the longitudinal opening of the fracture, initially with a limited resorption to the adjacent bone. This permits the penetration of a periodontal probe. The pocket associated with a VRF is typically isolated and present only in a limited area adjacent to the affected tooth. This pocket is often located at the buccal or lingual convexity of the tooth. In the early stages, the pocket is deep but has a narrow coronal opening (see Fig. 21-17). The insertion of a probe first requires the detection of the coronal opening; often, light pressure is necessary for the insertion of the probe. Because the pocket is narrow, probe insertion may result in the blanching of the surrounding tissue (Fig. 21-18). This is specially the case when a plastic probe is used, as its coronal part is thicker than an equivalent metal probe (Figs. 21-18 and 21-19).

The pocket associated with the early stages of a VRF is quite different from a common periodontal pocket. This difference has been widely recognized, and terms such as *osseous defect*²⁸ and *probing defect*⁵ have been used to emphasize the point. Nevertheless, these pockets do possess enough unique features to justify them being specifically termed a **VRF pocket**.

Rigid metal periodontal probes may be ineffective in probing VRF pockets in the early stages of a VRF. Given that the pocket is deep, narrow, and tight, the bulge of the tooth's crown may prevent the insertion of a metal probe into the pocket (see Fig. 21-19). A flexible probe should be used instead, such as a probe available from Premier Dental Products (Plymouth

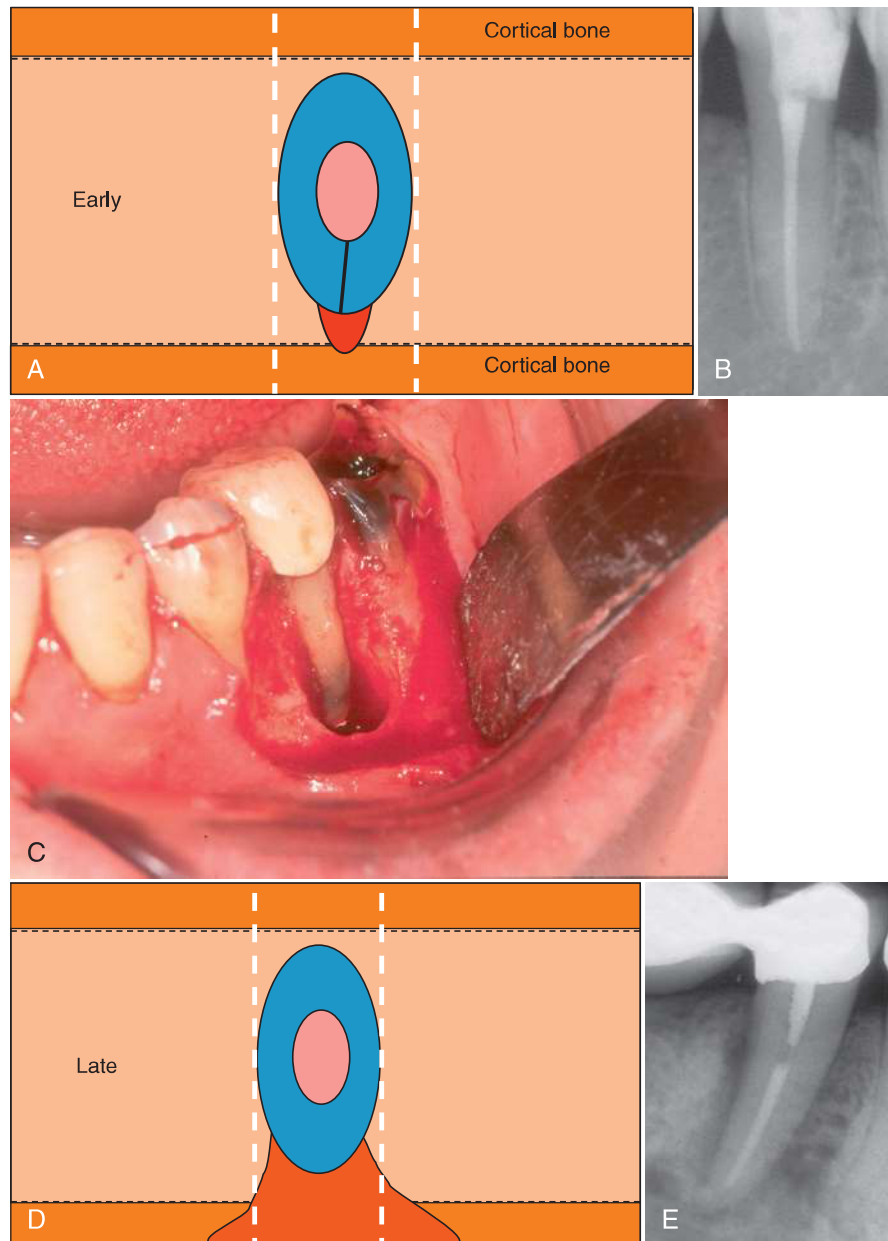


FIG. 21-14 Early versus late radiographic presentation of a VRF-associated bone defect. At an early stage, a bone defect (red) is not likely to be detected in a periapical radiograph, as the root will overlap with the defect (A, B). At later stages, when major damage has occurred to the cortical plate (C), the bone defect may be large enough to extend beyond the silhouette of the root (C, D) and appear as a radiolucent defect along the root (E). (Surgical image courtesy Dr. Devora Schwartz-Arad, Ramat-Hasharon, Israel.)

Meeting, Pennsylvania) (see Fig. 21-19) or a similar device. This type of flexible probe should be included on every endodontic examination tray and is an essential tool when checking for potential VRF pockets.

A typical VRF pocket was observed in 67% of the VRF cases reported by Tamse and colleagues.⁸¹ However, because the early detection of such pockets is technique sensitive and because traditional metal probes were used in the aforementioned study, the incidence of these pockets may in fact be higher than reported. When a typical VRF pocket is located on the convex flank of the root on the buccal or lingual side, it is likely that the root has a VRF. In contrast, when such a pocket

is located at the furcation of a molar, the pocket may indicate either a VRF or a sinus tract from an apical abscess that found a point of least resistance at the furcation area. In cases with a furcation pocket, when a VRF diagnosis cannot be conclusively determined, a positive healing response to the elimination of infection by initiating root canal retreatment may differentiate between these two types of pathoses.

Coronally Located Sinus Tract

Sinus tracts that originate from a chronic apical abscess are typically detected at the site of least bone resistance, against the apical part of the root or in the area of the junction of the

FIG. 21-15 Radiographic presentations of long-standing VRFs. A, J-shaped “halo” associated with a VRF in a second right mandibular premolar. B, Extensive bone damage associated with a complete VRF in a second right maxillary premolar. C, Limited bone damage associated with a midroot VRF in a second left maxillary premolar. D, Bone damage associated with a VRF in the mesial root of a first left mandibular molar. All such presentations are typical of longstanding VRFs.

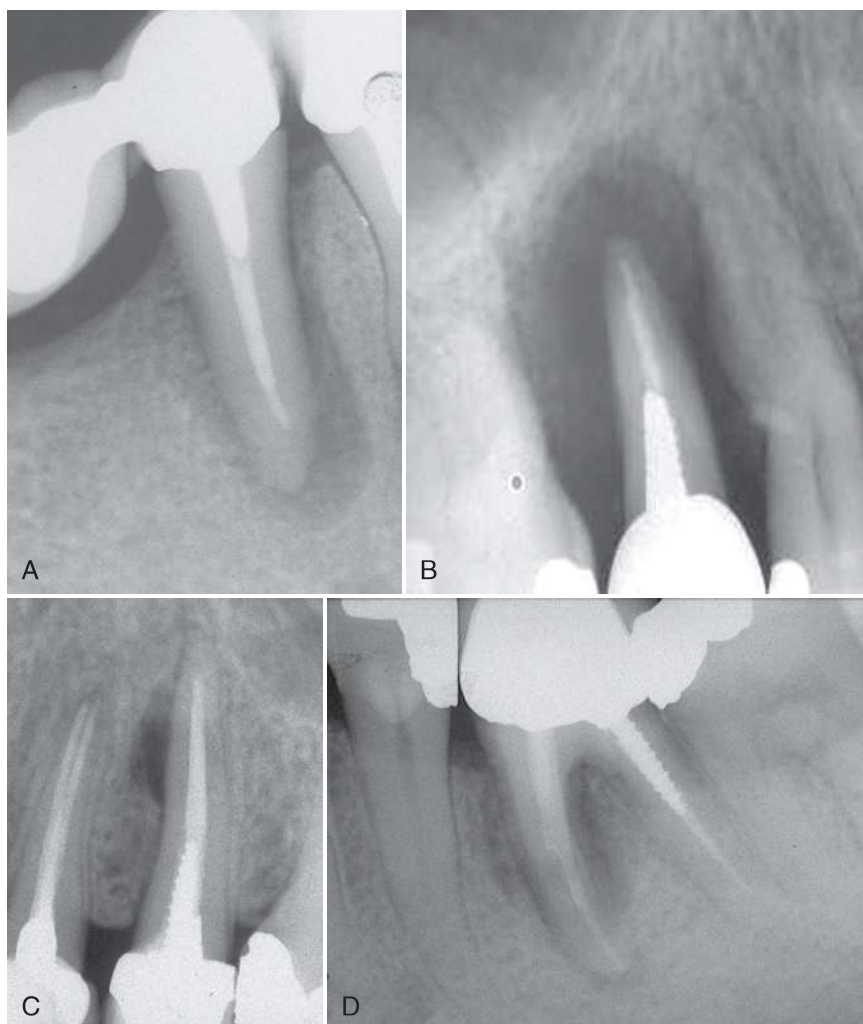
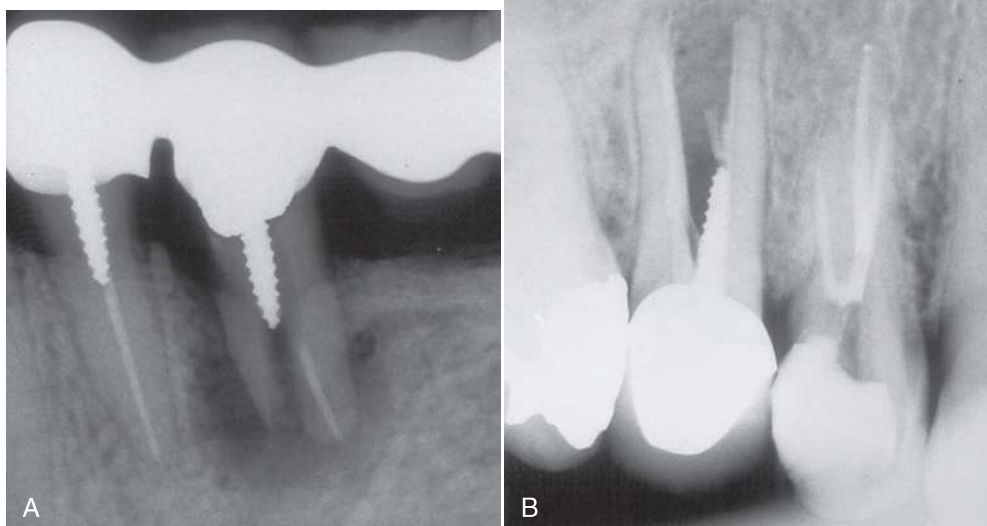


FIG. 21-16 Radiographs of longstanding vertical root fractures. No special diagnostic skills are needed to diagnose such cases.



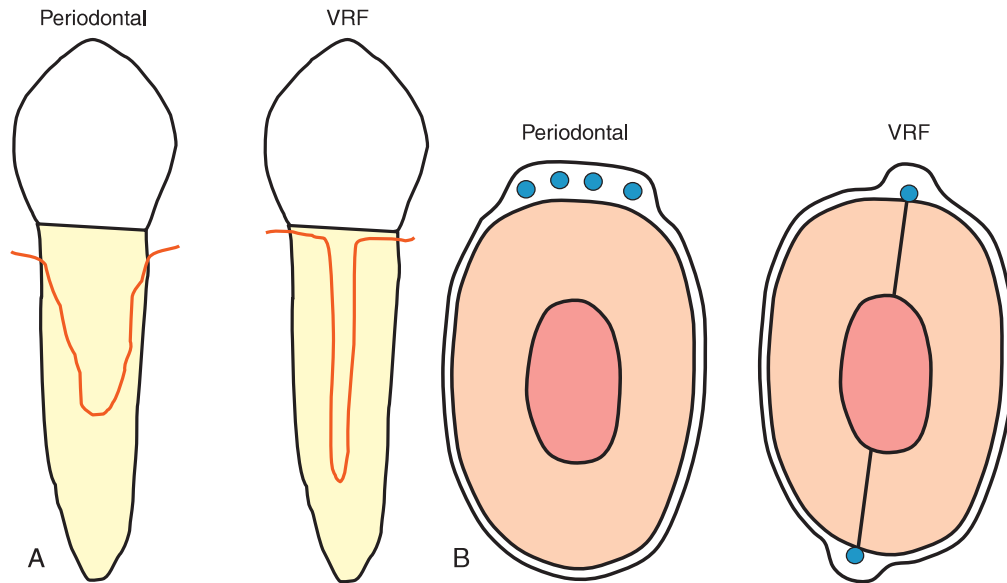


FIG. 21-17 VRF pocket. A, Periodontal pockets (left) are wide coronally, whereas VRF pockets (right) are narrow and deep. B, Periodontal pockets (left) are loose and allow probing at various sites, whereas VRF pockets (right) are narrow and tight. If not checked carefully at every millimeter of the sulcus, an early VRF pocket can easily be missed. Please note that periodontal pockets appear more commonly in the proximal sides of the root, whereas VRF pockets are more common on the buccal or lingual sides.

attached gingiva and the oral mucosa. Sinus tracts that are associated with a VRF pocket are often found in a more coronal position, as the source is not from a periapical lesion⁸⁰ (see Fig. 21-12).

In four clinical retrospective case series, coronally located sinus tracts were found in 13% to 35% of these cases.^{58,79,81,85} As in the case of a VRF pocket, if the sinus tract is located at the furcation of a molar, this observation does not necessarily indicate a VRF, as periapical abscesses from a failing root canal treatment can also drain in this coronal location.

Radiographic Features

A definitive VRF diagnosis can sometimes be made based on the radiographic appearance of a thin radiolucent line extending longitudinally down the root.⁷² Such lines, however, are difficult to detect and are commonly not seen in routine orthoradial, periapical radiographs because either the root canal filling has “masked” the fracture line or the angulation of the radiograph is not optimal for discerning the fracture (see Fig. 21-13) (Figs. 21-20 and 21-21). Rud and Omnell⁷² claimed that it was possible to observe fracture lines in 35.7% of cases, but many of these cases were not true VRF instances. In clinical practice, it is still rare to observe a VRF on a radiograph, especially when only a single periapical radiograph is taken. Such an observation requires the x-ray beam to align with the plane of the fracture as well as the fracture line not being superimposed over the radiopaque root filling (Fig. 21-20, A). Therefore, two or three periapical radiographs should be exposed from different horizontal angulations when a fracture is suspected⁸⁰ (see Figs. 21-21 and 21-22).

In most VRF cases, the clinician must make *interpretations* or *predictions* based on the various patterns of periradicular bone destruction, which, unfortunately, are also shared by other periodontal and endodontic-like lesions.^{58,75,88}

In the early stages of a VRF, no radiolucent bone lesions may be observed²⁰ (see Fig. 21-14), which may be the reason why VRFs often remain undetected, delaying diagnosis and treatment. Rud and Omnell⁷² correlated the direction of the fracture, the degree of bone destruction, and the radiographic appearance, and emphasized that the extent of bone destruction around a fractured root depends on the location of the root fracture and the time elapsed since the inception of the fracture. The significance of time was confirmed by Meister and colleagues,⁵⁸ who demonstrated that immediate radiographic detection is difficult due to the time required for bone resorption to occur or for the fractured segments to separate and be radiographically visible. In a study of the patterns of bone resorption in 110 VRF cases, Lustig and associates⁵⁷ found that in 72% of patients with either chronic signs and symptoms (i.e., pertaining to a sinus tract, osseous defect, or mobility) or acute exacerbations, there was greater bone loss recorded compared to patients for whom a VRF diagnosis was made at an early stage.⁵⁷

Despite the difficulty of diagnosing *early stage* VRFs in endodontically treated teeth, there are often several radiographic signs associated with *later stages* that are strong indicators of VRF.

The J-shaped or halo appearance, a combination of periapical and periradicular radiolucencies, was associated with a high probability of a VRF in a double-blind radiographic study involving 102 endodontically treated maxillary premolars⁸² (see Fig. 21-15). An angular resorption of the crestal bone along the root on one or both sides, without the involvement of the periapical area, mimicking a “periodontal radiolucency” (see Fig. 21-15), was found in 14% of the cases. Tamse and coworkers⁸³ also reported the radiographic appearance of “halo” (see Fig. 21-10) and “periodontal” radiolucencies (see Fig. 21-10) in vertically fractured mesial roots of

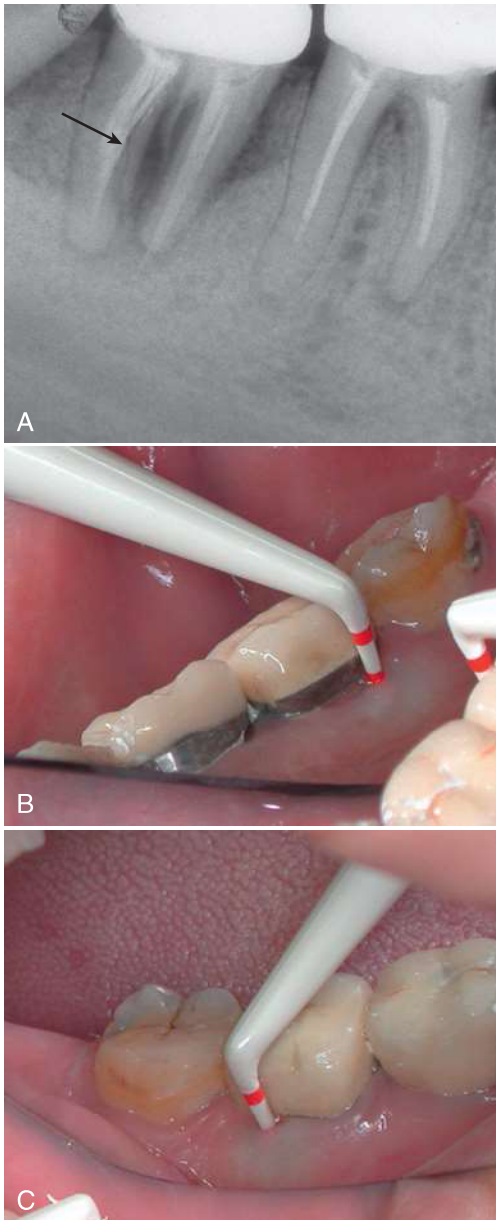


FIG. 21-18 Tight VRF pockets. A, The distal root of a second right mandibular molar with a VRF. VRF pockets were found on both the lingual (B) and the buccal (C) sides. VRF pockets are tight, so inserting a probe into these pockets causes pressure blanching of the surrounding tissues.

mandibular molars (37% and 29%, respectively). In that study, the use of these two variables, combined with bifurcation involvement (63%) and the presence of an amalgam dowel (67%), predicted fracture in 78% of the cases. Others have reported similar findings.^{24,62} Despite the different sample sizes, study designs, and objectives, the most common radiographic feature in these studies was a lateral radiolucency appearing longitudinally along the root and a halo appearance.

Radiolucency in the Bone Along Root

The type of periradicular radiolucency associated with a vertical root fracture is not and should not be interpreted as a thickening of the PDL. Instead, it represents a substantial

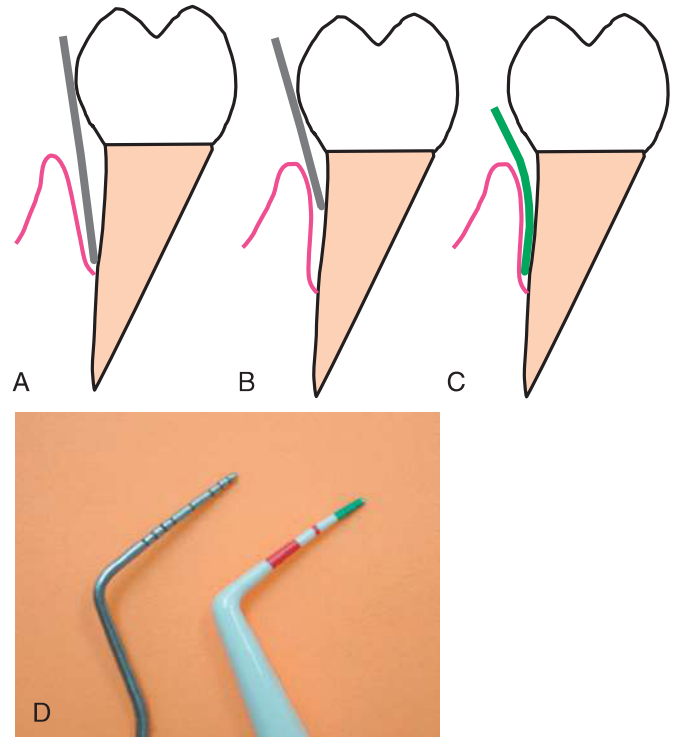


FIG. 21-19 Rigid versus flexible probes. A, In a loose periodontal pocket, a rigid metal probe can easily reach the depth of the pocket. B, In a tight, early-stage VRF pocket, a rigid probe may be of limited value, as the bulge of the crown often prevents the insertion of the probe into the tight, deep pocket. C, A flexible probe (D) is more likely to detect VRF pockets at an early stage.

destruction of the cortical plate of the alveolar bone⁵⁷ (see Fig. 21-14). In the case of a VRF in the buccolingual plane, often the bone resorption is limited at early stages, and any associated radiolucency may be obscured by the superimposition of the root (see Fig. 21-14). As the bone loss increases, the radiolucency becomes greater than the dimensions of the root, allowing it to be detected more clearly in the above-mentioned manner (see Fig. 21-14). As the VRF progresses to an intermediate stage, radiographs taken at different horizontal angulations may detect bone resorption (see Fig. 21-22), whereas a conventional orthoradial radiograph may not (see Figs. 21-14 and 21-22). This radiographic feature should be differentiated from a split tooth, in which the fracture plane is typically mesiodistal, with the bone resorption occurring in the earlier stages on the mesial or distal aspects of the root.

Radiograph of Empty Canal

As mentioned previously, the direct clinical detection of an early stage VRF from a periapical radiograph is unlikely, especially when there has been endodontic treatment. Because most VRFs are in the buccolingual plane, the radiopaque obturation often obstructs the view of the hairline radiolucency of the fracture (see Figs. 21-13 and 21-20). When a VRF is suspected, one may initiate root canal retreatment, removing the root obturation, and taking radiographs at two or three different horizontal angulations. The detection of a hairline radiolucency may provide a more definitive diagnosis of a VRF⁶⁰ (see Figs. 21-20 and 21-21).

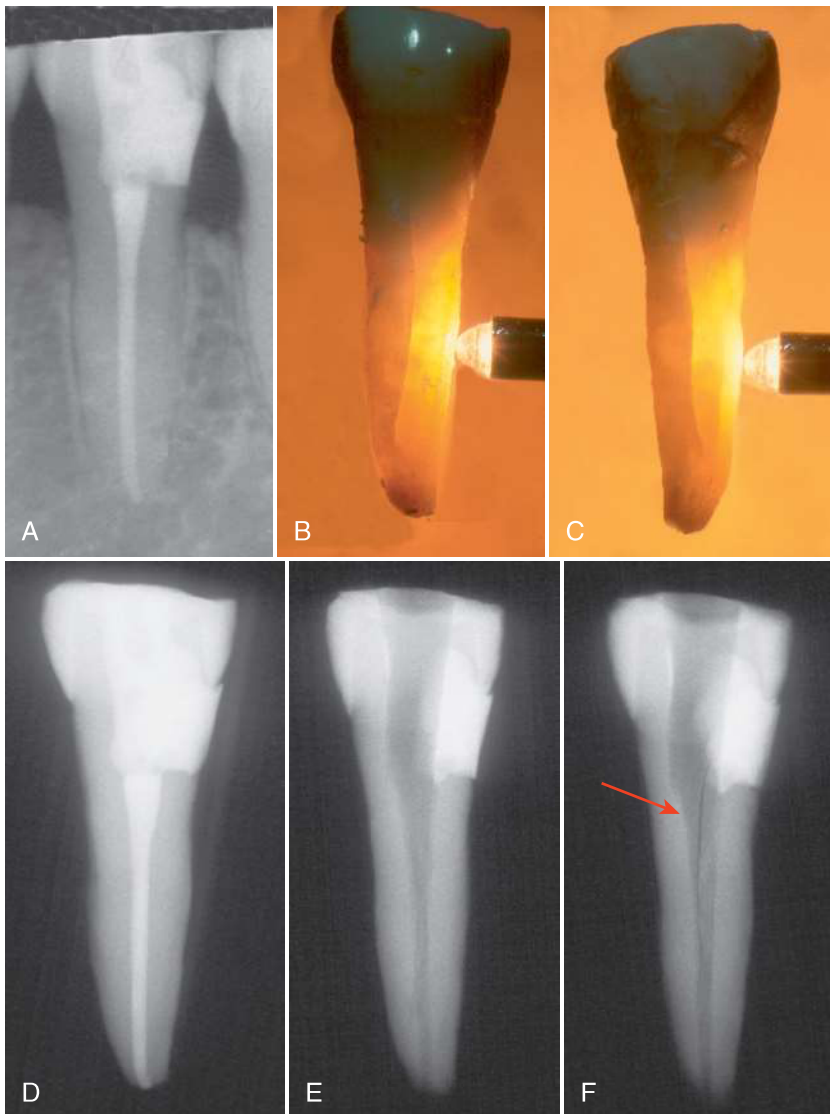


FIG. 21-20 Radiography of an ex vivo empty canal. The second left mandibular bicuspid underwent a root canal treatment, with no post required. Thirteen months later, the patient complained about pain and sensitivity to palpation on the lingual side. A radiograph provided no further information (A). An isolated, 7-mm pocket was detected on the lingual side, and the tooth was extracted. Midroot VRFs were visible on the buccal (B) and lingual sides (C). An ex vivo radiograph of the same tooth with no findings (D). The root filling was removed, and radiographs were taken from different mesiodistal angulations (E, F). One of the radiographs clearly revealed the VRF (F).

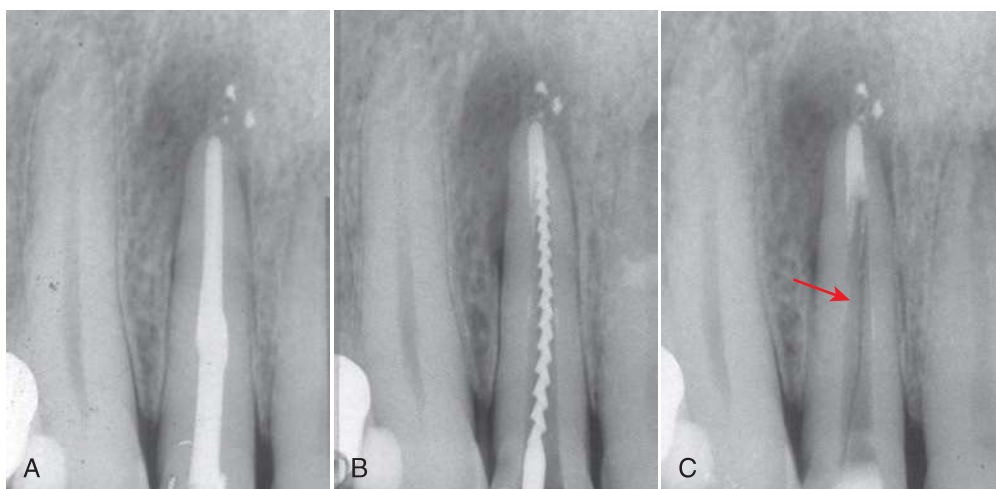


FIG. 21-21 Radiography of an empty canal: a clinical case. The right maxillary lateral incisor underwent a root canal treatment a few years ago. The patient complained about occasional pain on the palatal side. The tooth was sensitive to percussion and palpation on the palatal side. Radiography revealed a periapical radiolucency (A). An isolated, deep, and narrow pocket was found on the palatal side of the root. Both the patient and the referring dentist were reluctant to extract the tooth, assuming that the pocket could potentially be a sinus tract, and decided on retreatment. A radiograph taken with a file during the process (B) could have missed essential information that was obscured by the file, which was an evident VRF (C).

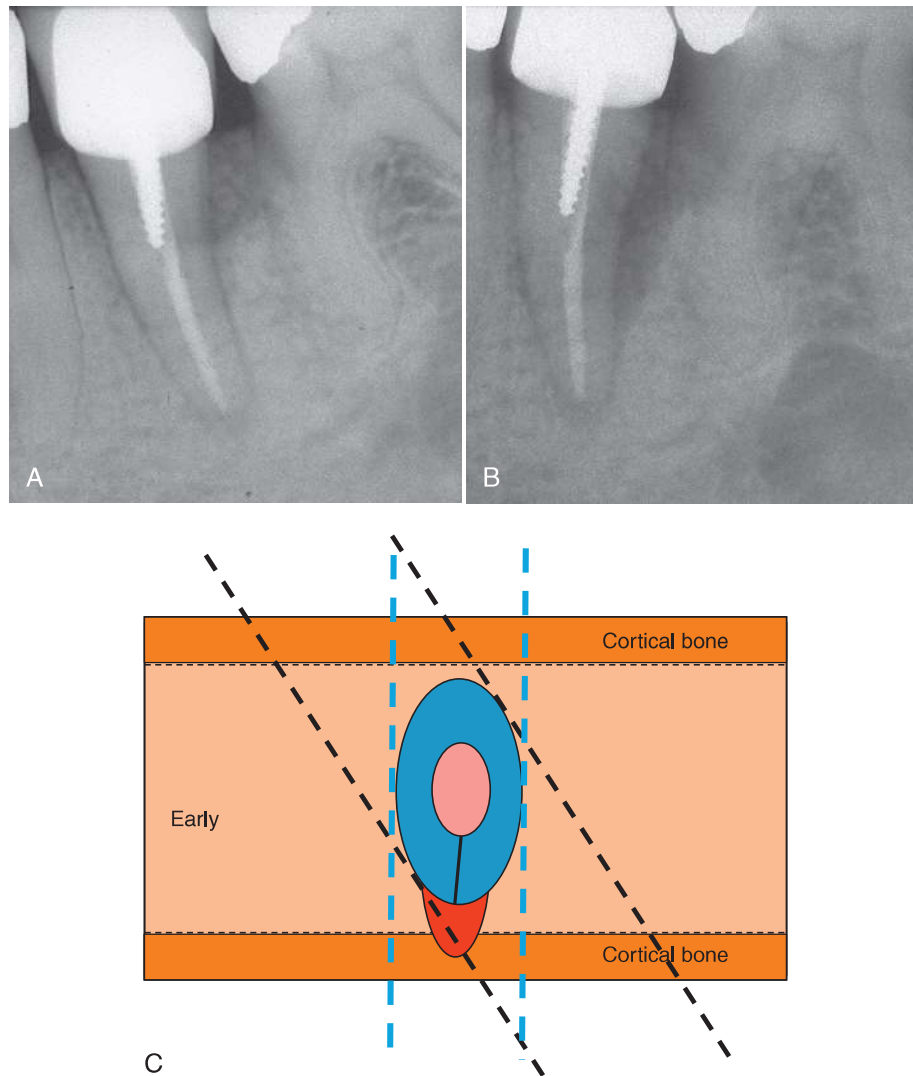


FIG. 21-22 Diagonal radiographs for detection of VRF. **A**, Orthoradial radiograph: very limited bone loss is seen. **B**, A different horizontal angulation reveals a radiolucent lesion along the root. **C**, Schematic presentation. Although a radiograph in an orthoradial direction (*blue lines*) cannot pick up the radiolucency along the root, diagonal angulation (*black lines*) may do so, as in **B**.

Cone-Beam Computed Tomography in VRF Diagnosis

Modern cone-beam computed tomography (CBCT) has a much smaller radiation dose compared to traditional medical spiral CT imaging, thus rendering CBCT a reasonable diagnostic tool for the use in selected endodontic cases.^{6,31,31a,65}

One of the unique features of CBCT is its ability to study the suspected tooth and associated bone in an axial plane. Axial views may provide detailed information regarding the cross-sectional appearance of the tooth and its surrounding bone (Fig. 21-23). With the CBCT devices currently available, the width of an unseparated fracture may be too small and undetectable (see Fig. 21-23) (SEDENTEXCT guidelines³¹). Traditional planar, periapical radiographs are also of limited value for the early detection of VRFs. More specifically, bone damage or separation of the fragments is only radiographically evident at a relatively late stage. Several studies suggested that the detection of early-stage VRFs by a CBCT scan set to an axial view may be possible.^{41,42,59} Yet such detection may greatly depend on the resolution of the machine (i.e., the voxel size). At a voxel size

of 0.3 mm, the detection of early, unseparated VRFs is not reliable; however, when smaller voxel sizes were used in these in vitro studies, the reliability greatly increased.^{41,42,59} Although the detection level of a fracture is thought to be twice the voxel size of CBCT imaging, there is presently no literature available to support this theory. Therefore, given that the smallest voxel size currently available for a CBCT device is about 0.075 mm, CBCT imaging would not be able to visualize a root fracture unless the fracture width was greater than 0.15 mm. It should also be noted that the intracanal presence of gutta-percha or a metal post often causes artifacts that make it extremely difficult to differentiate a VRF from such artificial lines.⁵⁹

Although early VRFs may still be below the detection level of many CBCT machines, the early destruction of the bone along the suspected fracture may be visible in the cancellous bone (i.e., with an axial view) at relatively early stages, whereas this early bone destruction would not be detectable in traditional planar, periapical radiographs; such bone resorption may help to establish a VRF diagnosis (see Fig. 21-23).

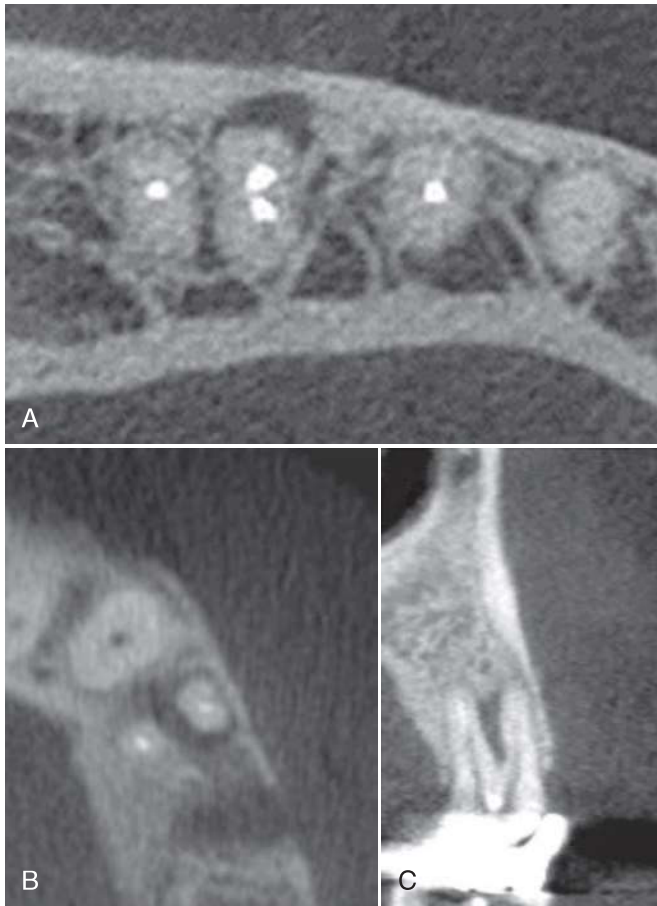


FIG. 21-23 “Invisible” bone destruction associated with early VRFs. **A**, Buccal VRF was present in the mesial root of a first left mandibular molar. At this early stage a typical VRF pocket was evident, yet no associated bone destruction was observed in a periapical radiograph. The VRF-associated bone destruction was evident in an axial plane of a CBCT. **B**, A VRF was present in the palatal side of the buccal root of the first maxillary premolar. A draining sinus tract was present with no radiographic signs to explain it. **C**, CBCT revealed a radiolucent lesion on the palatal side of the buccal root, which was verified, after extraction, as caused by VRF. Please note that in neither of these cases could the actual VRF fracture line be seen in the CBCT scan. (*B*, Courtesy Dr. Anda Kfir, Tel Aviv.)

With likely increased resolution in the near future, CBCT may become an important diagnostic tool for the detection of VRFs. For the present, neither the most updated Joint Position Statement of the American Association of Endodontists and American Academy of Oral and Maxillofacial Radiology (2010), nor the European Society of Endodontology position statement on the use of CBCT in endodontics (2014) recommend the use of CBCT for diagnosis of VRF.^{6,31a}

Improvements of CBCT imaging—such as achieving a better signal-to-noise ratio, obtaining a smaller voxel size, and by applying advanced algorithms to segment fracture lines—may promise the potential to enhance the ability to detect early-stage VRFs in the future.

Exploratory Surgery

When clinical and radiographic evaluations are equivocal in detecting a suspected vertical root fracture, exploratory surgery may be indicated. When a full-thickness flap is raised and the

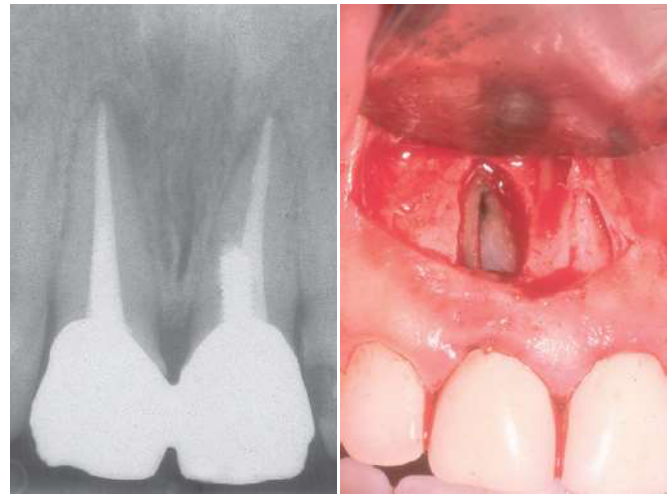


FIG. 21-24 An apical VRF with no pockets. The right maxillary central incisor was symptomatic despite an apparently adequate obturation. A radiolucent area was present around the apex, but no pockets were detected. Apical surgery was attempted, only to reveal a VRF at the apical part of the root that did not (yet) extend into the gingival margin and thus did not present with a typical VRF pocket. A semilunar flap design was used in this case, which was intended for apicoectomy. If surgical exploration for suspected VRF was initially intended, a conventional full flap would have been used. (Courtesy Dr. Ram Zeev, Rehovot, Israel.)

granulation tissue is removed, a VRF may often be directly visualized⁸⁰ (see *Figs. 21-14* and *21-24*). The bone resorption pattern associated with a VRF is mostly seen as a bony dehiscence, with the greater bone destruction being present on the buccal cortical plate located over the offending root. In a small percentage of the cases, fenestration can also be seen.⁵⁷ Furthermore, it has been shown that the longer a VRF-related infection persists, the greater the resulting periradicular bone destruction.⁵⁷

Etiology

Vertical root fractures may arise from a series of factors, some of which are natural whereas others are iatrogenic, arising from dental procedures such as endodontic treatment and the restorative procedures that follow it. The most common dental procedure contributing to vertical root fractures is endodontic treatment.¹¹

Most vertical root fractures occur in endodontically treated teeth.^{11,24} VRFs usually do not occur during the actual obturation of the root canal, but rather they occur long after the procedure has been completed.⁸¹

The etiology of VRFs is multifactorial.^{33,79} It is likely that in the presence of one or an accumulation of more predisposing factors, the repeated functional or parafunctional occlusal loads may eventually lead, over months or even years, to the development of a VRF. Predisposing factors may include natural ones, such as the anatomy of the root, or iatrogenic ones, such as the excessive forces during root canal instrumentation, excessive tooth structure removal, or excessive obturation pressure.

Natural Predisposing Factors

Shape of Root Cross Section

One of the common anatomic features shared by teeth that typically develop VRFs is an oval cross section of the root, with

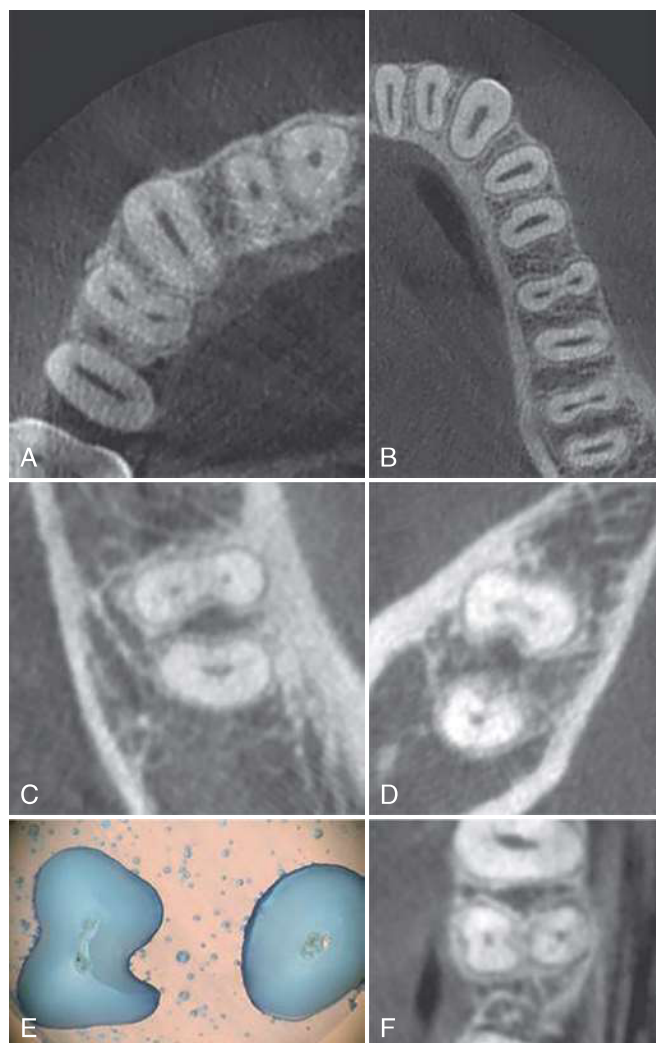


FIG. 21-25 Anatomic predisposing factors. **A**, An axial view of CBCT scan of a maxilla, revealing oval canals in the maxillary canine and second premolar. **B**, An axial view of a mandible, revealing oval canals in incisors, canine, premolars, and distal roots of the mandibular molars. Oval anatomy combined with endodontic treatment has been associated with a higher incidence of VRFs. **C**, **D**, Concavities on the distal aspect of the mesial roots of mandibular molar may establish a “danger zone” in which excessive instrumentation, combined with straightening of the canal, may result in a thinner dentin wall that may allow strain concentration. **E**, **F**, Concavities in the palatal side of the buccal root of maxillary first premolar (**E**, sections; **F**, axial view from a CBCT). These depressions may also represent a potential danger zone. Neither the concavity in **C** and **D** nor the concavity in **E** and **F** would be evident in a planar periapical radiograph. It should be noted that CBCT scans should not be used for routine screening but should be limited to the indications delineated in the joint statement of the American Association of Endodontists (AAE) and the American Academy of Oral and Maxillofacial Radiology (AAOMR).^{5,6}

a buccolingual diameter being larger than the mesiodistal diameter.^{36,40} These teeth include the maxillary and mandibular premolars, the mesial roots of the mandibular molars, and the mandibular incisors (Fig. 21-25, **A** and **B**). Such anatomy is easily observed in the axial plane of a CBCT scan (see Fig. 21-25, **A** and **B**). The fracture in these teeth typically starts in the buccolingual plane, specifically at the highest convexity of the oval root^{21,80} (see Fig 21-25, **A** and **B**). This conclusion,

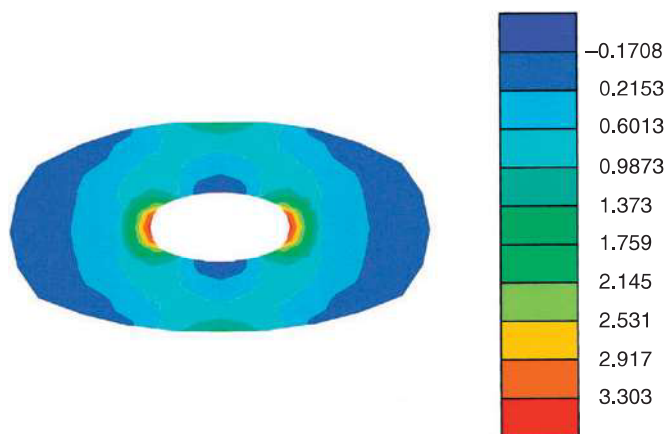


FIG. 21-26 Finite element analysis of the strain distribution in an oval root. Note the strain concentration on the inner side of the highest convexity of the remaining dentin wall. Red and orange represent areas of higher strains than blue areas. (From Lertchirakarn V, Palamara J, Messer HH: Patterns of vertical fractures: factors affecting stress distribution in the root canal, *J Endod* 29:523, 2003.)

derived from large case series, is also supported by finite element analysis.⁶⁴ Such analysis clearly demonstrated strain concentration on the inner side of the remaining dentin wall at the highest convexity point (i.e., the buccal and lingual sides of the oval roots)^{54,55} (Fig. 21-26).

Occlusal Factors

Excessive occlusal loads or concentration of such loads may be another natural predisposing factor. Load concentrations, such as those caused by occlusal prematurities in maxillary premolars, and excessive occlusal forces, specifically in the case of mandibular second molars, are examples.¹⁸ In combination with other natural and iatrogenic predisposing factors, excessive occlusal loads may, over time, lead to VRFs.

Preexisting Microcracks

Preexisting microcracks may be present in the radicular dentin, likely resulting from repeated forces of mastication or occlusal parafunction.^{15,63} Such fractures were also recently reported by Barreto and colleagues,¹⁰ who have found these microcracks in 40% of intact maxillary incisors and canines.

Iatrogenic Predisposing Factors

Root Canal Treatment

VRFs mostly appear in endodontically treated teeth^{5,80}; therefore, endodontic treatment per se may be considered an iatrogenic predisposing factor. Teeth were once thought to be more susceptible to fracturing after endodontic treatment because of a decrease in hydration.⁴³ However, later studies found no difference in the properties of dentin, as a material, after endodontic procedures.^{46,75}

Although the physical characteristics of the dentin, as a material, may not be compromised by endodontic treatment, the radicular dentin, as a structure, may be compromised by the accumulative or combined effect of several natural or iatrogenic factors associated with the endodontic treatment and the restoration of endodontically treated teeth. This may be the reason for the often-reported association of VRF with endodontically treated teeth.

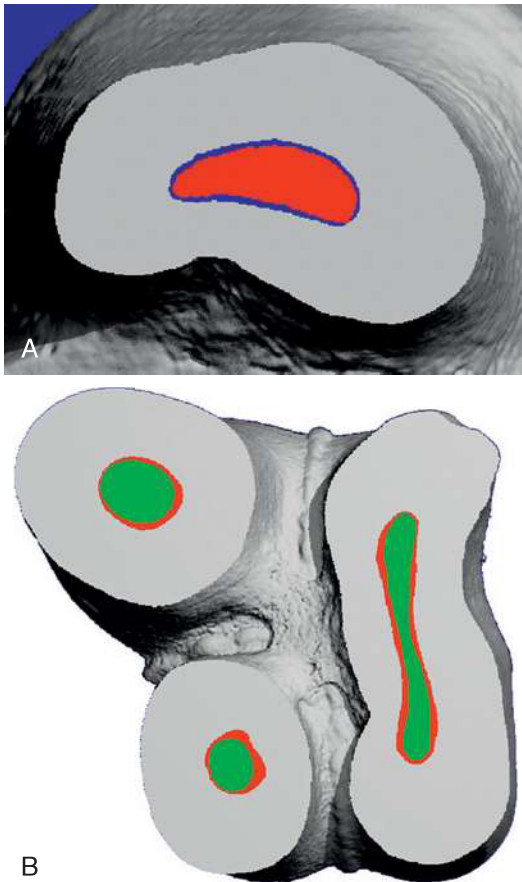


FIG. 21-27 Minimally invasive endodontic preparation. In this preparation, a uniform layer of dentin was removed from all around the root canal wall using a self-adjusting file, as opposed to shaping the canal into a circular cross section using rotary endodontic files. (A, From Metzger Z, Teperovich E, Zary R, et al: The self-adjusting file (SAF). Part 1: respecting the root canal anatomy—a new concept of endodontic files and its implementation, *J Endod* 36:679, 2010. B, From Solomonov M: Eight months of clinical experience with the self-adjusting file system, *J Endod* 37:881, 2011. Image from ongoing study by Solomonov and Paque F.)

It is incumbent for the clinician to recognize this effect and take efforts to minimize any steps that may contribute to the development of a root fracture during endodontic treatment.

Excessive Root Canal Preparation

Excessive root canal preparation may be a predisposing factor for VRF development.⁸⁹ In one study, cracks detected by transillumination were more frequent when the same teeth were subjected to a gradually increasing endodontic canal preparation.⁸⁹ To reduce the risk of VRFs, less invasive methods may be considered, such as minimally invasive endodontic instrumentation^{60,66} (Fig. 21-27; see also Chapter 6).

Microcracks Caused by Rotary Instrumentation

Shemesh and colleagues⁷⁶ and others^{2,10,14,17,44,77,91} observed that root canal preparation using nickel-titanium rotary and reciprocating files often results in microcracks in the remaining radicular dentin (Fig. 21-28). This finding, which was originally noted for single-root teeth, has been further supported by Yoldas and coworkers,⁹¹ who studied microcrack formation from rotary files in the mesial roots of mandibular molars. Each

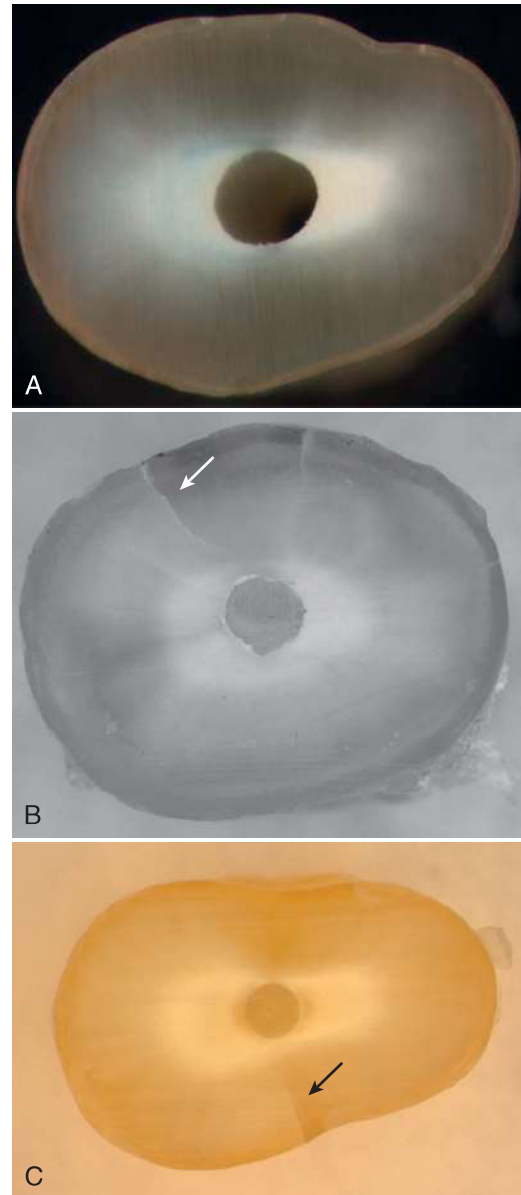


FIG. 21-28 Microcracks generated in single-root teeth by rotary nickel-titanium files. A, Control: hand instrumentation, generating no microcracks. B, C, Rotary instrumentation: microcracks generated in the remaining radicular dentin (arrows). (Courtesy Dr. H. Shemesh, Amsterdam, Holland.)

of the rotary file systems examined in this study caused frequent microcracks in the dentin, whereas both hand instrumentation with files and the self-adjusting file (see Chapter 6) did not cause such cracks (Fig. 21-29).

A finite element analysis by Kim and colleagues⁵⁰ supports and may explain these findings. These researchers reported that rotary files induce strain on the dentin, as measured in the surface layers of the root dentin, which likely exceeds the elasticity of the dentin, causing subsequent microcracks, as also reported by Shemesh, Bier, Adorno, Yoldas, and Bürklein, along with their research associates as well as by others.^{2,10,14,17,44,76,77,91} Additional stress, by either root obturation with lateral compaction^{10,76} or by retreatment⁷⁷ that was applied to roots that were previously instrumented with rotary files, caused some of the microcracks to propagate and become

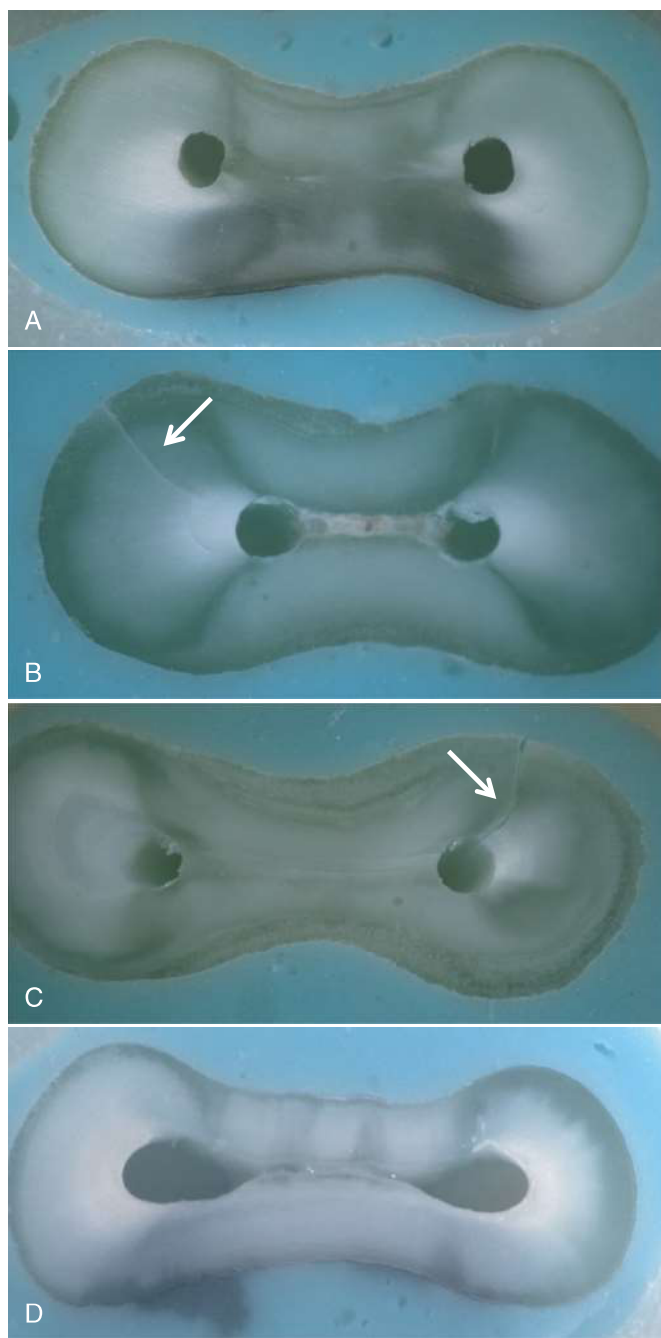


FIG. 21-29 Microcracks generated in mesial roots of mandibular molars by rotary nickel-titanium files. **A**, Control: hand instrumentation, generating no microcracks. Rotary instrumentation: microcracks generated in the remaining radicular dentin (arrows). **B**, A partial-thickness crack. **C**, A full-thickness fracture. **D**, Self-adjusting file instrumentation: no microcracks generated. (From Yoldas O, Yilmaz S, Atakan G, et al: Dentinal microcrack formation during root canal preparation by different NiTi rotary instruments and the self-adjusting file, *J Endod* 38:232, 2012.)

through-and-through fractures that were indistinguishable from VRFs.^{10,76,77}

The relationship of these various findings to the subsequent clinical creation of a VRF has yet to be confirmed. In any event, considering the basic principles of fracture mechanics, the creation of microcracks should at least be considered as a potential predisposing factor.

Uneven Thickness of Remaining Dentin

The instrumentation of root canals often results in uneven thickness of the remaining dentin, particularly when curved canals are straightened by instrumentation.⁶⁷ Uneven dentin thickness can also occur upon excessive instrumentation of the mesial roots of the mandibular molars or first maxillary premolars, which may exhibit a distal or mesial concavity, respectively, that is not detectable in a common planar, periapical radiograph (Fig. 21-25, C and D). These areas, which have been referred to as “danger zones,”³⁰ may be characterized by a decrease in the remaining dentin thickness in which the application of internal strain may potentially lead to a fracture. The anatomic groove that is often found on the palatal side of the buccal root of maxillary bifurcated premolars is another example of such a hidden danger zone⁴⁸ (Fig. 21-25, E and F).

Lingual access, which is commonly used in incisors, may also result in a thinner buccal wall in the apical area as compared with the lingual wall. This phenomenon may be especially pronounced when thick, and thus rigid, instruments are used excessively. When lateral compaction was applied ex vivo in a similar case, the strain concentration was recorded on the thinner buccal side of the apical part of the tooth (Figs. 21-30 and 21-31).

The use of flexible nickel-titanium files and minimally invasive instrumentation with instruments such as the self-adjusting file may reduce such risks (see also Fig. 21-27 and Chapter 6).

Methods of Obturation

Certain obturation techniques, such as lateral compaction, involve the application of internal pressure with a spreader, which may cause strains^{27,73} and subsequent propagation of microcracks into fractures across the full dentin thickness.^{10,76} Other obturation methods may create less pressure, such as thermoplasticized gutta-percha, and may reduce the risk of VRFs (see Chapter 7).

Type of Spreader Used

The use of a more rigid and thick stainless-steel hand spreader may lead to increased strain in the radicular dentin and can result in an increased incidence of root fracture.^{27,73} The introduction of more flexible finger spreaders, which have smaller diameter, may greatly reduce such risks.²⁷ Among the finger spreaders, devices composed of nickel-titanium allow insertion with less force than stainless-steel finger spreaders.⁷⁴ The nickel-titanium spreaders also allow a further reduction in the strain induced in the radicular dentin during obturation compared to traditional stainless-steel finger spreaders⁶⁸ (Fig. 21-32).

Post Design

Post selection, design, and seating have a significant effect on the strain distribution in the root. Excessively long or thick posts are considered a predisposing factor for VRFs.^{23,25,61} The use of posts carries an inherent risk of root fracture, particularly if excessive sound dentin is removed during preparation. Posts should only be used when essential for core retention and should be avoided whenever a sufficient coronal tooth structure is available for the secure retention of the crown.^{4,37}

Crown Design

When considering endodontically treated teeth, crowns with a ferrule margin (i.e., supported by a sound tooth structure all




FIG. 21-30 Strain measurement setup. Microstrain gauges (A, greatly magnified) are attached to the surface of the root in the area(s) of interest (B). The tooth is embedded in a cylinder composed of flexible dental-impression material (C), and the strain gauge or gauges are wired with a 3/4 Wheatstone bridge circuit (D) and connected to a data collection system (E). The continuous registration of the force applied to the spreader and the strain that develops in a given area of the root allows for the analysis presented in Figs. 21-31 and 21-32. (From Pilo R: Development of strains and mechanical failure in dental roots undergoing root canal obturation and prosthetic rehabilitation. PhD thesis, Tel Aviv University, 2007, supervised by Zvi Metzger and T. Brosh.)

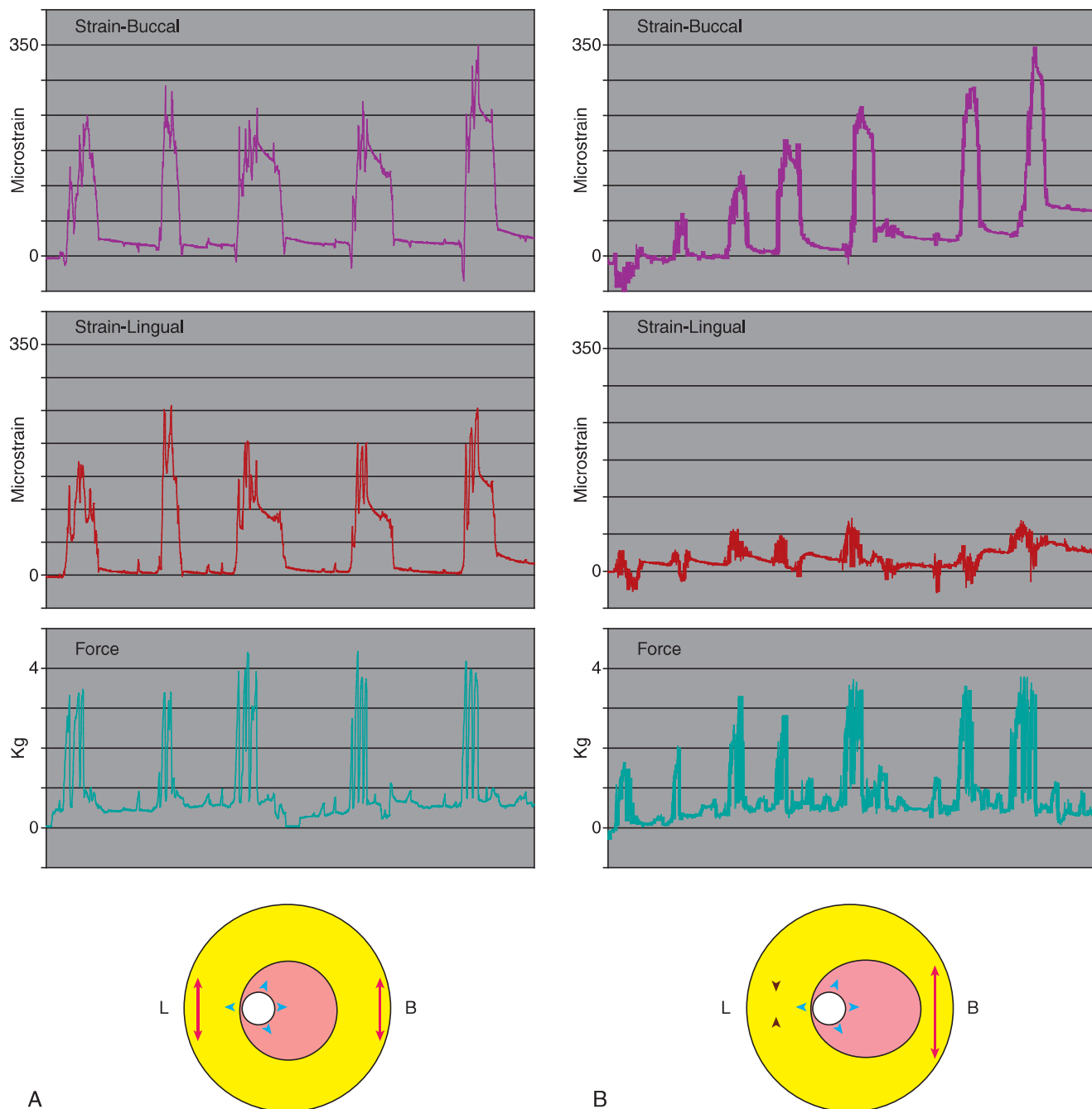


FIG. 21-31 Strain during lateral compaction: even versus uneven wall thickness. A pattern of the strain that develops in the buccal and lingual dentin of the apical area of a maxillary central incisor during lateral compaction. **A**, The thicknesses of the remaining buccal and lingual dentin were similar (even). Each manual insertion of the spreader was registered as a force peak. The tension strain was recorded for each insertion and was *similar* on the buccal and lingual sides. **B**, The thickness of the remaining dentin was lower on the buccal side than on the lingual side (uneven) due to the lingual access and rigidity of the instruments used. Each manual insertion of the spreader was registered as a force peak. The tension strain was recorded for each insertion on the buccal side, whereas compression was recorded on the lingual side. (From Pilo R: Development of strains and mechanical failure in dental roots undergoing root canal obturation and prosthetic rehabilitation, PhD thesis, Tel Aviv University, 2007, supervised by Zvi Metzger and T. Brosh.)

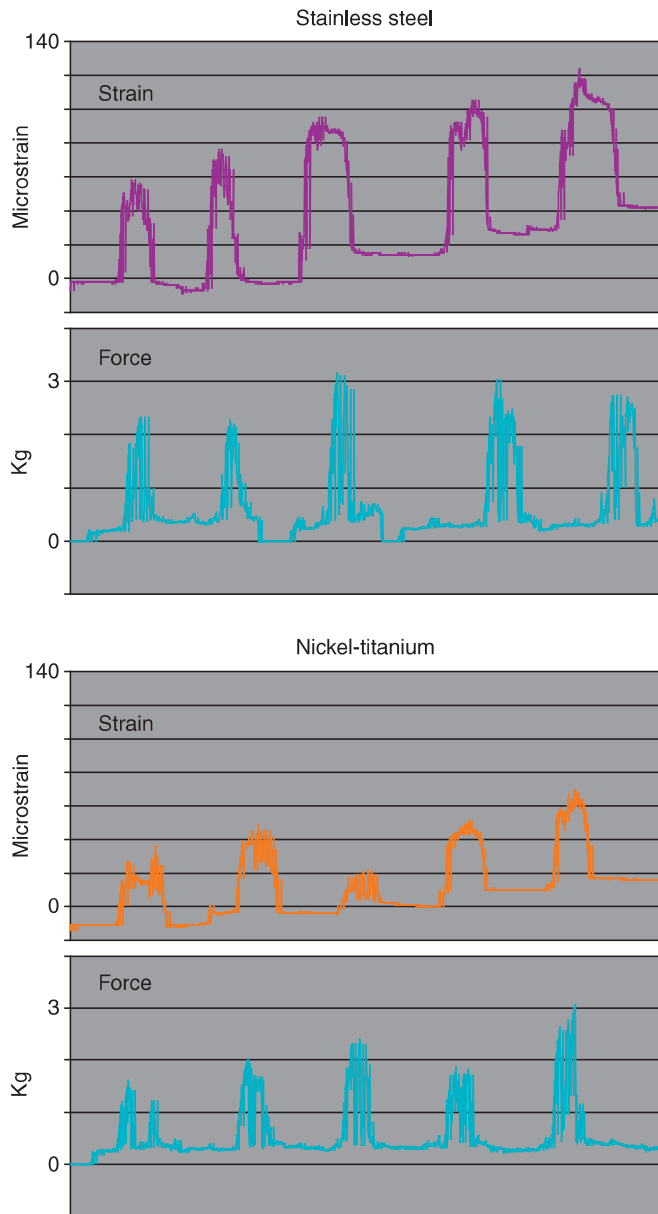


FIG. 21-32 Strain caused by stainless-steel versus nickel-titanium finger spreaders. The force applied to the finger spreader during lateral compaction caused strain on the buccal side of the apical part of the maxillary central incisors. Upper panels: the force and strain registered with a stainless-steel finger spreader. Lower panels: the root filling was removed, and another cycle of lateral compaction was completed for the same tooth using a nickel-titanium finger spreader. The spreader dimensions and depth of insertion were similar in both cycles. The nickel-titanium finger spreader required less force and generated lower strains than the stainless-steel finger spreader. (From Pilo R: Development of strains and mechanical failure in dental roots undergoing root canal obturation and prosthetic rehabilitation. PhD thesis, Tel Aviv University, 2007, supervised by Zvi Metzger and T. Brosh.)

around and beyond the gingival margins of the core) provide better strain distribution than similar restorations that are supported by the post and core alone.⁴ This design may help to avoid yet another potential predisposing factor for VRFs.²⁶

Conclusions

In conclusion, even though endodontic treatment may be necessary in many occasions, the impact of each of the iatrogenic predisposing factors should be minimized as much as possible, as they are likely to have a cumulative deleterious effect.

TREATMENT PLANNING

Prevention is the key to managing vertical root fractures. There are many predisposing factors and iatrogenic causes of these fractures, all of which should be minimized as much as clinically possible. VRFs may be present in teeth subjected to retreatment but are rarely present also in teeth that have never undergone endodontic treatment.²² Therefore, comprehensive clinical, radiographic, and *periodontal examination* is imperative when evaluating any tooth that is planned for endodontic treatment or retreatment. A flexible periodontal probe is mandatory in such examinations.

When a VRF is determined to be present, extraction of the affected tooth or root is recommended as soon as possible. Any delay may increase the potential for additional periradicular bone loss and possibly compromise the placement of an endosseous implant. Thus the measures and means that may allow the dentist to make the diagnosis at early stages are important. Attempts to “repair” a fracture by filling the crevice with a variety of restorative materials have been reported; however, none of these repairs is considered a reliable long-term solution.^{8,49,53,84}

SUMMARY

Because of the wide variety of different types of cracks and fractures in teeth, there may be a myriad of symptoms and presentations that may appear at different stages of the crack or fracture development, making their diagnosis often difficult. The awareness that many of these symptoms represent *stages in an evolving process* may make their interpretation easier for the operator.

The extensiveness of a crack may directly alter the prognosis assessment and treatment plan for a given tooth; the presence of a fracture may lead to the demise of a tooth and may compromise the periradicular bone. Therefore, developing a diagnosis, prognosis assessment, and treatment plan for teeth with suspected cracks and fractures is essential, with an emphasis on early detection. In addition, endodontic and restorative procedures should focus on minimizing any offending and predisposing factors that may perpetuate cracks and fractures.

REFERENCES

- Abbott PV: Assessing restored teeth with pulp and periapical diseases for the presence of cracks, caries and marginal breakdown, *Aust Dent J* 49:33, 2004.
- Adorno CG, Yoshioka T, Suda H: Crack initiation on the apical root surface caused by three different nickel-titanium rotary files at different working lengths, *J Endod* 37:522, 2011.
- Alfor JE: Managing incomplete tooth fractures, *J Am Dent Assoc* 131:1186, 2000.
- American Association of Endodontists: *Restoration of endodontically treated teeth. Endodontics; colleagues for excellence*, Chicago, spring/summer 2004, American Association of Endodontists.
- American Association of Endodontists: *Cracking the cracked tooth code: detecting and treatment of various longitudinal tooth fractures. Endodontics; colleagues for excellence*, Chicago, summer 2008, American Association of Endodontists.
- American Association of Endodontists and American Academy of Oral and Maxillofacial Radiology: AAE and AAOMR joint position statement: use of cone-beam computed tomography in endodontics, *J Endod* 37:274, 2011.
- Anderson TL: *Fracture mechanics: fundamentals and applications*, ed 3, Oxford, 2005, Taylor & Francis.
- Arakawa S: Treatment of root fractures by CO₂ and Nd:YAG lasers, *J Endod* 22:662, 1996.
- Bakland LK: Tooth infractions. In Ingle JI, Bakland LK, Baumgartner JC, editors: *Ingle's endodontics*, ed 6, Hamilton, ON, 2008, BC Decker.
- Barreto MS, Moraes RA, da Rosa RA, et al: Vertical root fractures and dentin defects: effects of root canal preparation, filling and mechanical cycling, *J Endod* 38:1135, 2012.
- Bender IB: Adult root fracture, *J Am Dent Assoc* 107:413, 1983.
- Berman LH, Hartwell GR: Diagnosis. In Hargreaves KM, Cohen S, editors, *Cohen's pathways of the pulp*, ed 10, New York, 2011, Elsevier, p 2.
- Berman LH, Kuttler S: Fracture necrosis: diagnosis, prognosis assessment, and treatment recommendations, *J Endod* 36:442, 2010.
- Bier CA, Shemesh H, Tanomaru-Filho M, et al: The ability of different nickel-titanium rotary instruments to induce dentinal damage during canal preparation, *J Endod* 35:236, 2009.
- Boyarsky H, Davis R: Root fracture with dentin retained post, *Am J Dent* 5:11, 1992.
- Brynjulfsson A, Fristad I, Grevstad T, Hals-Kvinsland I: Incompletely fractured teeth associated with diffuse longstanding orofacial pain: diagnosis and treatment outcome, *Int Endod J* 35:461, 2002.
- Bürklein S, Tsotsis P, Schäfer E: Incidence of dentinal defects after root canal preparation: reciprocating versus rotary instrumentation, *J Endod* 39:501, 2013.
- Cameron CE: Cracked tooth syndrome, *J Am Dent Assoc* 68:405, 1964.
- Cameron CE: The cracked tooth syndrome: additional findings, *J Am Dent Assoc* 93:971, 1976.
- Caplan DJ, Weintraub JA: Factors related to loss of root canal filled teeth, *J Publ Health Dent* 57:31, 1997.
- Chai H, Tamse A: Fracture mechanisms analysis of vertical root fracture from condensation of gutta-percha, *J Biomech* 45:1673, 2012.
- Chan CP, Lin CP, Tseng SC, Jeng JH: Vertical root fracture in endodontically versus non-endodontically treated teeth, *Oral Surg Oral Med Oral Pathol Oral Radiol Endod* 87:504, 1999.
- Cheung W: A review of the management of endodontically treated teeth, *J Am Dent Assoc* 136:611, 2005.
- Cohen S, Blanco L, Berman L: Vertical root fractures—clinical and radiographic diagnosis, *J Am Dent Assoc* 134:434, 2003.
- Cooney JP, Caputo AA, Trabert KC: Retention and stress distribution of tapered-end endodontic posts, *J Prosthet Dent* 55:540, 1986.
- da Silva NR, Raposo LH, Versluis A, et al: The effect of post, core, crown type, and ferrule presence on the biomechanical behavior of endodontically treated bovine anterior teeth, *J Prosthet Dent* 104:306, 2010.
- Dang DA, Walton RE: Vertical root fracture and root distortion effect of spreader design, *J Endod* 15:294, 1989.
- Davis R, Overton JD: Efficacy of bonded and nonbonded amalgam in treatment of teeth with incomplete fractures, *J Am Dent Assoc* 131:469, 2000.
- Eakle WS, Maxwell EH, Braly BV: Fractures of posterior teeth in adults, *J Am Dent Assoc* 112:215, 1986.
- El Ayouti A, Chu A-L, Kimonis I, et al: Efficacy of rotary instruments with greater taper in preparing oval root canals, *Int Endod J* 41:1088, 2008.
- European Commission for Radiation Protection: Radiation protection No 172, Cone Beam CT for dental and maxillofacial radiology: evidence-based guidelines, SEDENTEXCT project, www.sedentext.eu, 2012.
- European Society of Endodontology position statement: The use of CBCT in endodontics, *Int Endod J* 47:502, 2014.
- Fuss Z, Lustig J, Katz A, Tamse A: An evaluation of endodontically treated vertically fractured roots: impact of operative procedures, *J Endod* 1:46, 2001.
- Fuss Z, Lustig J, Tamse A: Prevalence of vertical root fractures in extracted endodontically treated teeth, *Int Endod J* 32:283, 1999.
- Geurdsen W, Schwarze T, Günay H: Diagnosis, therapy and prevention of the cracked tooth syndrome, *Quintessence Int* 34:409, 2003.
- Gibbs JW: Cuspal fracture odontalgia, *Dent Dig* 60:158, 1954.
- Gluskin AH, Radke RA, Frost SL, Watanabe LG: The mandibular incisor: rethinking guidelines for post and core design, *J Endod* 21:33, 1995.
- Goodcare CJ, Baba NZ: Restoration of endodontically treated teeth. In Ingle JI, Bakland LK, Baumgartner JC, editors: *Ingle's endodontics*, ed 6, Hamilton, ON, 2008, BC Decker, p 1431.
- Graves DT, Oates T, Garlet GP: Review of osteoimmunology and the host response in endodontic and periodontal lesions, *J Oral Microbiol* 3:5304—DOI: 10.3402/jom.v3i0.5304, 2011.
- Guthrie RC, DiFiore PM: Treating the cracked tooth with full crown, *J Am Dent Assoc* 122:71, 1991.
- Gutmann JL: The dentin-root complex: anatomic and biologic considerations in restoring endodontically treated teeth, *J Prosthet Dent* 67:458, 1992.
- Hassan B, Metska ME, Ozok AR, et al: Detection of vertical root fractures in endodontically treated teeth by a cone beam computed tomography scan, *J Endod* 35:719, 2009.
- Hassan B, Metska ME, Ozok AR, et al: Comparison of five cone beam computed tomography systems for the detection of vertical root fractures, *J Endod* 36:126, 2010.
- Helfer AR: Determination of the moisture content of vital and pulpless teeth, *Oral Surg* 34:661, 1972.
- Hin ES, Wu M-K, Wesselink PR, Shemesh H: Effects of self-adjusting file, Mtwo, and ProTaper on the root canal wall, *J Endod* 39:262, 2013.
- Homewood CI: Cracked tooth syndrome: incidence, clinical findings and treatment, *Aust Dent J* 43:217, 1998.
- Huang TJ, Schilder H, Nathanson D: Effects of moisture content and endodontic treatment on some mechanical properties of human dentin, *J Endod* 18:209, 1991.
- Kahler B, Moule A, Stenzel D: Bacterial contamination of cracks in symptomatic vital teeth, *Aust Endod J* 26:115, 2000.
- Katz A, Wasenstein-Kohn S, Tamse A, Zukerman O: Residual dentin thickness in bifurcated maxillary premolars after root canal and dowel space preparation, *J Endod* 32:202, 2006.
- Kawai K, Masaka N: Vertical root fracture treated by bonding fragments and rotational replantation, *Dent Traumatol* 18:42, 2002.
- Kim HC, Lee MH, Yum J, et al: Potential relationship between design of nickel-titanium rotary instruments and vertical root fracture, *J Endod* 36:1195, 2010.
- Krell KV, Rivera EM: A six year evaluation of cracked teeth diagnosed with reversible pulpitis: treatment and prognosis, *J Endod* 33:1405, 2007.
- Kruzic JJ, Nalla RK, Kinney JH, Ritchie RO: Mechanistic aspects of in vitro fatigue-crack growth in dentin, *Biomaterials* 26:1195, 2005.
- Kudou Y, Kubota M: Replantation with intentional rotation of complete vertically fractured root using adhesive resin, *Dent Traumatol* 18:115, 2003.
- Lertchirakarn V, Palamara J, Messer HH: Patterns of vertical fractures: Factors affecting stress distribution in the root canal, *J Endod* 29:523, 2003.
- Lertchirakarn V, Palamara JEA, Messer HH: Finite element analysis and strain-gauge studies of vertical root fracture, *J Endod* 29:529, 2003.
- Liu R, Kaiwar A, Shemesh H, et al: Incidence of apical root cracks and apical dentinal detachments after canal preparation with hand and rotary files at different instrumentation lengths, *J Endod* 39:129, 2013.
- Lustig JP, Tamse A, Fuss Z: Pattern of bone resorption in vertically fractured endodontically treated teeth, *Oral Surg Oral Med Oral Pathol Oral Radiol Endod* 90:224, 2000.
- Meister F, Lommel TJ, Gerstein H: Diagnosis and possible causes of vertical root fractures, *Oral Surg Oral Med Oral Pathol Oral Radiol Endod* 49:243, 1980.
- Melo SLS, Bortoluzzi EA, Abreu M Jr, et al: Diagnostic ability of a cone-beam computed tomography scan to assess longitudinal root fractures in prosthetically treated teeth, *J Endod* 36:1879, 2010.
- Metzger Z, Teperovich E, Zary R, et al: The self-adjusting file (SAF). Part 1: respecting the root canal anatomy—a new concept of endodontic files and its implementation, *J Endod* 36:679, 2010.
- Morando G, Leupold RJ, Reiers JC: Measurements of hydrostatic pressure during simulated post cementation, *J Prosthet Dent* 74:586, 1995.
- Nikopoulou-Karayanni K, Bragger U, Lang NP: Patterns of periodontal destruction associated with incomplete root fractures, *Dentomaxillofac Radiol* 26:321, 1997.
- Onnink PA, Davis RD, Wayman BE: An in vitro comparison of incomplete root fractures associated with obturation technique, *J Endod* 20:32, 1994.
- Opdam NJ, Roeters JJ, Loomans BA, Bronkhorst EM: Seven-year clinical evaluation of painful cracked teeth restored with a direct composite restoration, *J Endod* 34:808, 2008.
- Patel S, Dawood A, Ford TP, Whaites E: The potential applications of cone beam computed tomography in the management of endodontic problems, *Int Endod J* 40:818, 2007.
- Peters OA, Paqué F: Root canal preparation of maxillary molars with the self-adjusting file: A micro-computed tomographic study, *J Endod* 37:53, 2011.
- Peters OA, Peters CL, Schöenberg K, Barbakow F: ProTaper rotary root canal preparation assessment of torque and force in relation to canal anatomy, *Int Endod J* 36:93, 2003.
- Pilo R: *Development of strains and mechanical failure in dental roots undergoing root canal obturation and prosthetic rehabilitation*, PhD thesis, Tel Aviv University, 2007.
- Ritchey B, Mendenhall R, Orban B: Pulpitis resulting from incomplete tooth fracture, *Oral Surg Oral Med Oral Pathol Oral Radiol Endod* 10:665, 1957.
- Roh BD, Lee YE: Analysis of 154 cases of teeth with cracks, *Dent Traumatol* 22:118, 2006.
- Rosen H: Cracked tooth syndrome, *J Prosthet Dent* 47:36, 1982.

72. Rud J, Omnell KA: Root fracture due to corrosion, *Scand J Dent Res* 78:397, 1970.
73. Saw L-H, Messer HH: Root strains associated with different obturation techniques, *J Endod* 21:314, 1995.
74. Schmidt KJ, Walker TL, Johnson JD, Nicoll BK: Comparison of nickel-titanium and stainless steel spreader penetration and accessory cone fit in curved canals, *J Endod* 26:42, 2000.
75. Sedgley CM, Messer HH: Are endodontically treated teeth more brittle? *J Endod* 18:332, 1992.
76. Shemesh H, Bier CA, Wu MK, et al: The effects of canal preparation and filling on the incidence of dentinal defects, *Int Endod J* 42:208, 2009.
77. Shemesh H, Roeleveld AC, Wesselink PR, Wu MK: Damage to root dentin during retreatment procedures, *J Endod* 37:63, 2011.
78. Snyder DE: The cracked tooth syndrome and fractured posterior cusp, *Oral Surg Oral Med Oral Pathol Oral Radiol Endod* 41:698, 1976.
79. Tamse A: Iatrogenic vertical root fractures in endodontically treated teeth, *Endod Dent Traumatol* 4:190, 1988.
80. Tamse A: Vertical root fractures of endodontically treated teeth. In Ingle JI, Bakland LK, Baumgartner JC, editors: *Ingle's endodontics*, ed 6, Hamilton, ON, 2008, BC Decker, p 676.
81. Tamse A, Fuss Z, Lustig J, Kaplavi J: An evaluation of endodontically treated vertically fractured teeth, *J Endod* 25:506, 1999.
82. Tamse A, Fuss Z, Lustig JP, et al: Radiographic features of vertically fractured endodontically treated maxillary premolars, *Oral Surg Oral Med Oral Pathol Oral Radiol Endod* 88:348, 1999.
83. Tamse A, Kaffe I, Lustig J, et al: Radiographic features of vertically fractured endodontically treated mesial roots of mandibular molars, *Oral Surg Oral Med Oral Pathol Oral Radiol Endod* 101:797, 2006.
84. Taschieri S, Tamse A, del Fabbro M, et al: A new surgical technique for preservation of endodontically treated teeth with coronally located vertical root fractures: a prospective study, *Oral Surg Oral Med Oral Pathol Oral Radiol Endod* 110:45, 2010.
85. Testori T, Badino M, Castagnola M: Vertical root fractures in endodontically treated teeth: a clinical survey of 36 cases, *J Endod* 19:87, 1993.
86. Tsesis A, Rosen E, Tamse A, et al: A diagnosis of vertical root fractures in endodontically treated teeth based on clinical and radiographic indices: a systematic review, *J Endod* 36:1455, 2010.
87. Walton RE, Michelich RJ, Smith GN: The histopathogenesis of vertical root fractures, *J Endod* 10:48, 1984.
88. Walton RE, Torabinejad M: *Principles and practice of endodontics*, ed 3, Philadelphia, 2002, WB Saunders, p 516.
89. Wilcox LR, Roskelley C, Sutton T: The relationship of root canal enlargement to finger-spreader induced vertical root fracture, *J Endod* 23:533, 1997.
90. Yeh CJ: Fatigue root fracture: a spontaneous root fracture in non-endodontically treated teeth, *British Dent J* 182:261, 1997.
91. Yoldas O, Yilmaz S, Atakan G, et al: Dentinal microcrack formation during root canal preparations by different Ni-Ti rotary instruments and the self-adjusting file, *J Endod* 38:235, 2012.